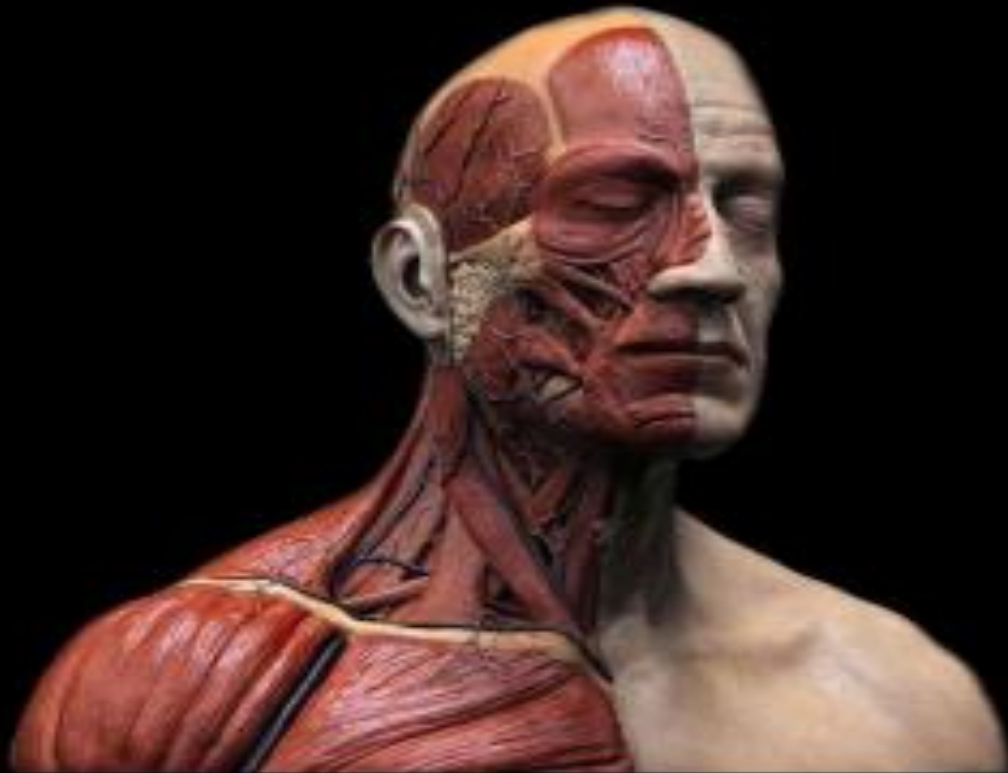



Head and Neck Anatomy



AL-Saraj
Professor of Human Anatomy
University of Mosul - College of Dentistry

I

Head and Neck Anatomy

Dr. Ayad AL-Saraj

Professor of Human Anatomy

University of Mosul - College of Dentistry

II

Preface

Most of anatomy textbook are traditionally directed toward the students of medicine. Moreover, there tends to be a uniform emphasis on all areas of the body, thus limiting the use of such texts in dentistry courses.

This book, on the other hand, fulfills a need for a textbook of gross anatomy specifically tailored for undergraduate dental students, highlights those regions of the head and neck that are of clinical importance. The study of these regions is essential as a foundation for other basic sciences and subsequent clinical courses. The number of clinical applications has been highlighted with shaded yellow boxes.

Preparation of this work has occupied the author for nearly more than one year, and it is the culmination of many years spent in the classroom and in the laboratory. Our objective was to create a high quality and visually attractive pure Iraqi anatomical work and I hope that the time and effort spent in its preparation is reflected in the finished product. At the same time, it is hoped that this book will maintain its usefulness and prove valuable throughout the undergraduate clinical years and eventually take its place on the desk of the practicing dentist.

I would like to record our thanks to the dean of college of dentistry and to the Mosul university for their invaluable support to complete this work.

Dr. Ayad AL-Saraj

Mosul- Iraq 2022

III

CONTENTS

NUMBER	TITLE	PAGE
1	INTRODUCTION TO HUMAN ANATOMY	
2	BASIC STRUCTURES OF THE BODY	
3	THE FACE	
4	THE SCALPE	
5	THE NECK	
6	POSTERIOR TRIANGLE	
7	ANTERIOR TRIANGLE	
8	SUBMANDIBULAR TRIANGLE	
9	CAROTID TRIANGLE	
10	MUSCULAR TRIANGLE	
11	ROOT OF THE NECK	
12	THYROID GLAND	
13	PAROTID REGION	
14	TEMPORAL FOSSA	
15	INFRATEMPORAL FOSSA	
16	MUSCLES OF MASTICATION	
17	MANDIBULAR NERVE	
18	MAXILLARY ARTERY	
19	MAXILLARY NERVE	
20	TEMPROMANDIBULAR JOINT (TMJ)	
21	ORAL CAVITY	
22	HARD PALATE	
23	SOFT PALATE	
24	TONGUE	
25	FLOOR OF THE MOUTH	
26	PHARYNX	
27	PARANASAL SINUSES	
28	NASAL CAVITY	
29	LARYNX	
30	ORBITAL CAVITY	
31	EAR	
32	LYMPH NODES OF HEAD AND NECK	

NUMBER	TITLE	PAGE
33	FACIAL SPACES OF HEAD AND NECK	
35	MENINGES	
36	VENOUS SINUSES OF THE BRAIN	
37	BLOOD SUPPLY OF THE BRAIN	
38	CEREBRUM	
39	CEREBELLUM	
40	MEDULLA OBLONGATA	
41	PONS	
42	MIDBRAIN	
43	DIENCEPHALON	
44	VENTRICLES OF THE BRAIN	
45	REFERENCES	

INTRODUCTION TO HUMAN ANATOMY

Basic anatomy

Anatomy: the term which means the study of human body, it's divided into:

- 1- **Macroanatomy or Gross anatomy:** which studies the structures of human body and the relationships of its parts to each other by the method of dissection, and take the anatomical knowledge by naked eye.
- 2- **Microanatomy:** which is divided into:
 - a- **Histology:** studies the cells, tissues and organs of the body using microscope.
 - b- **Embryology:** studies the development of the human from the fertilization of the ovum to the birth (intrauterine life).
 - c- **Cell biology:** studies the structure and function of the cell, which is the basic unit of life.

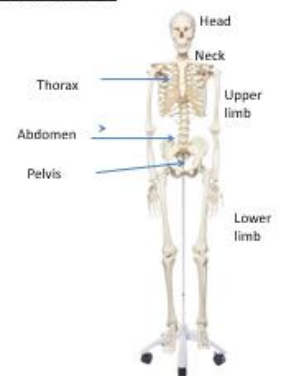
✿ **For descriptive purpose, the human body is divided into:**

- Head, neck, trunk and limbs.
- The trunk is subdivided into: (Chest or Thorax) and (Belly or Abdomen).
- The abdomen is further subdivided into: Abdomen proper and Pelvis.

✿ **Anatomical position:**

- The body usually lies in erect position on a table with the arms by the sides and the palms and face direct forwards, heels together.

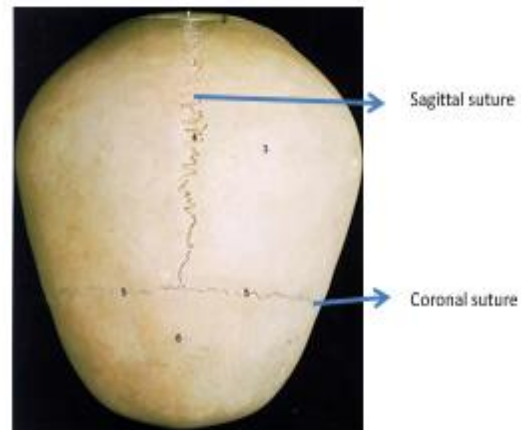
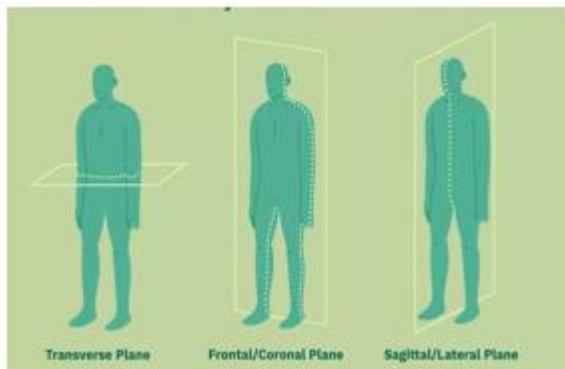
Human body divided into:



✿ **Sections used during dissection:**

- 1- **Median or Sagittal section (plane):** a vertical plane passes through the center of the body or through the sagittal suture of the skull and divides the body into symmetrical or equal right and left halves. (any section parallel to this section is called parasagittal section)

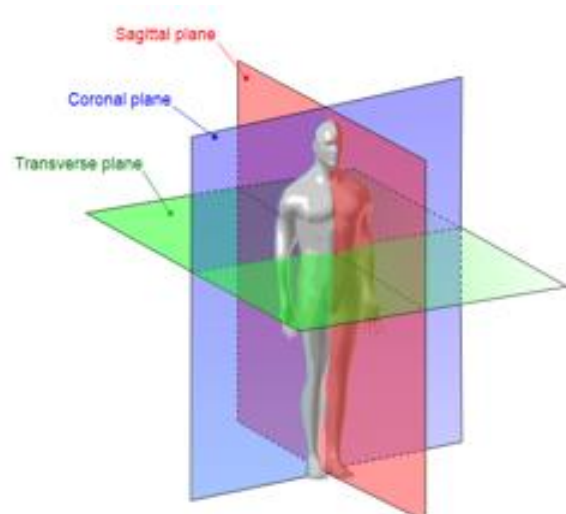
- 2- **Coronal or Frontal section:** a vertical plane passes through the coronal suture of the skull at the right angle to the median plane, it divides the body into front and back.
- 3- **Transverse or Horizontal or Cross section:** it's at the right angle to the median and coronal planes, divides the body into above and below.



✿ Terms of position:

The following terms are used to express the relationship of any structure to the other within the body:

- **Anterior (ventral):** nearer or closer to the front surface of the body.
- **Posterior (dorsal):** nearer or closer to the back surface of the body.
- **Superior:** nearer or closer to the head.
- **Inferior:** nearer or closer to the feet.
- **Medial:** nearer to the median or sagittal plane.
- **Lateral:** further from the median plane.
- **Internal & external:** used to describe the distance or relation of the structure from the center of an organ or a cavity.
- **Superficial & deep:** to describe the distance of a structure from the surface of the body.

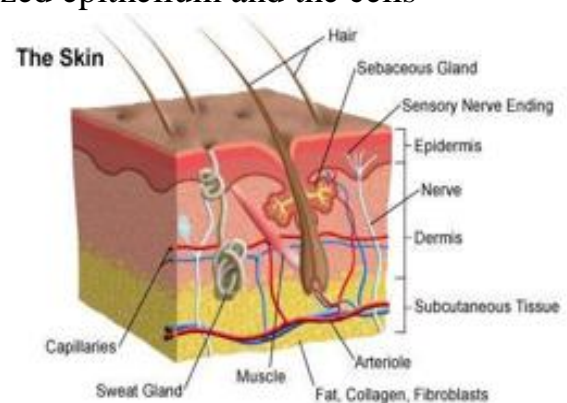


BASIC STRUCTURES OF THE BODY

✿ Skin

The skin is divided into two distinct parts, the superficial part (Epidermis) and the deep part (Dermis)

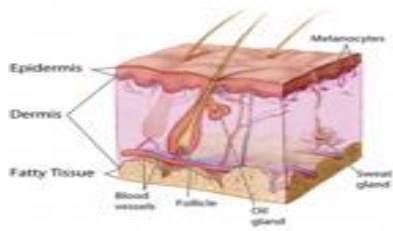
- The epidermis is a stratified squamous keratinized epithelium and the cells become flattened as they mature and rise to surface. On the palms of the hands and the soles of feet, the epidermis is thick while in the other area of the body it is thin.
- The Dermis is composed of dense connective tissue containing many blood vessels, lymphatic vessels and nerves. It shows considerable variation in the thickness in the different parts of the body and it is thinner in woman than man and in the flexor surfaces of the limbs than the extensor surfaces.
- The dermis consists of bundles of collagen fibers and mostly arranged in parallel rows, a surgical incision through the skin made along or between these rows cause minimum of scar tissue. The Dermis connected to the underlying deep fascia or bones by the superficial fascia which is also called subcutaneous tissue. The appendages of the skin are the nails, hair follicles, sebaceous and sweat glands.



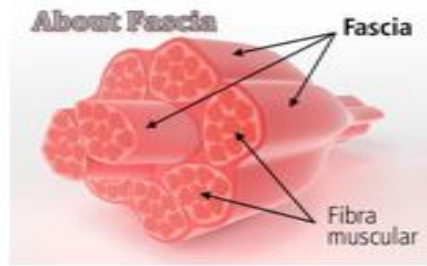
✿ Fascia

The fascia can be divided into two parts:

- 1- **Superficial or Subcutaneous tissue:** it's a mixture of loose areolar and adipose tissue that unite the dermis of the skin to the underlying deep fascia, it allows the skin to move over the underlying structures. In palms and soles, it contains numerous bundles of collagen fibers that hold the skin firmly to the deep structures.
- 2- **Deep fascia:** it's a membranous layer of connective tissue that invests the muscles and other deep structures. Fibrous septa extend from the deep surface of the membrane between the groups of muscles and divide the limbs into compartments. In the region of joints, the deep fascia becomes thick to form restraining band called *retinacula* which hold the underlying tendons in position.



Superficial fascia



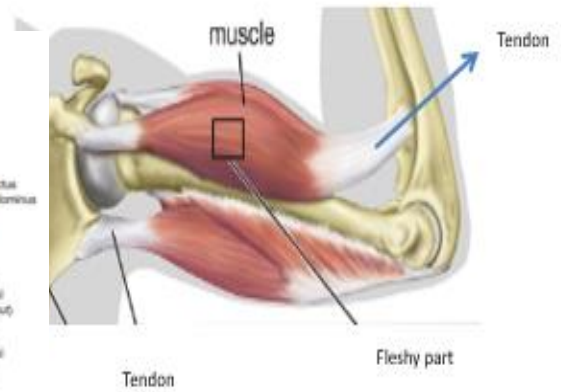
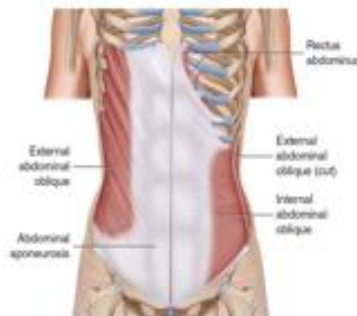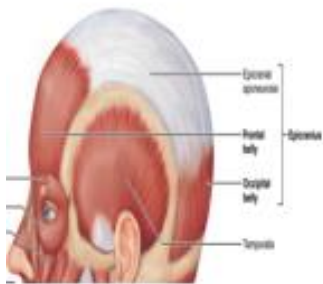
Deep fascia

★ **Muscles**

There are 3 types of muscles:

1- **Skeletal muscle (voluntary or striated muscle)**: these muscles produce movements of the skeleton, each muscle has two or more attachments, the attachment that moves the least is called

Aponeurosis

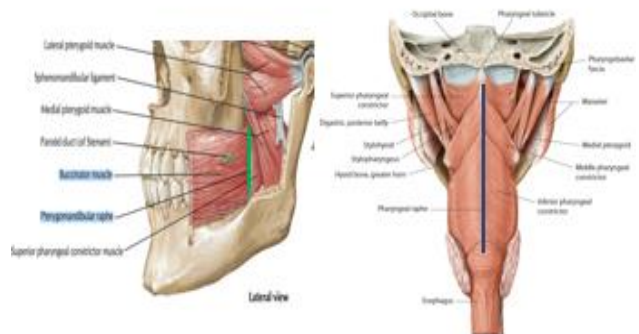


origin, and that which moves the most is called insertion. The fleshy part of the muscle is called **Belly**, while the ends attached to bones, cartilages or ligaments formed by fibrous tissue are called tendons. Some flattened muscles (as in the head and neck) are attached by thin but strong sheet of fibrous tissue called the **aponeurosis**, or attached to a cord like structure called **raphe**.

Raphe

The names of muscles according to:

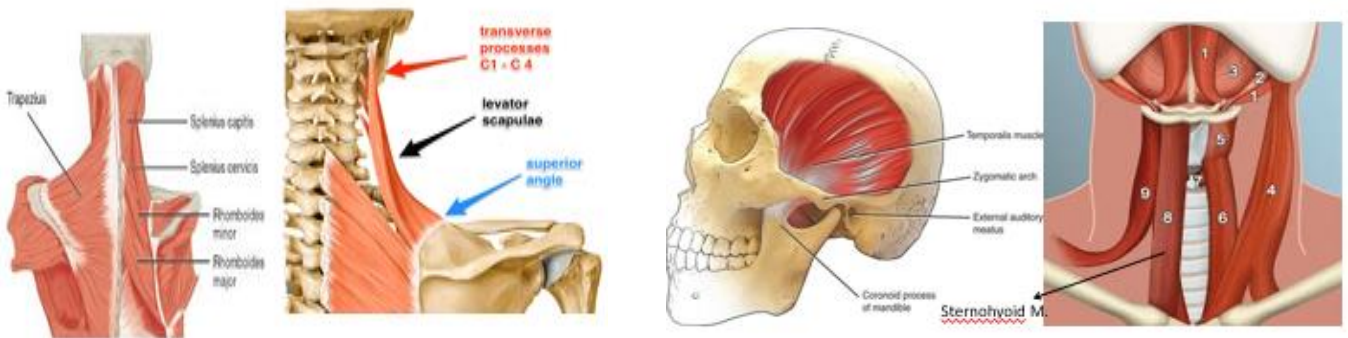
- a) The shape → Trapezius M.
- b) Location → Temporalis M.
- c) Action → Levator scapula M.
- d) Number of heads of origin → Biceps M.
- e) The origin and insertion → Sternothyroid M.



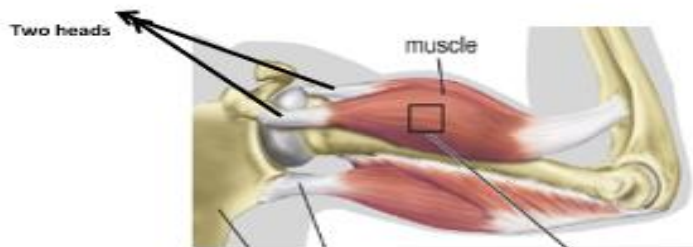
- 2- **Smooth muscle (involuntary muscle):** it consists of long, spindle-shaped cells closely arranged in bundles or sheets; they are found in the walls of involuntary organs.
- 3- **Cardiac muscle (striated involuntary):** it consists of striated and branched muscle fibers that form the myocardium of the heart.

Names of muscles: shape and Action

According to the location & origin- insertion



According to the number of heads of origin: Biceps or triceps muscles

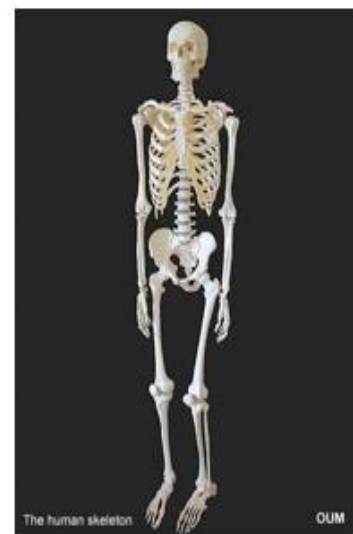

🌟 Bones

The skeletal system consists of set of bones which serves as a supporting framework of the body, it also protects the vital organs such as the brain, heart and lungs.

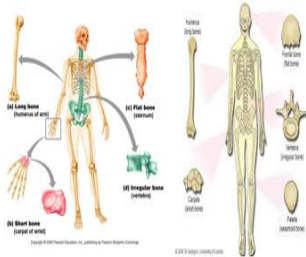
It serves for the attachment of muscles and the formation of blood cells as well as a store house for calcium and phosphorus. There are 206 bones in complete skeleton.

- Skull=29
- Ribs + sternum=25
- Upper Limb=64
- Lower Limb= 62
- Vertebral Colum=26
- Total=206



The bones are classified according to their shape into:

- 1- **Long bones:** they are found in the limbs (e. g. humerus, femur). Their length is greater than their breadth, they have a shaft called diaphysis, and two heads called epiphysis.
- 2- **Short bones:** found in the hand and foot (e. g. carpal, tarsal bones), they are roughly cuboidal in shape.



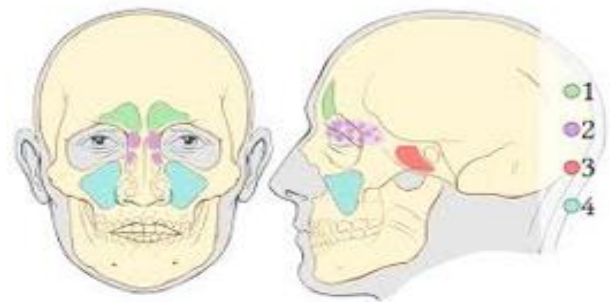
3- **Flat bones:** they are found in the vault of the skull (e. g. frontal, parietal bones).

4- **Irregular bones:** e. g. the vertebrae.

5- **Sesamoid bones:** small bones found in certain tendons; the largest sesamoid bone is the patella which is located in the tendon of quadriceps femoris.

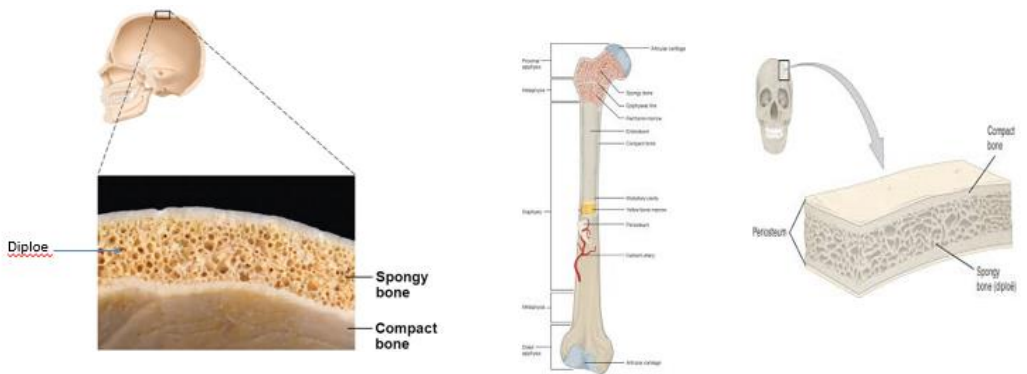
6- **Pneumatic bones:** e. g. the maxilla which has air spaces.

Pneumatic bones



✱ **Histologically, the bones are classified into:**

- a- Compact bone.
 - b- Spongy bone.
- Each bone is composed of compact and spongy bones (e. g. the shaft of long bones is formed by compact bone, while the heads are formed by spongy bone).
 - The flat bones are formed by inner and outer layers (tables) of compact bone, and between them, there's a spongy bone called **diploe**.
 - The irregular bones are composed of spongy bone covered by a thin layer of compact bone.
 - All bones are covered by a connective tissue layer called periosteum. The end of the head is smooth and called articular surface which is covered by hyaline cartilage for the articulation with the neighboring bone.



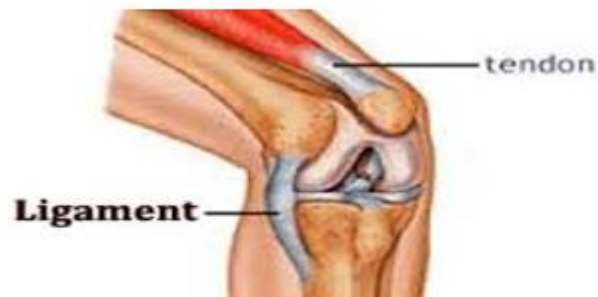★ Cartilage

The cartilage is a form of connective tissue, there are 3 types:

- 1- **Hyaline cartilage:** forms the skeleton of the fetus and found in trachea.
- 2- **Elastic cartilage:** found in the auricle of the ear, auditory tube and epiglottis.
- 3- **Fibrocartilage:** found in the intervertebral discs and the temporomandibular joint.

★ Ligaments

The ligament is a cord or band of connective tissue uniting two structures and usually in joints.



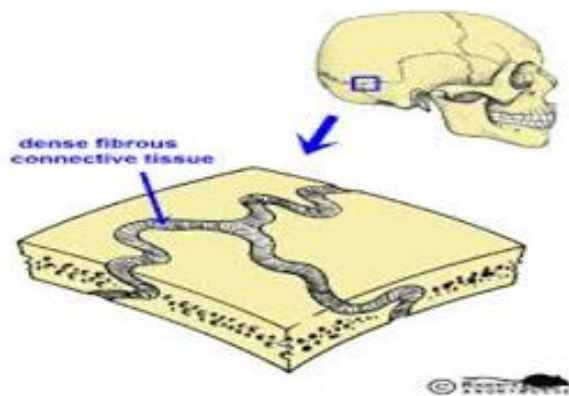
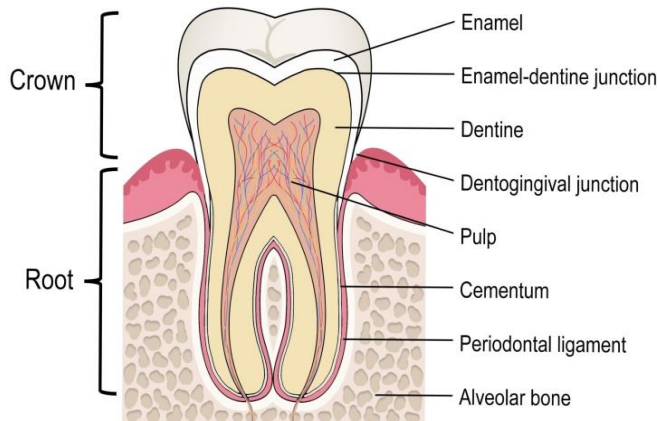
★ Joints

The site where two or more bones come together, whether there is a movement or not, it's called joint.

Joints are classified according to tissues that lie between the bones:

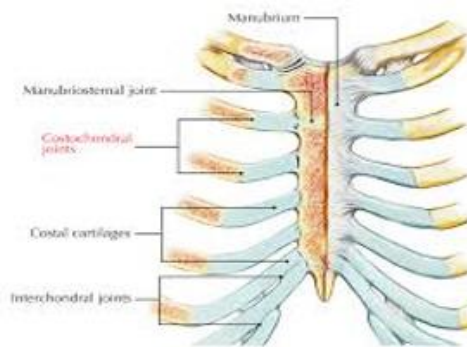
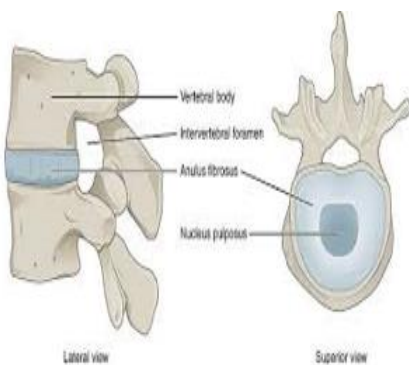
- 1- **Fibrous joints:** The articulating surfaces of the bones are joined by fibrous tissue and very little movement is possible. (e. g. the sutures of the vault of the skull).

((Other example is the dento-alveolar syndesmosis (gomphosis or socket) is a fibrous joint in which a peg-like process fits into a socket, forming an articulation between the root of the tooth and the alveolar process of the jaw (periodontal ligament). Mobility of this joint (a loose tooth) indicates a pathological state affecting the supporting tissues of the tooth)).



2- Cartilaginous joints: divided into 2 types

- a) **Primary cartilaginous joint:** in which the bones are united by a plate of hyaline cartilage. (e. g. the joint between the ribs and the sternum), no or little movement is possible.
- b) **Secondary cartilaginous joint:** the bones are united by a plate of fibrocartilage (intervertebral disc), e. g. the joint between the vertebrae, a small amount of movement is possible.

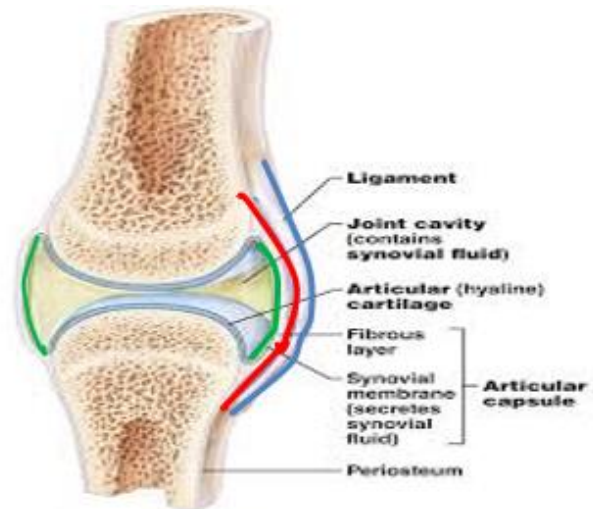

2- Synovial joints

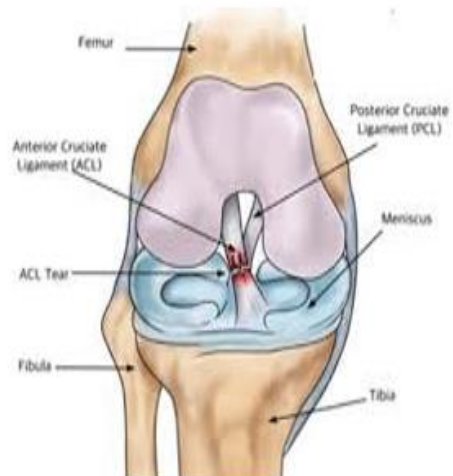
The articular surfaces of the bones are covered by a thin layer of hyaline cartilage separated by a joint cavity. This arrangement permits a great degree of freedom of movement. The cavity of the joint is lined by synovial membrane which extends from the margins of one articular surface to the other. The synovial membrane is protected from outside by a fibrous membrane called capsule.

The articular surfaces are lubricated by a viscous fluid called synovial fluid produced by the synovial membrane.

The degree of movement in the synovial joint is limited by the shape of the bones forming the joint and the presence of fibrous ligaments uniting the bones. Most of the ligaments lie outside the joint capsule, but in **knee joint**, some important ligaments called Cruciate ligaments lie within the capsule.

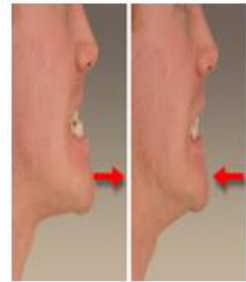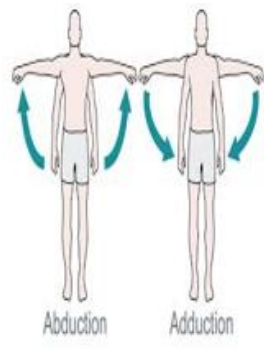
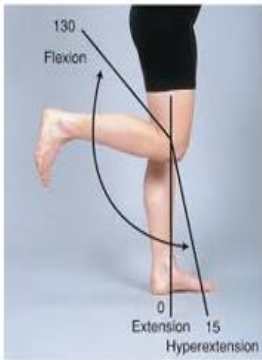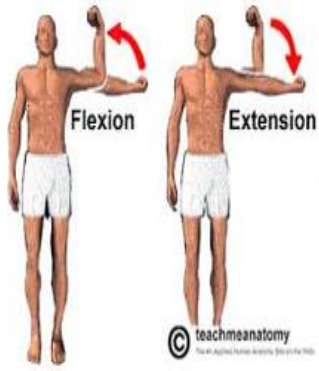


Cruciate Ligaments:



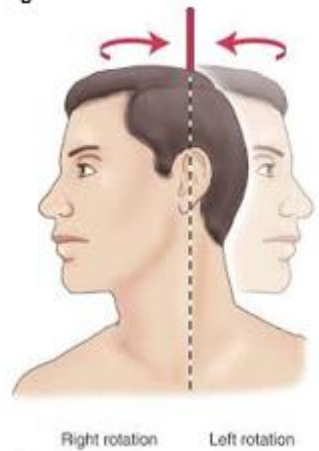★ The terms of movement

- 1- **Flexion:** this term used to describe any movement which making angle or bending of the parts. (e. g. flexion of the elbow joint)
- 2- **Extension:** the movement which brings the parts toward straight condition.
- 3- **Abduction:** the movement of limb away from the midline of the body.
- 4- **Adduction:** the movement of limb toward the body.
- 5- **Rotation:** the movement of a part of the body around its long axis.
- 6- **Circumduction:** is the combination of movements of flexion, extension, abduction and adduction.
- 7- **Protraction:** is the movement of the lower jaw (mandible) forward.
- 8- **Retraction:** is the movement of the lower jaw (mandible) backward.



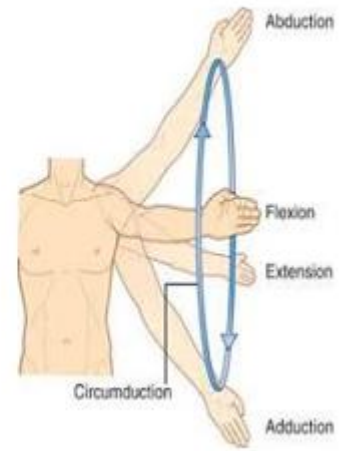
Rotation:

Movement around long axis

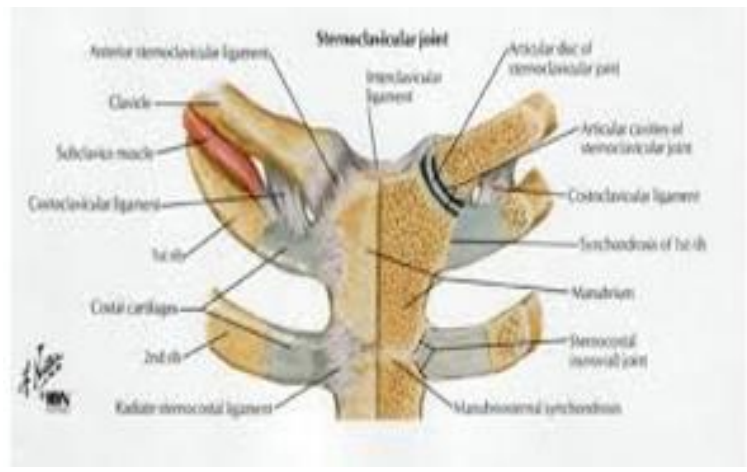


Circumduction

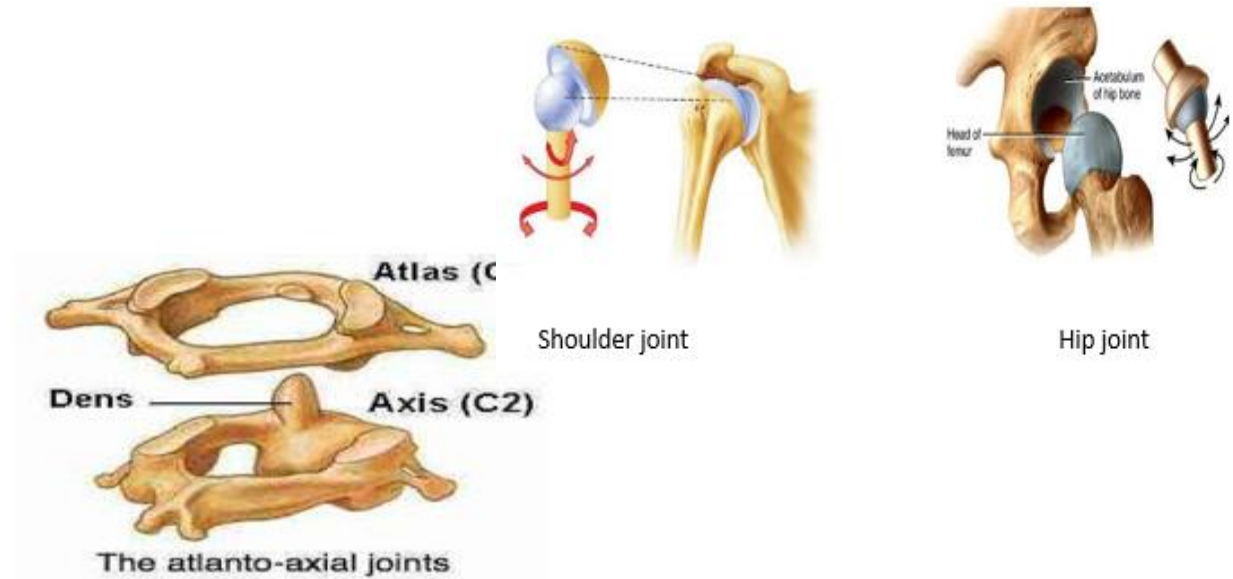
Combination of flexion+extension:
Adduction+abduction



- There are also many other movements.
- ☀ The synovial joints can be classified according to the arrangement of the articular surfaces and the types of the movement that are possible into:
 - 1) **Plane joints:** In these joints, the apposed articular surfaces are flat and this permits the bones to slide upon on another. (e.g. sternoclavicular joints)



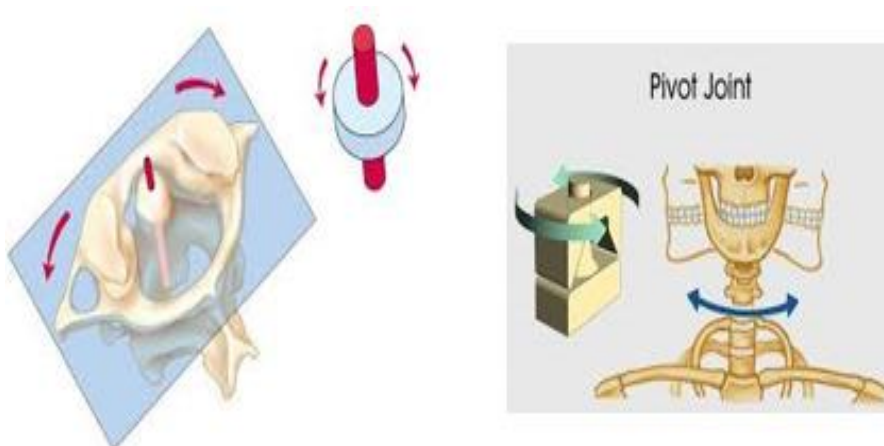
- 2) **Hinge joints:** These joints resemble the hinge on a door, so that flexion and extension movements are possible. (e. g. elbow and knee joints)
- 3) **Pivot joints:** In these joints, there is a central body by a bony-ligament ring. In this joint, rotation is the only movement possible. (e.g. atlantoaxial and the radio-ulnar joints)
- 4) **Ball and socket joints:** In these joints, a ball-shaped head of one bone fits
- 5) into a socket-like concavity of another. This arrangement permits very free

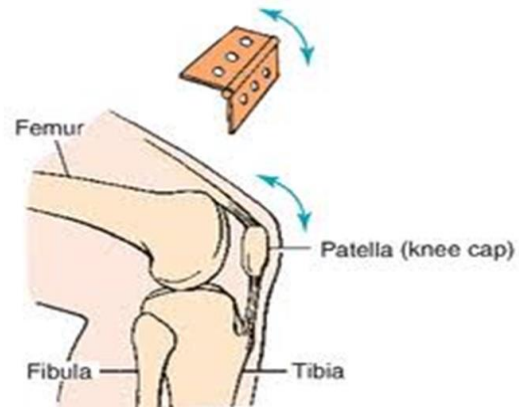
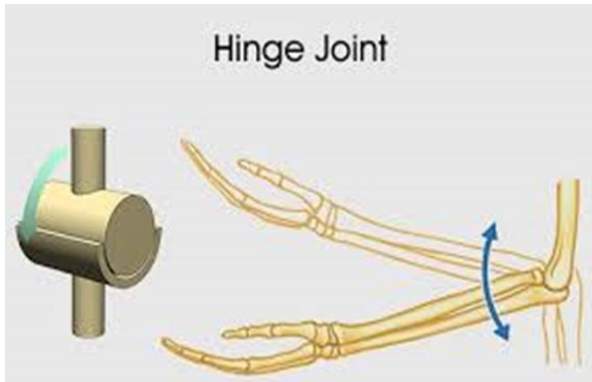


movement including flexion, extension, abduction, adduction, rotation and circumduction. (e.g. shoulder and hip joints).

Other types like:

- 6) **Condyloid joints** e.g. metacarpophalangeal joint
- 7) **Ellipsoid joints** e.g. wrist
- 8) **Saddle joints** e.g. carpometacarpal joint





✳ Blood vessels

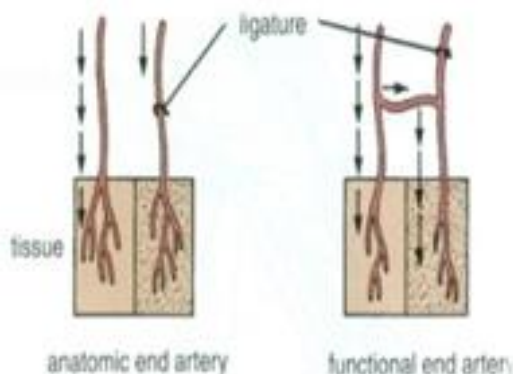
Blood vessels involve 3 types: arteries, veins and capillaries. The arteries transport blood from the heart and distribute it to the various tissues of the body.

The smallest arteries are called arterioles.

The joining of the branches of arteries is called anastomosis,

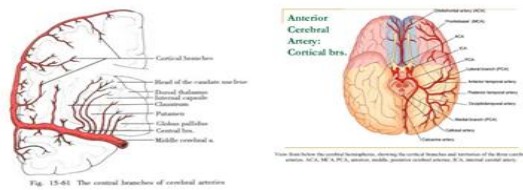
There are no valves in arteries.

- **Functional end artery:** having only ineffectual anastomosis, so that it is unable to maintain viability of the supplied tissue when the occlusion of the artery occurs. Blockage of one artery results in death of the tissue to lack sufficient blood supply from the other branch.



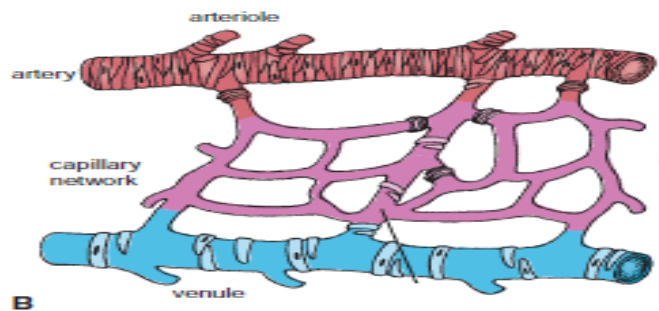
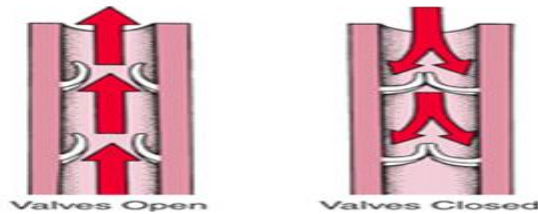
neighbors. There's no collateral circulation present besides the end arteries. (e. g. of end arteries: coronary artery, central artery of retina, central branches of cerebral arteries)

- **Veins**
- The veins are vessels that transport blood back to the heart and most of them possess valves. The smallest veins are called venules.
-
- **The capillaries** are microscopic vessels in the form of network connecting the arterioles to venules.



The veins are vessels that transport blood back to the heart and most of them possess valves.

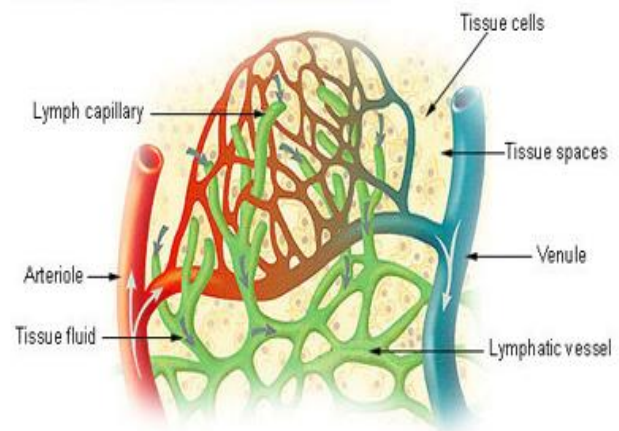
The smallest veins are called venules.



★ Lymphatic system

- The lymphatic system consists of lymphatic tissues and lymphatic vessels. Lymphatic tissues are type of connective tissue that contains large numbers of lymphocytes. The lymphatic tissues are the thymus, spleen, tonsils and lymph nodes. The lymphatic tissues are important for immunological defense of the body against bacteria and viruses.

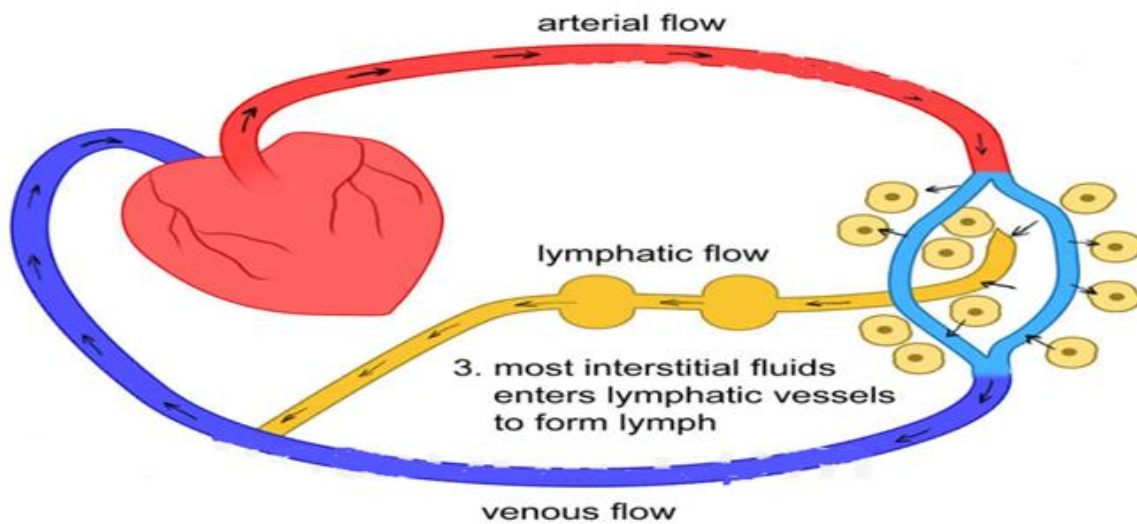
Lymph Capillaries in the Tissue Spaces



Lymphatic vessels: are tubes which assist in the removal of tissue fluid from the tissue spaces of the body, the vessels return to the heart. The lymphatic system is not a close cycle.

- Lymph vessels are found in all tissues and organs except the central nervous system, eye ball, cartilage, bones, internal ear and epidermis of skin.
- **Lymph:** is the name given to tissue fluid once it has entered the lymphatic vessels.
- **Lymphatic capillaries:** are network of fine vessels that drain lymph from the tissues. The capillaries in turn drained by small lymphatic vessels which unite to form large lymph vessels. The large lymph vessels have numerous valves.

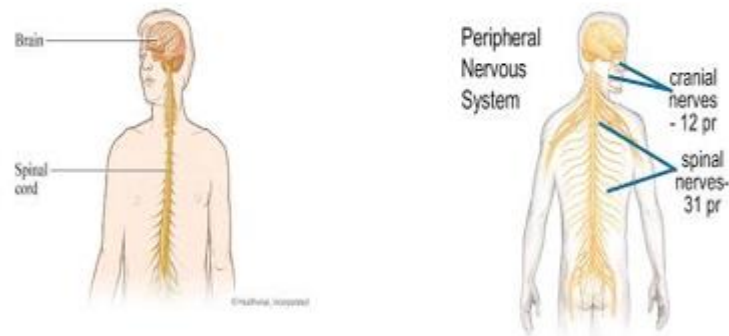
- Before the lymph is returned to the blood stream, it passes through at least one lymph node.
- The lymph reaches the blood stream at the root of the neck by large vessels called the right lymphatic duct and the thoracic duct.



★ Nervous system:

The nervous system is divided into two parts:

- 1) **The central nervous system** which is consisted of the brain and the spinal cord.
- 2) **The peripheral nervous system** which is consisted of 12 pairs of cranial nerves and 31 pairs of spinal nerves and their associated ganglia.

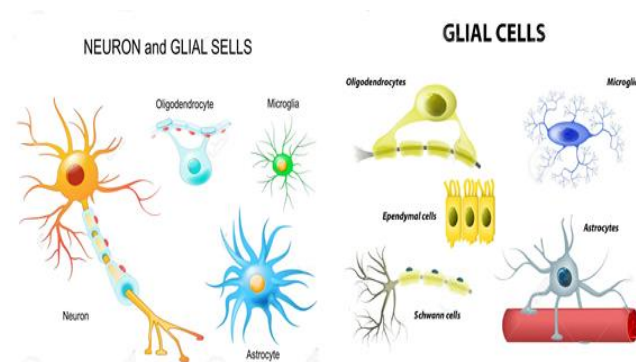


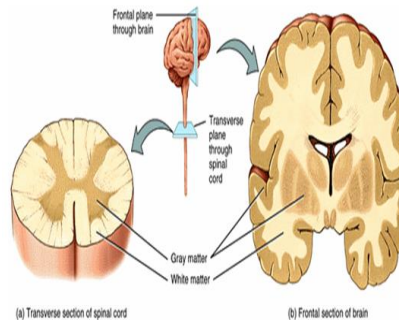
★ Functionally, the nervous system can be divided into:

- 1) **Somatic nervous system** which controls voluntary activities.
- 2) **Autonomic nervous system** which controls involuntary activities.

★ The central nervous system (CNS)

- It is composed of large numbers of nerve cells & their processes, supported by specialized tissue called **neuroglia**.
- **Neuron** is the name given to the nerve cell & its processes. the nerve cell has two types of processes called dendrites & axon. The dendrites are short processes & the axon is the longest process.
- The central nervous system organized into gray & white matter; the gray matter consists of nerve cells embedded in neuroglia. white matter consists of nerve fibers (axons) embedded in the neuroglia





☀ Peripheral nervous system (PNS)

It consists of the cranial, spinal nerves and their associated ganglia. They are made up of bundles of nerve fibers.

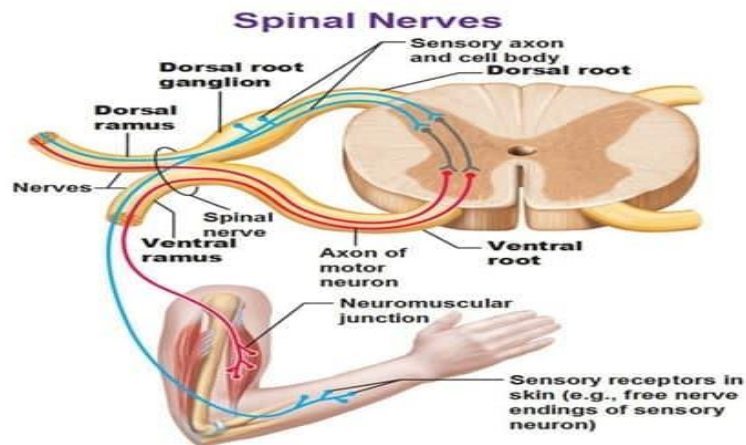
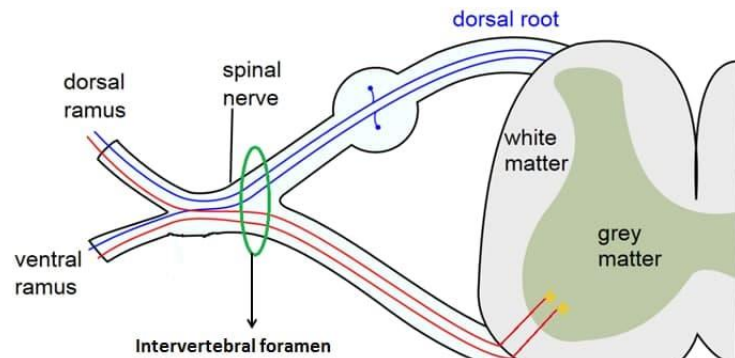
Cranial nerves

- They are 12 pairs of cranial nerves that leave the brain and pass through the foramina in the skull. All the nerves are distributed in the head & neck except the vagus nerve, which supplies structures in the thorax and abdomen.

▪ Spinal nerves

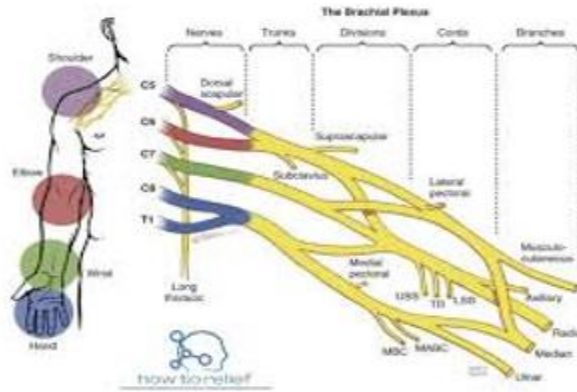
- There are 31 pairs of the spinal nerves that leave the spinal cord and pass through the intervertebral foramina in the vertebral column. The spinal nerves are named according to the region of the vertebral column with which they are associated: (8 cervical, 12 thoracic, 5 lumbar, 5 sacral, 1 coccygeal)
- **Each spinal nerve is connected to the spinal cord by two roots:**
The anterior (ventral) root and the posterior (dorsal) root.
- The anterior root is consisted of bundles of nerve fibers carrying impulses away from the central nervous system, such nerve fibers are called efferent. Those efferent fibers that go to skeletal muscle & cause them to contract are called motor fibers. Their cell of origin lies in the anterior gray horn of the spinal cord. The posterior root consists of bundles of nerve fibers that carry impulses to the CNS & called afferent fibers. Since these fibers are concerned with conveying information about the sensation of touch, pain, temperature & vibration, they are called sensory fibers, the cell bodies of these nerve fibers are situated in a swelling on the posterior root called the posterior root ganglion.
- At each intervertebral foramen, the anterior & posterior root unite to form a spinal nerve, here, the motor & sensory fibers become mixed together, so, the spinal nerve is made up of a mixture of motors & sensory fibers.
- On emerging from the foramen, the spinal nerve divides into a large anterior ramus & a small posterior ramus.

- The posterior ramus passes posteriorly to supply the muscle & skin of the back. The anterior ramus continues anteriorly to supply the muscle & skin of the limbs.
- In addition to the anterior & posterior rami, the spinal nerves give small meningeal branches to the meninges which cover the spinal cord.
- The thoracic spinal nerves have branches called rami communicans that are associated with sympathetic part of the autonomic nervous system.



Plexus

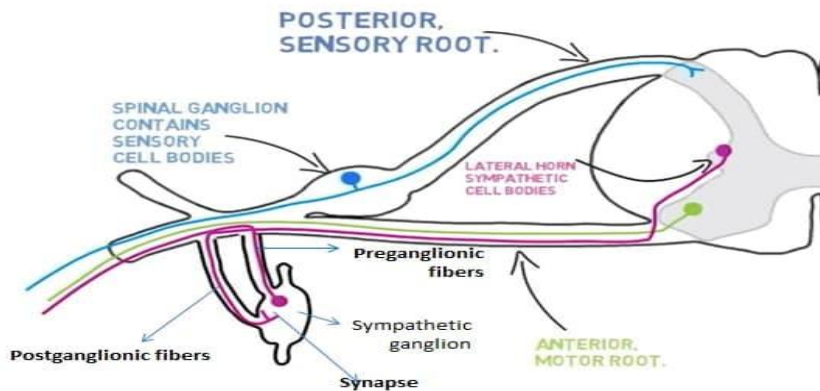
- At the root of the limb, the anterior rami join one another to form complicated nerve plexuses.
- The cervical & brachial plexuses are found at the root of the upper limbs. The lumbar & the sacral plexuses are found at the root of the lower limbs.



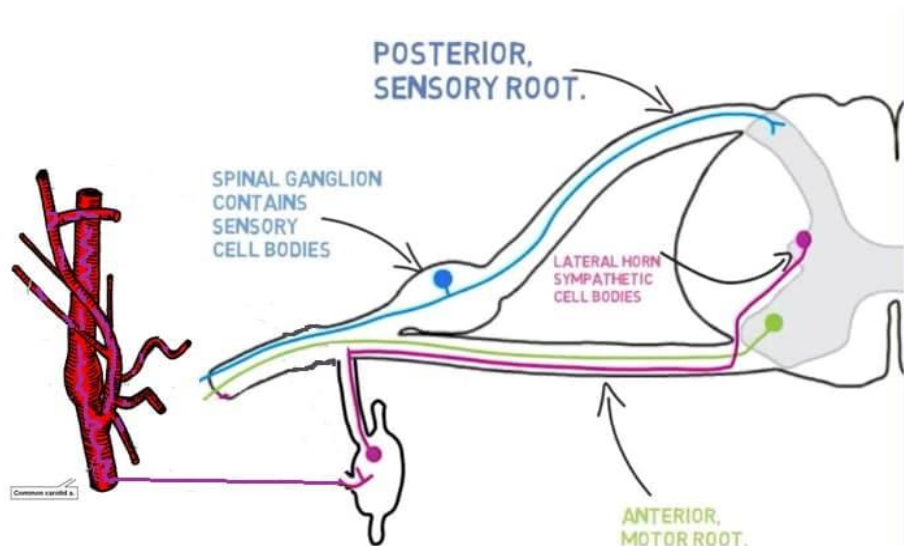
★ The autonomic nervous system

- The autonomic nervous system is the part of the nervous system that is concerned with the innervation of involuntary structures such as the heart, smooth muscles & glands. The autonomic nervous system is divided into two parts, the sympathetic & the parasympathetic, they regulate the actions of viscera by balancing of their opposing action, (e.g. the sympathetic part accelerates the heart rate & raises blood pressure & decreases peristalsis of intestine, while the parasympathetic part slows the heart rate, increases the peristalsis of intestine)
- Each part (sympathetic & parasympathetic) is formed by two sets of neurons, the cell bodies of the first set of neurons are located in the CNS, while the second set of neurons, their cell bodies are located outside of the CNS.
 - **Sympathetic part (thoracolumbar)**
- The gray matter of the spinal cord from the 1st thoracic segment to the second lumbar segment consists a lateral horn in which the cell bodies of the sympathetic neurons are located, along the lateral aspect of the vertebral column, there is a chain of ganglia located opposite most of the spinal nerves, connected with each other by nerve fibers to form sympathetic trunk. The sympathetic trunk in the cervical region, there are 3 ganglia, the superior, middle & inferior. In the thoracic region, there are 10-11 ganglia. In the lumbar, there are 3-4 ganglia. In the sacral 4-5 ganglia.
- The axons of the cells of the sympathetic neuron leave the spinal cord through the vertebral root of the spinal nerve as a preganglionic nerve Fibers. The preganglionic nerve fibers pass to the sympathetic trunk through or as a white ramus communicant. When the preganglionic nerve fibers reach the ganglia in the sympathetic trunk, **they may take one of the four courses:**

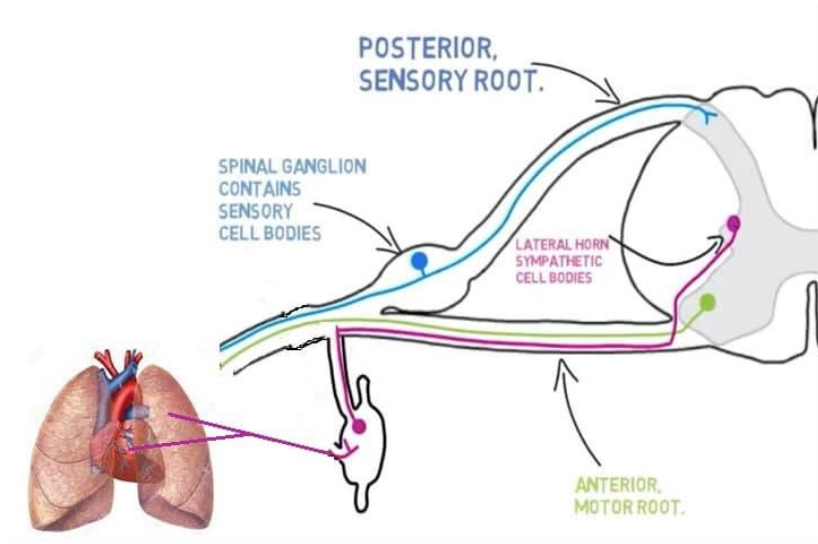
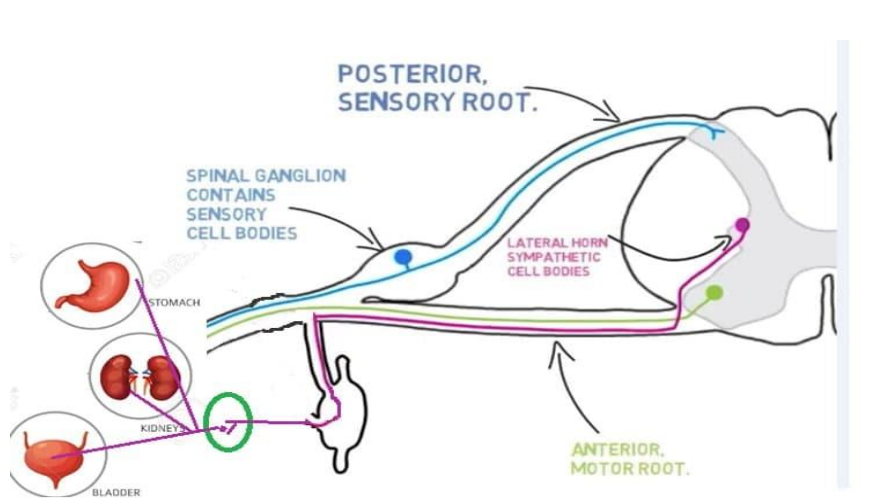
- 1- It may synapse with neuron located in the ganglia and the fibers are called postganglionic fibers which leave the ganglia and join the corresponding spinal nerve through gray ramus communicant. Through the branches of the spinal nerve, it is distributed to supply smooth muscles of the walls of the blood vessels and the sweat glands of the skin.



- 2- It may synapse with neuron located in the ganglia and the fibers called postganglionic fibers which leave the ganglia and join the common carotid artery and its branches (external and internal carotid arteries and their branches) and called perivascular plexus. Through the branches of the arteries, the postganglionic fibers distribute to supply all the involuntary structures located in the head and neck.



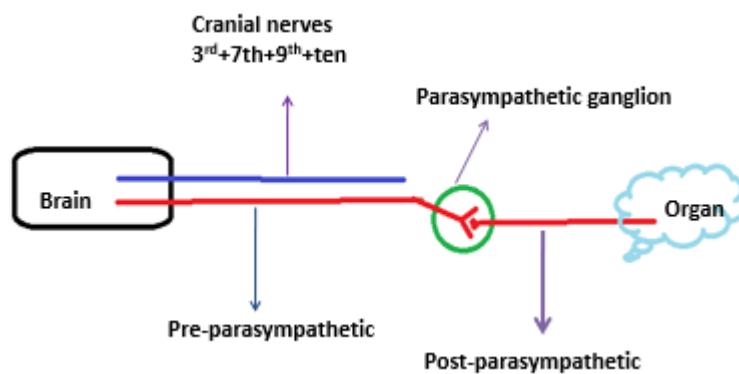
- 3- It may synapse with neuron located in the ganglia and the fibers called postganglionic fibers which leave ganglia and pass directly to the organs to be innervated such as the cardiac plexus which supplies the heart, and the pulmonary plexus which supplies the lungs.
- 4- The preganglionic fibers pass through the sympathetic trunk without any synapse, then they leave the sympathetic trunk as three nerves called (greater, lesser and least splanchnic nerves) and terminate in a ganglion called celiac ganglion in which they synapse, and from it, postganglionic fibers emerge to supply the viscera in abdomen and pelvis.



- The parasympathetic part (craniosacral)

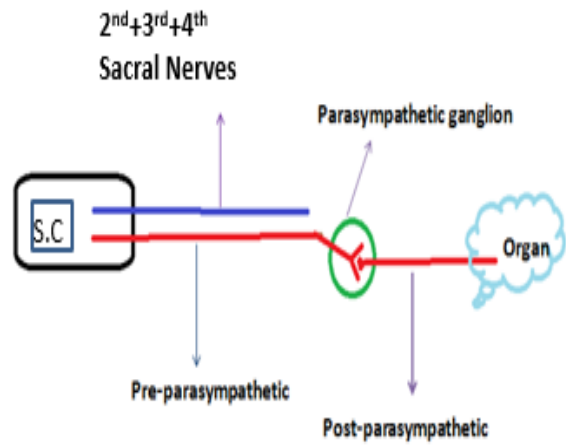
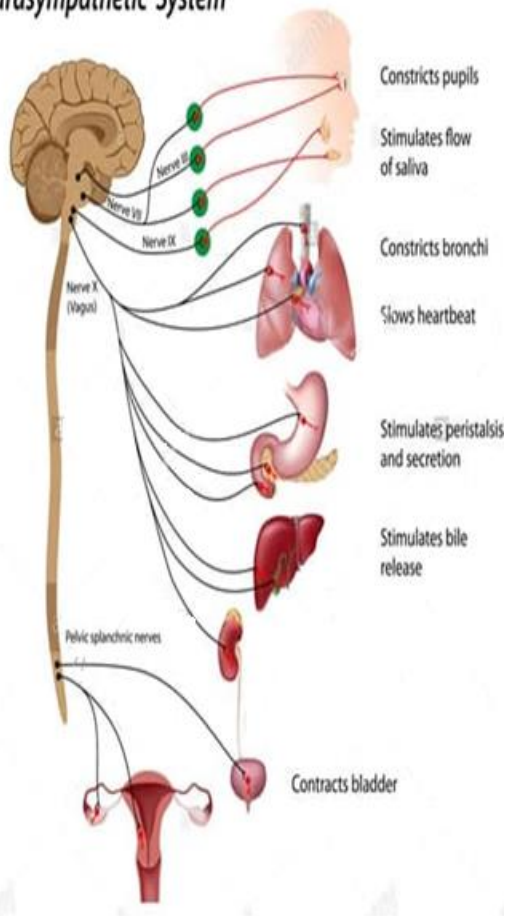
The cell bodies of this part are located in the brain and sacral segments of the spinal cord. Those in the brain are located in the nuclei of origin of the oculomotor, facial, glossopharyngeal and vagus nerves. The pre-ganglionic fibers course is in the corresponding cranial nerves, then they terminate in the ganglion located near or within the viscera or organ to be innervated, they synapse within the neurons located in this ganglion. Then, the post-ganglionic fibers emerge from this ganglion to innervate the organ e.g.:

- 1- **Oculomotor nerve** → ciliary ganglion located in the orbital cavity to supply the sphincter of the pupil muscle and the ciliary muscle.
- 2- **Facial nerve** → submandibular ganglion located in the floor of the mouth to supply the submandibular and sublingual salivary glands.
- 3- **Glossopharyngeal** → otic ganglion located in the infratemporal fossa to supply the parotid gland.



- While those located in the sacral segments, their neurons located in the gray matter of the 2nd, 3rd, and 4th sacral segments of the spinal cord.
- The pre-ganglionic fibers leave the spinal cord in the anterior root of the corresponding sacral nerves (2nd, 3rd, and 4th), then they leave these sacral nerves to enter a ganglion located near or within the wall of an organ to be innervated. The post-ganglionic fibers leave the ganglion to innervate the organ.

Parasympathetic System

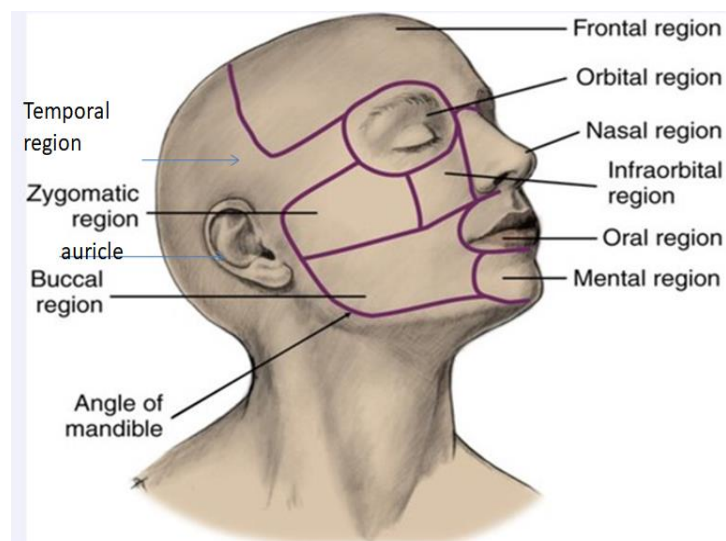
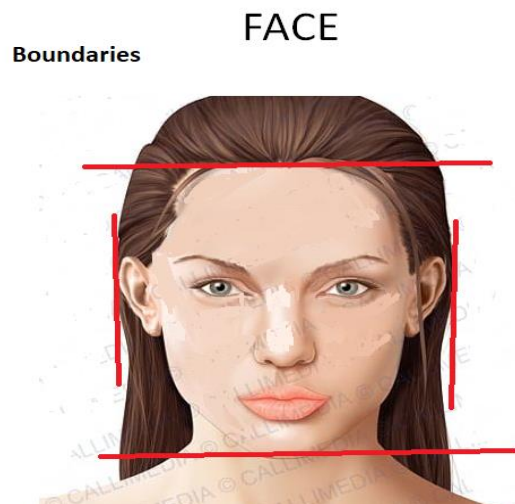


THE FACE

The face extends from the hair margin to the chin, and from one auricle to the other.

The facial region is subdivided into:

- 1- The forehead.
- 2- The temporal area (anterior to the ears).
- 3- The area of the eyes and eyelids.
- 4- The external nose.
- 5- The zygomatic area (the prominence of the cheek).
- 6- The mouth and lips.
- 7- The cheeks.
- 8- The chin.
- 9- The external ear.

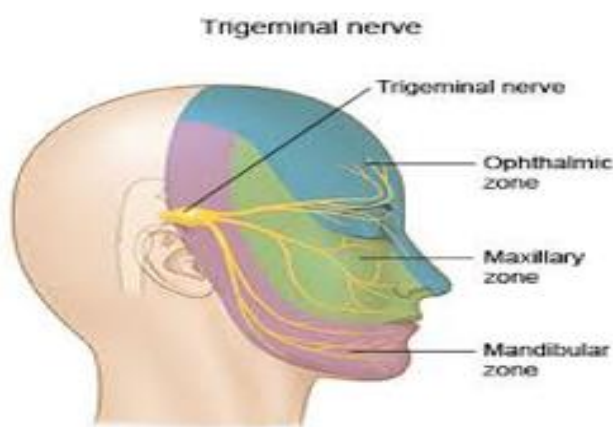


✿ The basic shape of the human face is determined by the underlying facial skeleton, the facial muscles and the amount of subcutaneous tissue present.

✿ No deep fascia is present in the face.

✿ **Sensory nerves of the face**

- The facial cutaneous nerve supply is principally derived from the trigeminal nerve (cranial nerve no. 5).
- Within the skull, the trigeminal nerve is divided into 3 parts:
 - 1) **Ophthalmic N.:** sensory nerve associated mainly with the orbit and its contents.
 - 2) **Maxillary N.:** sensory nerve associated with the Nasomaxillary complex.



3) **Mandibular N.:** sensory and motor nerve associated with the lower jaw and the muscles of mastication.

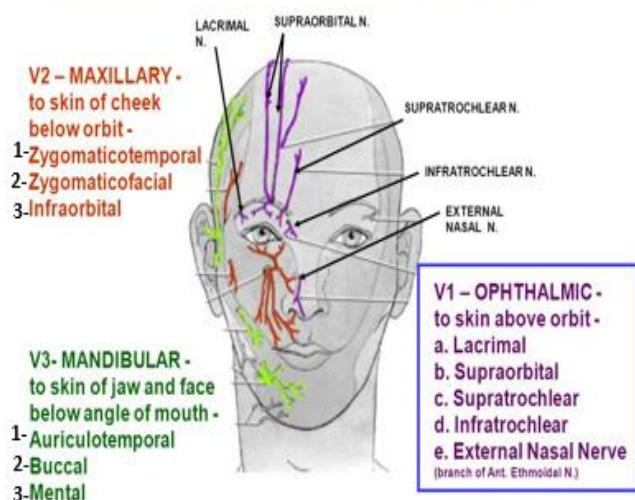
- Each division of trigeminal N. contributes sensory cutaneous branches of the face.

➤ **The ophthalmic nerve**

It contributes several branches to the upper eyelid, the forehead scalp and the external nose.

- 1- **The supraorbital N.:** Emerges from the roof of the orbit through the supraorbital foramen or notch, it supplies a portion of the frontal sinus, a large portion of the upper eyelid, and a large portion of the forehead and the scalp.
- 2- **Supratrochlear N.:** in the orbit, it passes over the pulley or trochlea of the superior oblique M., it emerges from the medial aspect of the superior orbital margin to supply the medial portion of upper eyelid and adjacent forehead.

TRIGEMINAL – SENSORY BRANCHES TO FACE



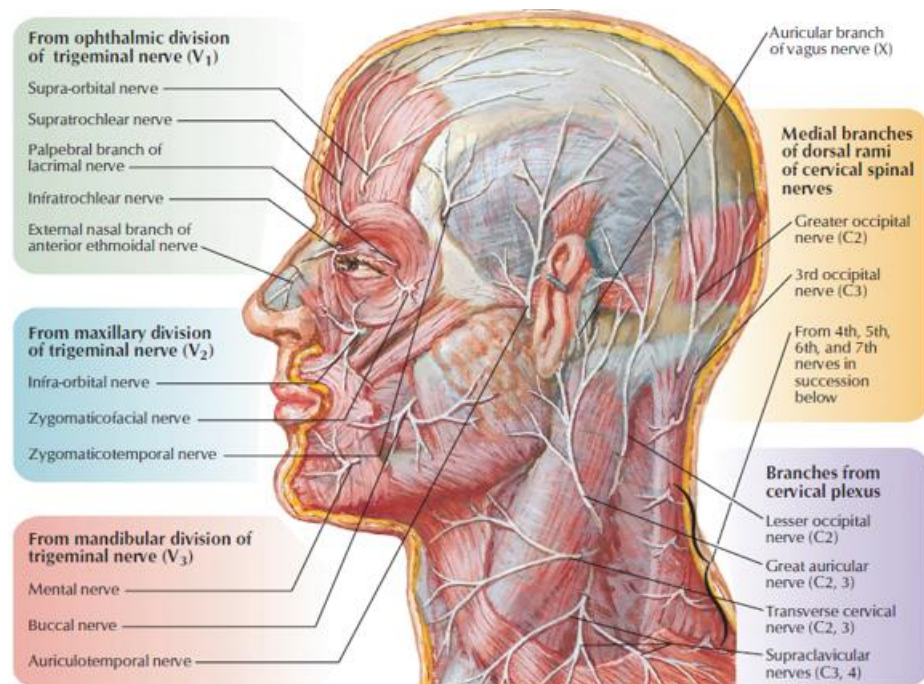
- 3- **The infratrochlear N.:** Passes under the trochlea in the orbit and emerges near the medial angle of the eye. It supplies the medial angle of the upper eyelid and the lacrimal sac.
- 4- **Palpebral N.:** It is a branch of the lacrimal N., which supplies the lacrimal gland. It is a small branch that emerges from the lateral aspect of the superior margin of the orbit to supply a small lateral portion of the upper eyelid.
- 5- **The external nasal N.:** it appears in the midline at the junction of the nasal bone and the nasal cartilage. It supplies the median part of the external nose below the nasal bones as far as the tip .

➤ **The maxillary nerve**

- 1- **The infraorbital N.:** It is the large terminal branch of the maxillary N.; it passes through a bony canal in the orbital floor to emerge into the face through the infraorbital foramen. On the face, it divides into **three branches:**
 - a) **Inferior palpebral branches:** which convey sensation from the skin and conjunctiva of the lower lid.
 - b) **Lateral nasal branches:** which convey sensation from the lateral aspect of the external nose.
 - c) **Superior labial branches:** which convey sensation from the skin and mucous membrane of the upper lip.
- 2- **The zygomaticofacial N.:** It is a small branch which emerges into the face through a bony opening of the same name, it supplies the skin of the zygomatic prominence.
- 3- **The zygomaticotemporal N.:** It passes through the zygomaticotemporal foramen & ascends to supply the skin of the anterior aspect of the temporal fossa & the scalp.

➤ **The mandibular nerve**

- 1- **Auriculotemporal N.:** it passes between the temporomandibular joint and the tragus of the ear, it supplies the upper lateral portion of the external ear, the ear canal, the temporal region, and the lateral aspect of the scalp.
- 2- **Buccal N.:** It appears on the face under the cover of the ramus of the mandible. It spreads over the cheek and conveys sensation from the skin and mucous membrane of the cheek and the buccal gingiva.
- 3- **Mental N.:** it's the termination of the inferior alveolar N. that leaves the mandibular canal through the mental foramen and exits into the face lateral to the skin. **It breaks up into three sets of branches:**
 - a) **Mental branch** → to the skin of chin.
 - b) **Inferior labial branch** → to the skin and mucous membrane of the lower lip.
 - c) **Gingival branch** □ to the labial gingiva of the mandibular teeth



Sensory Innervation and Trigeminal Neuralgia:

The facial skin receives its sensory nerve supply from the three part divisions of the trigeminal nerve, except a small area of skin over the angle of the jaw is supplied by the great auricular nerve (C₂ and 3).

Trigeminal neuralgia is a relatively common condition in which the patient experiences intense pain in the distribution of the mandibular or maxillary division, with the ophthalmic division usually escaping.

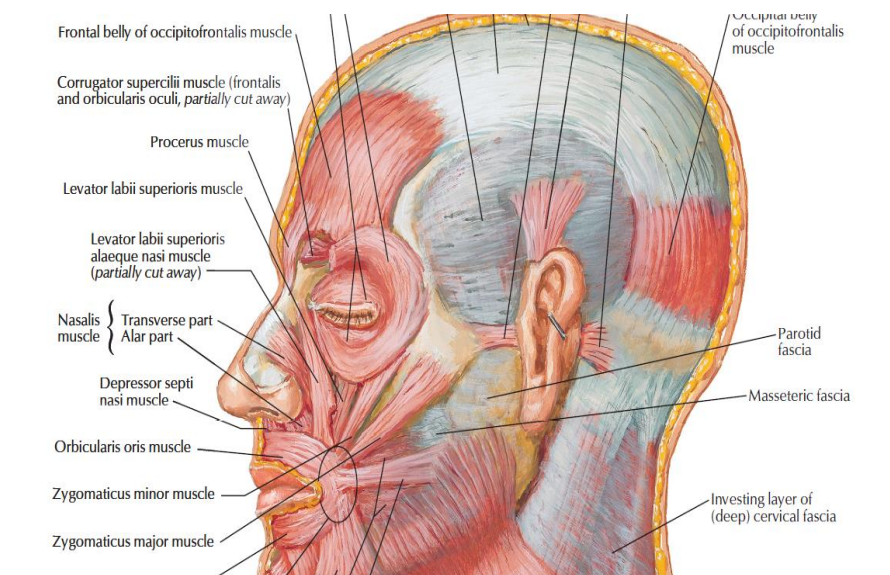
★ Muscles of the face

- The muscles of the face or muscles of the facial expressions are found within the superficial fascia around the facial orifices, the muscles of the scalp and the platysma muscle of the neck belong to the same muscle group.



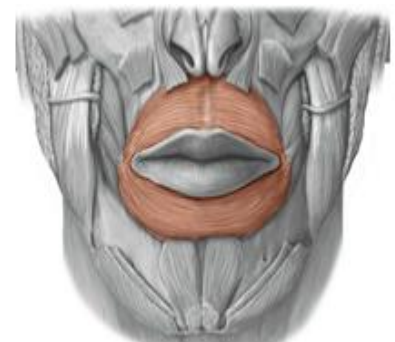
- They perform two functions:
 - 1- As dilators and sphincters, they control the openings of the orifices.
 - 2- As movers of overlying skin, they reflect the various facial expressions.
- Most of the facial muscles originate from the bones or from the fascia, and all insert into the skin of the face.
- During the contraction of these muscles, they move the facial skin into various attitudes that reflect emotions.

➤ There are many muscles, but the main are:



a) Orbicularis oris muscle:

- It is the sphincter of the oral aperture and lies within the upper and lower lips, encircling the mouth. Its fibers originate mainly from the contribution of other facial muscles that converge on the mouth. It closes the oral aperture, presses the lips against teeth and protrudes the lips.



b) Buccinator muscle:

It **arises** from three areas:

- 1- **The pterygomandibular raphe**: which is a thin fibrous band running from the hamulus of the medial pterygoid plate down to the mandible just behind the last mandibular molar tooth.

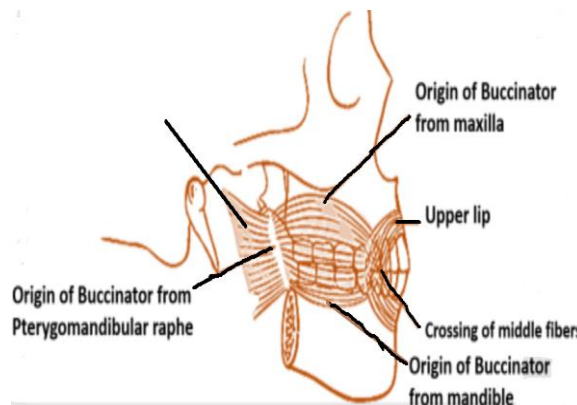
The buccinator muscle and the superior constrictor muscle of the pharynx - are attached to this raphe. The Buccinator is directed to the wall of cheek from the anterior part of the raphe, while the superior constrictor muscle is directed to the wall of the pharynx from the posterior part of the raphe.

2- **The maxillary alveolar process:** the superior fibers of the buccinator muscle originate from the maxillary alveolar process in the molar region.

3- **The mandibular alveolar process:** the inferior fibers of the buccinator muscle originate from the mandibular alveolar process along the posterior half of the oblique line.

The insertion: The muscle fibers sweep anteriorly through the cheek as a flattened sheet. On approaching the angle of the mouth, the upper fibers sweep inferiorly and the lower fibers sweep superiorly to blend with the orbicularis oris muscle and other muscles at the corner of the mouth to form the **modiolus**.

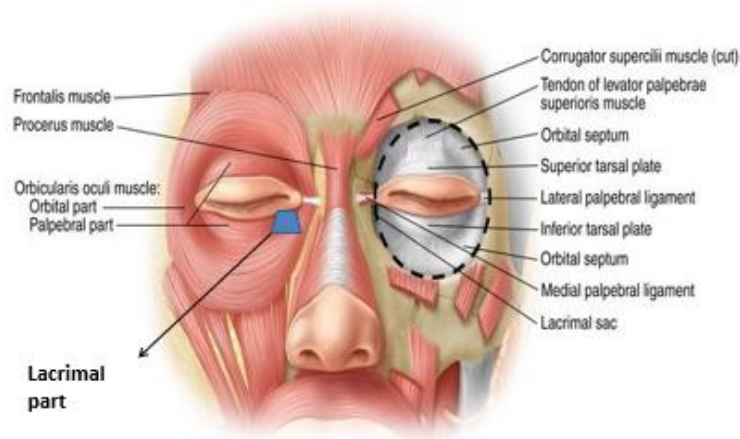
The function: it helps in mastication by pressing the cheek against the vestibular surface of the molar teeth. Sucking by decrease intraoral pressure, expelling air from oral cavity as in playing wind.



c) **Orbicularis oculi muscle:**

It is a sphincter muscle, which acts to close the lids, and it originates as **three components**:

1- **The orbital portion:** Originates from the bone of the upper medial orbital margin, encircles the orbital margin, and inserts from below into the prominent medial palpebral ligament (the ligament anchored to the lacrimal crest of the maxilla).



2- **The palpebral portion:** Arises from the medial palpebral ligament and arches laterally within the upper and lower eyelids to form continuous layer with the orbital part.

3- **The lacrimal portion:** It is a small portion, originates from the lacrimal bone & the lacrimal fossa.

Action:

The palpebral part → closes the eye lightly as in sleeping or blinking.

The orbital part → squeezes the lids to give more protection from bright light or the sun.

The lacrimal part → draws the eyelids medially to promote the flow of fluid (tears).

★ Motor nerves of the face

- The muscles of the face are supplied by the facial nerve (7th cranial nerve).
- The facial nerve exits from the skull through the stylomastoid foramen at the base of the skull, then passes inferiorly and anteriorly and enters the substance of the parotid gland and here it breaks up into five main groups of branches, which radiate from the anterior margin of the gland and travel to various areas of the face.

1- **Temporal branches:** travel superiorly and anteriorly to supply facial muscles situated above the zygomatic arch, including the orbit and forehead.

2- **Zygomatic branches:** travel Transversely across the face to supply facial muscles in the zygomatic, orbital, and infraorbital areas.

3- **Buccal branches:** supply the muscles of cheek.

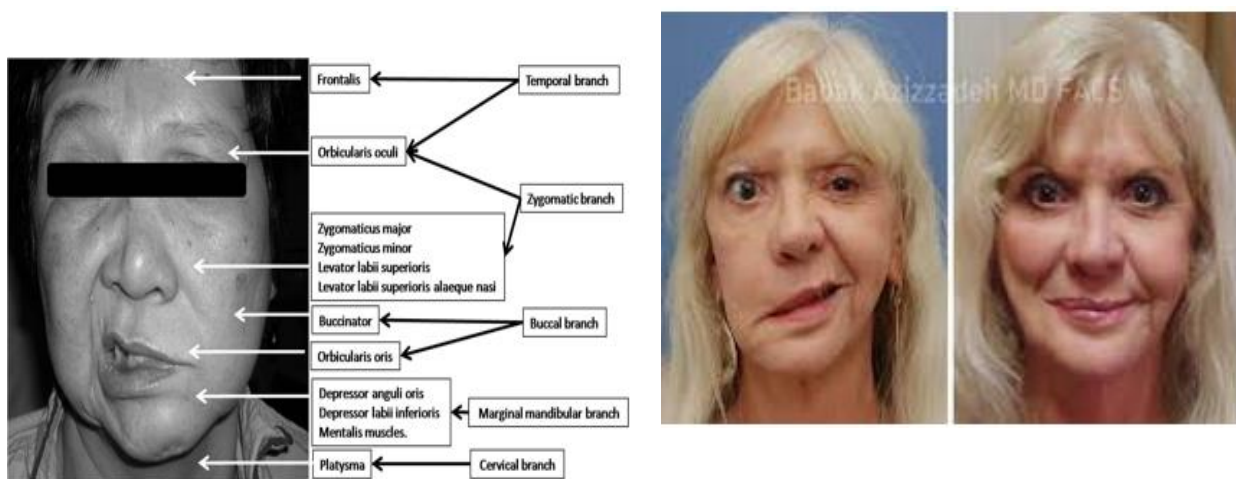
4- **Marginal mandibular branches:** supply muscles of the chin and lower lip.

5- **Cervical branches:** descend to the neck to supply the platysma muscle.

☀ Bell's palsy or facial palsy:

Damage to the facial nerve (by a tumor), in the middle ear (by infection or operation), in the parotid gland (by a tumor) , caused by lacerations of the face or as a complication of an inferior alveolar nerve block, will cause

- 1- The patient cannot blink.
- 2- The patient cannot whistle.
- 3- Accumulation of food in the vestibule.
- 4- saliva and food (drooling) tend to escape from the corner of the mouth.
- 5- Slurred speech.
- 6- The corner of the mouth sag (drooping) on the affected side.
- 7- loss of facial expression on affected side, such as the nasolabial fold.



➤ Sensory nerve communications:

The motor branches of the facial N. communicate with the cutaneous branches of the trigeminal N. on the face and those communications represent sensory proprioceptive contributions, which distribute with the facial N. branches to the various facial muscles.

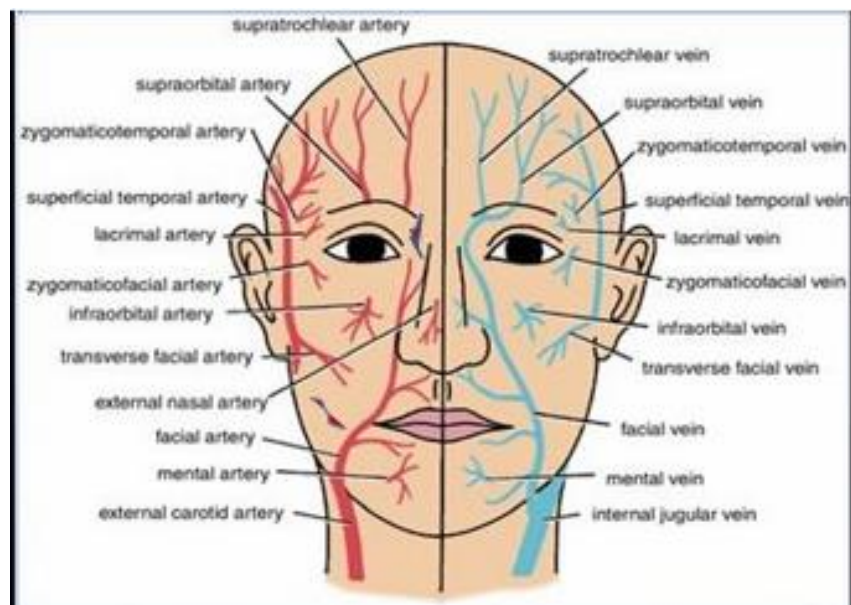
Arteries of the face:

- The face is richly supplied with blood from various arteries, and the terminal branches anastomose freely.
- The entire blood supply is derived from either the internal or external carotid arteries.

A) Facial branches of the ophthalmic artery:

- Arise directly or indirectly from the ophthalmic artery of the orbit:

1. **Supraorbital artery:** It leaves the orbit (with the supraorbital N.) through the supraorbital notch or foramen, to supply the upper eyelid, forehead and scalp.
2. **Supratrochlear artery:** It emerges medial to the supraorbital artery and supplies the upper lid, forehead and scalp.
3. **Dorsal nasal artery:** This is the companion artery to the infratrochlear nerve. It emerges from the medial angle of the orbit to supply the medial upper lid, the lacrimal sac, and the upper part of the nose.
4. **Lacrimal artery:** This is the small terminal portion of the ophthalmic artery, which emerges at the lateral aspect of the supraorbital margin to supply the lateral aspect of the upper lid.
5. **External nasal artery:** It is the terminal branches of the anterior ethmoidal artery, which arises from the ophthalmic artery, it passes at the junction of the nasal bone and the lateral nasal cartilage.
6. **Zygomatic artery:** It is a branch from the lacrimal artery, passes through the zygomatic canal in the lateral wall of the orbit and divides into **two terminal branches**, which emerge on the face:
 - a. **The zygomaticofacial artery:** emerges through the zygomaticofacial foramen to supply the skin of the prominence of cheek.
 - b. **The zygomaticotemporal artery:** emerges through the zygomaticotemporal foramen to supply the skin of the anterior temporal region.



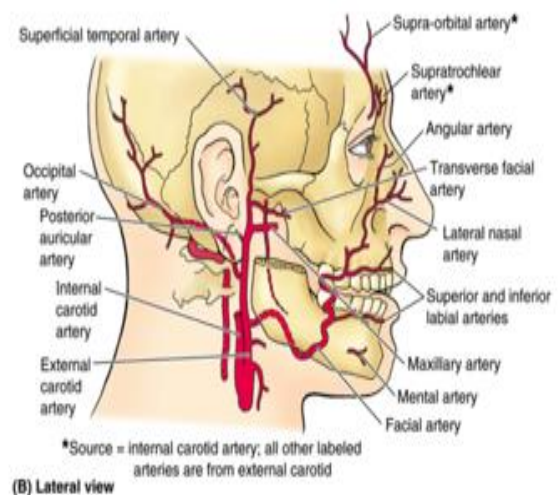
B) Facial branches of the maxillary artery:

1. **Infraorbital artery:** It passes through the infraorbital foramen below the orbit and immediately breaks up into:
 - a. Inferior palpebral branches to the lower eyelid.
 - b. Nasal branches to the lateral aspect of the nose.
 - c. Superior labial branches to the upper lip.
2. **Buccal artery:** It appears from under the cover of the ramus and masseter muscle. It is divided in the cheek, supplying the skin and mucous membrane of the cheek and vestibular gingiva of mandibular molar area.
3. **The mental artery:** The mental artery branches from the inferior alveolar artery within the mandibular canal of the mandible. It exits through the mental foramen along with the mental nerve to supply the chin, lower lip and the vestibular gingiva of the mandibular anterior teeth.

C) The branches of the facial artery:

- The facial artery is a branch from the external carotid artery, it leaves the submandibular region of the neck and ascends on the inferior border of the mandible.
- As it ascends obliquely on the face, it follows a tortuous route toward the medial angle of the eye.
- It passes between the more superficial and deep muscles of the facial expressions. It supplies several branches to the face that anastomose freely with the terminal branches of the maxillary and ophthalmic arteries.

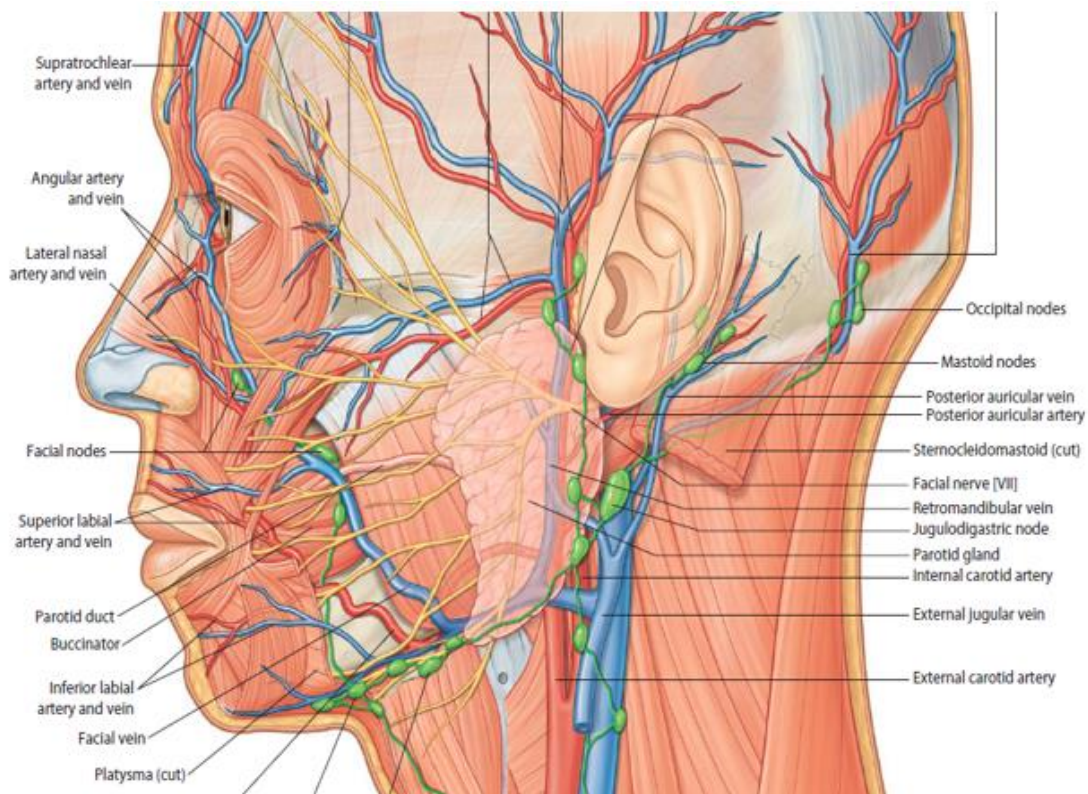
1. **Labial branches:** As the facial artery travels tortuously toward the medial angle of the mouth, it gives off the:
 - a. **Inferior labial artery** to the lower lip.
 - b. **Superior labial artery** to the upper lip.



2. **Nasal branches:** They are given to the side of the nose and they anastomose with the nasal branches of infraorbital artery and the external nasal artery.
3. **Angular artery:** The facial artery ends in the medial angle of the eye as the angular artery. It provides branches to the nose and medial aspect of the lids.

D) Facial branches of the superficial temporal artery:

- The Superficial Temporal Artery is a terminal branch of the external carotid artery.
- It emerges into the face between the jaw joint and the ear to ascend on the scalp. Just below the ear, it sends a branch forward as Transverse facial artery immediately below the zygomatic arch.



Facial Arteries and Taking the Patient's Pulse:

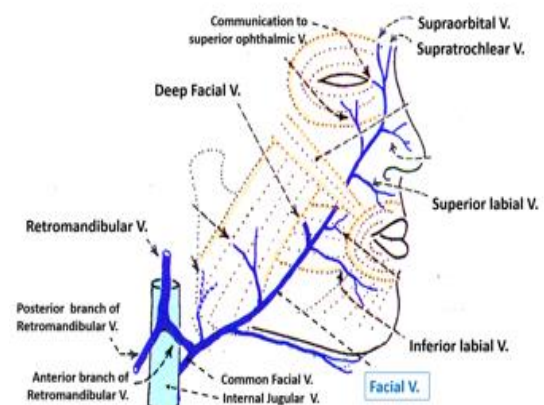
The superficial temporal artery, as it crosses the zygomatic arch in front of the ear, and the facial artery, as it winds around the lower margin of the mandible level with the anterior border of the masseter, are commonly used by the anesthetist to take the patient's pulse.

- **The veins of the face:**
- The veins of the face follow somewhat the same pattern of distribution as the arterial supply, veins in several show more variability in their distribution than the arteries.

- For each of the named arteries described previously as facial branches of the ophthalmic artery or maxillary, there are corresponding veins of the same name that flow in the opposite direction.
- The veins of the forehead, scalp, and upper lid flow to the superior ophthalmic vein in the orbit, the vein of the upper lip, lateral nose and lower lid flow through the infraorbital vein to the pterygoid plexus of veins in the infraorbital region.

➤ The facial vein:

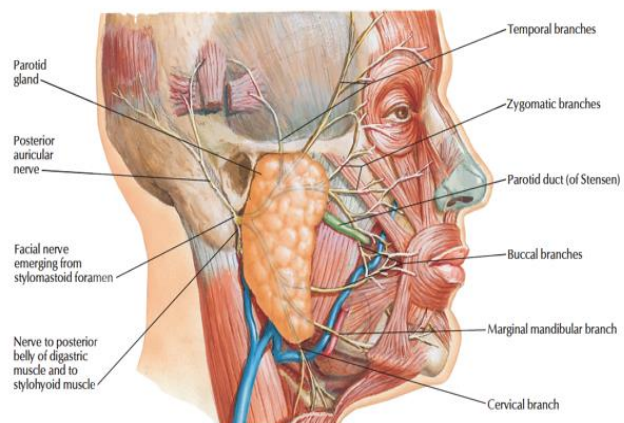
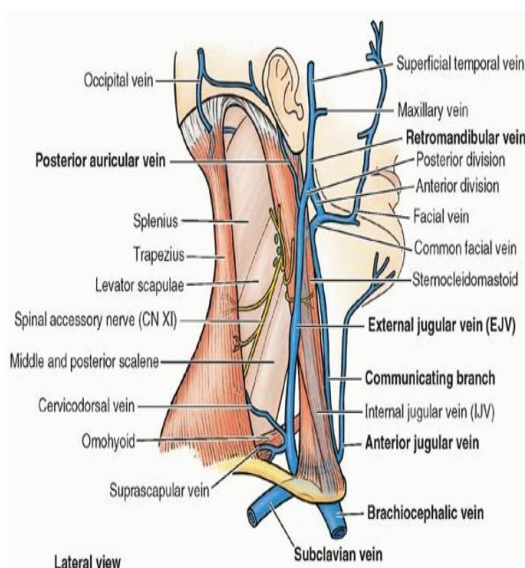
- The facial vein is nearly parallel to the course of the facial artery. It is however more posterior, takes a straighter and less tortuous course, and travels in the opposite direction. **The facial vein originates and gathers tributaries in the following manner:**
 1. **The angular vein:** Forms at the medial angle of the eye by the union of the supraorbital and the supratrochlear veins. The angular vein divides, one division passes into the orbit to drain to the superior ophthalmic vein, and the other division remains superficial and passes inferior as facial vein.
 2. **Facial vein:** passes posteriorly toward the angle of the jaw, and as it descends, it takes several tributaries.
 3. **Nasal vein:** drains the side of the nose and communicates with tributaries of the infraorbital vein.
 4. **Deep facial vein:** communicates with the pterygoid plexus of veins deep within the infratemporal region.
 5. **Labial vein:** drains the upper and lower lips. The superior labial vein communicates with the infraorbital vein, the inferior labial vein communicates with the mental vein.
- Then the facial vein descends over the inferior border of the mandible to enter the submandibular region of the neck. Unlike the facial artery, the vein takes a superficial course through the submandibular region.



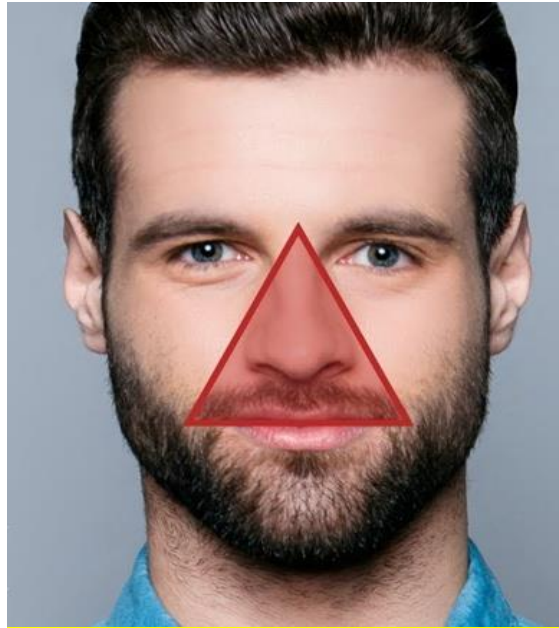
➤ The retromandibular vein:

It is formed by two sources:

1. **Superficial temporal vein:** which drains the scalp and the side of the head. It descends anterior to the ear into the substance of the parotid gland, here it unites with the maxillary vein.
2. **Maxillary vein:** it is formed from the pterygoid plexus of veins. The plexus organizes posteriorly as maxillary vein. The maxillary vein travels posteriorly deep into the neck of the condyle, and joins the superficial temporal vein within the parotid gland to form the retromandibular vein.
 - **Retromandibular vein:** continues inferiorly and leaves the gland at its inferior bound.
 - At the angle of the mandible, it divided into **anterior** and **posterior** divisions in the neck.
 - a. **The posterior division** of the retromandibular vein unites with the posterior auricular vein behind the ear to form the external jugular vein.
 - b. **The anterior division** of the retromandibular vein joins the facial vein in the neck to form the common facial vein.
 - **The common facial vein drains deep to the internal jugular vein.**



DANGER TRIANGLE OF THE FACE:



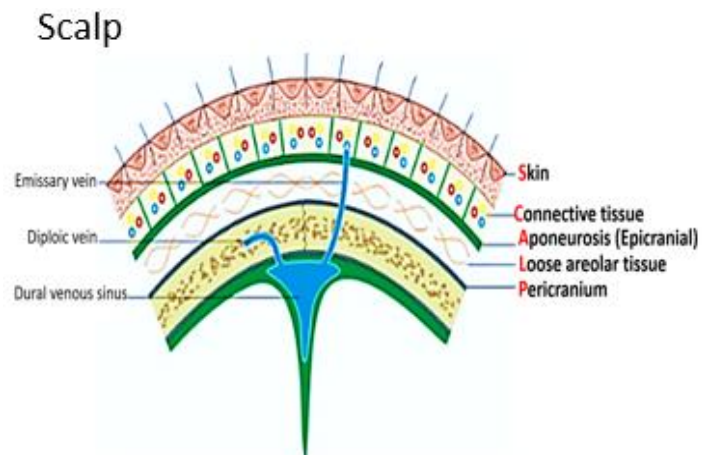
The danger triangle of the face consists of the area from the corners of the mouth to the bridge of the nose, including the nose and maxilla. It is possible, infection from the nasal area to spread to the brain, causing cavernous sinus thrombosis, meningitis or brain abscess. For example, a boil in this region can cause thrombosis of the facial vein. The facial vein does not contain valves; thus, blood flow may pass in either direction and into other venous vessels that may be connected to the cavernous sinus located in the dural venous sinus deep within the cranium. These connections include the superior ophthalmic vein, pterygoid venous plexus, inferior ophthalmic vein, and/or the deep facial vein. Infections in the face, especially in the “triangular danger zone of the face” may cause inflammation of the facial vein and development of thrombophlebitis (clot formation) of the facial vein. Pieces of the infected clot may become free to eventually pass into the cavernous sinus, giving rise to thrombophlebitis of the cavernous sinus—a life-threatening situation if left untreated.

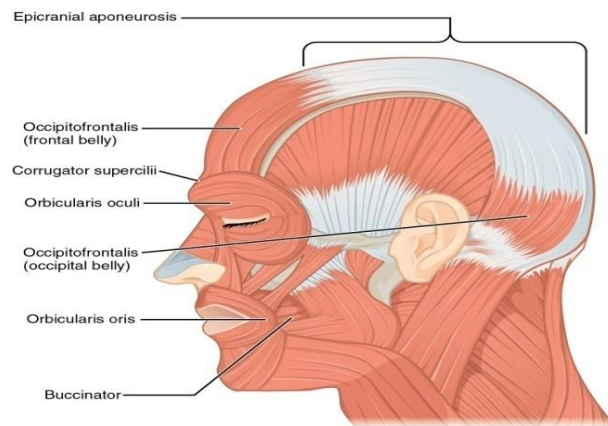
THE SCALP

The scalp covers the vault of the skull and extends between the left and right temporal lines laterally, the eyebrows (supraorbital margins) anteriorly and the superior nuchal lines posteriorly, thus the forehead (which extends between the eyebrows and the hair margin) is common to the face and the scalp.

➤ Layers of the scalp:

- 1- **Skin:** a layer of thin skin containing numerous hair follicles, sweat glands and sebaceous glands, it covers the scalp.
- 2- **Connective tissue:** a thick dense subcutaneous connective tissue is anchored firmly to the skin above and the membranous layer below. Numerous arteries and veins are found in this layer. The arteries are branches of the external and internal carotid arteries, and a free anastomosis takes place between them.
- 3- **Aponeurosis:** The membranous aponeurosis (galea aponeurotica) is an intermediate tendon for the two fleshy bellies of the occipitofrontalis (Epicranius) muscle.
 - The occipital. portion originates just above the superior nuchal line and inserts into the aponeurosis. It pulls the scalp backwards.
 - The frontalis portion originates from the aponeurosis and inserts into skin above the eyebrows. It pulls the scalp forwards and produces transverse wrinkling of the brow.
- 4- **Loose connective tissue:** It is formed by loose c. t., which allows freedom of movement of the superficial three layers over the top of the skull.
- 5- **Periosteum:** It is firmly anchored to the underlying bone.





➤ Blood supply

- The blood supply to the scalp arises from various sources but mainly from branches of the ophthalmic and external carotid arteries. **The arteries are:**
 - 1) Supra trochlear A.
 - 2) Supraorbital A.
 - 3) Zygomaticotemporal A.
 - 4) Superficial temporal A.
 - 5) Posterior auricular A.
 - 6) Occipital A.

➤ Sensory nerve supply

The cutaneous nerve supply arises from three divisions of the trigeminal nerve anterior to the ear and spinal cutaneous nerves from the neck posterior to the ear.

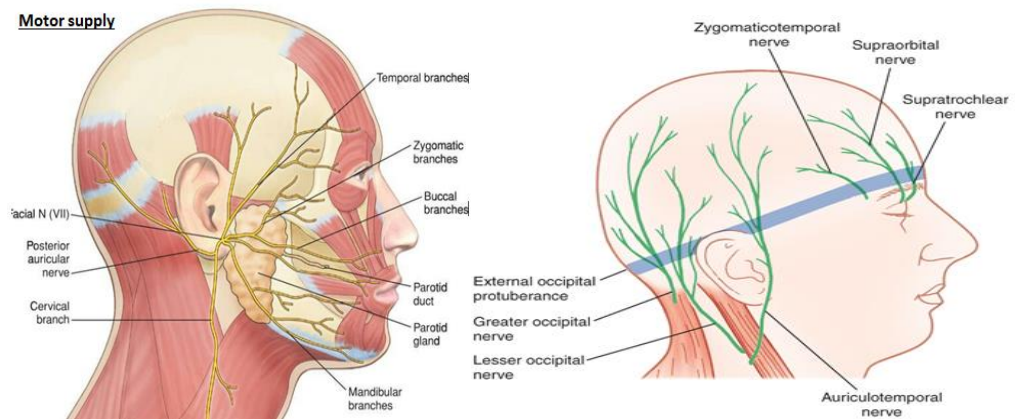
- The nerves anterior to the ear are:
 - 1- Supratrochlear N.
 - 2- Supraorbital N.
 - 3- Zygomaticotemporal N.
 - 4- Auriculotemporal N.
- The nerves posterior to the ear are:
 - 1- Lesser occipital N. (C2+C3)
 - 2- Greater occipital N. (C2)
 - 3- Third occipital N. (C3)

➤ The motor nerve supply

The facial Nerve supplies the occipitofrontalis muscle:

- 1- **Temporal branches:** which supply the facial muscles above, the zygomatic arch including the frontal belly.

2- **Posterior auricular nerve:** Leaves the facial nerve as it emerges from the stylomastoid foramen and runs above the superior nuchal line to supply the occipital belly of the occipitofrontalis muscle.



Bleeding in the scalp is extremely difficult to stop and is dangerous. The blood supply is extensive and the vessels pass through fibrous septa of the superficial fascia, which mechanically inhibit vessel contraction.

Hemorrhage in this region has a tendency to be contained in the loose connective tissue, the subaponeurotic layer.

The scalp has a profuse blood supply and even a small laceration of the scalp can cause severe blood loss. Local pressure applied to the scalp is the only satisfactory method of stopping the bleeding. It is important in all deep wounds of the scalp, if the aponeurosis has been divided, the wound will gape open. For satisfactory healing to take place, the opening in the aponeurosis must be closed with sutures.

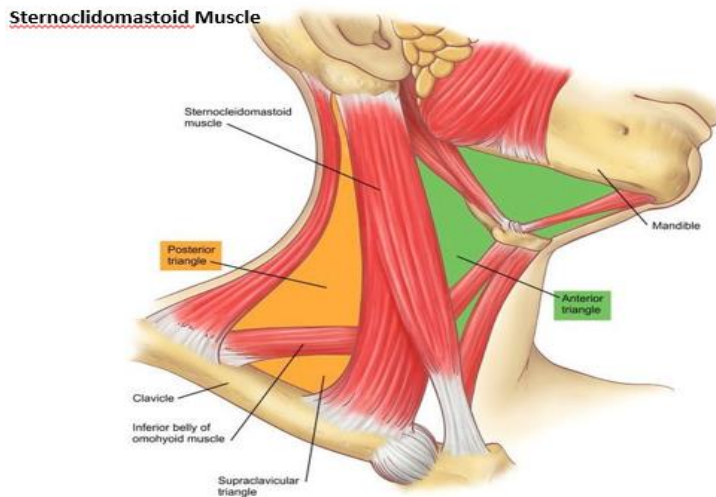
Furthermore, infection may result in a localized abscess that, having no outlet to the surface, may enter the valveless emissary veins of this region, also known as the “danger zone of the scalp,” and travel to the diploë and/or the dural venous sinuses. Such infection may result in osteomyelitis.

The skin of the scalp possesses numerous sebaceous glands, the ducts of which are prone to infection and damage by combs. For this reason, sebaceous cysts of the scalp are common.

THE NECK

- The neck (cervix) is the narrow and flexible portion between the head above and the chest below.
- Functionally, the neck can be divided into Four areas or units:
 1. **Vertebral unit:** The vertebral unit includes the cervical portion of the vertebral column and its musculature. Postvertebral muscles extend the neck and head; prevertebral muscles flex the neck and head. Passing through the vertebral canal, the cervical portion of the spinal cord, which gives rise to 8 pairs of spinal nerves.
 2. **Visceral unit:** Contained within the visceral unit, the food and air passages, that are, the larynx and pharynx above vertebral level C6. The thyroid gland is found lateral to the trachea and larynx as two lateral lobes joined by an isthmus.
 3. **Carotid unit:** Lateral to the visceral unit are bilateral tubes of fascia extending from the base of the skull to the thoracic inlet. **Contained within the carotid sheaths are:**
 - a. Common Carotid artery.
 - b. Internal jugular vein.
 - c. Vagus nerve.
 4. **Muscular unit:** Laterally and anteriorly are two groups of muscles. The lateral group includes the sternomastoid and the trapezius muscles. Anteriorly, there is a group of infrahyoid muscles which occupy the interval between the hyoid bone above and the manubrium of the sternum below.
- **Divisions of the neck:**
 - To facilitate the study of the neck, it is divided into a number of small regions or triangles by using several Key muscles.
 - **These muscles are:**
 - 1- Sternomastoid.
 - 2- Trapezius.
 - 3- The anterior and posterior bellies of digastric muscle.
 - 4- Inferior and superior bellies of omohyoid muscles.

- The muscles divide the neck into two major triangles and several smaller triangles. **These are:**
 - 1- The posterior triangle and its components, the occipital and the supraclavicular triangles.
 - 2- The anterior triangle and its components, the submandibular, submental, Carotid and muscular triangles.



FASCIA OF NECK

A- Superficial Cervical Fascia

Located deep to the skin and it includes the platysma muscle.

B- Deep Cervical Fascia

The deep cervical fascia deep to the superficial fascia and platysma muscle. This fascia is organized or divided into :

1- The investing layer :

It surrounds the trapezius, sternocleidomastoid and infrahyoid muscles. •
 ((The investing layer of the deep fascia extends from the hyoid bone and, as it reaches the mandible, it splits into medial and lateral leaflets to encase the bone. It then passes to the zygomatic area. The fascia covers the muscles of the floor of the mouth and also encapsulates the submandibular gland and encloses the masseter and medial pterygoid muscles as they insert into the mandible. Moreover, the fascia forms a capsule around the parotid gland)). •

2-Pretracheal fascia

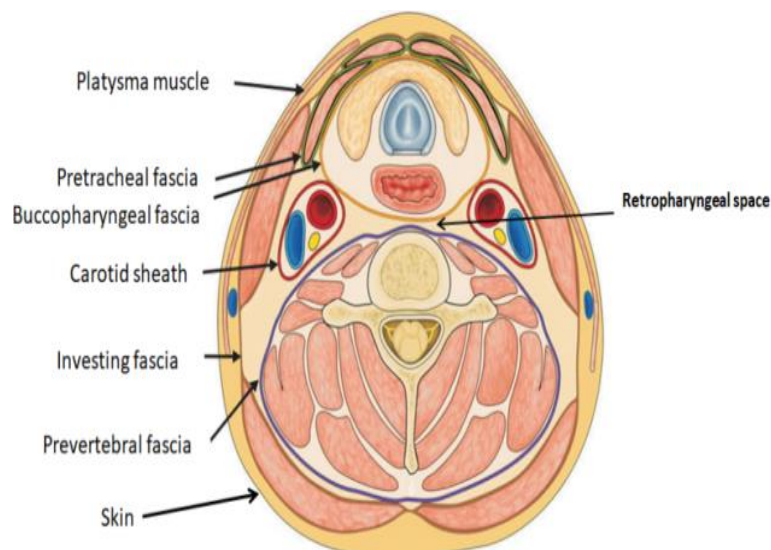
The pretracheal fascia is situated in the anterior aspect of neck. The trachea, oesophagus, thyroid gland are enclosed by the pretracheal fascia. The posterior aspect of this fascia called buccopharyngeal fascia (a fascia covering the pharynx).

3- Prevertebral fascia:

- This fascia invests the vertebral unit (the cervical portion of the vertebral column and its musculature)
-
- **4- The carotid sheaths (carotid fascia):**
are paired tube like structures on either side of the neck, which enclose an important neurovascular bundle of the neck, these are:

1- Common carotid artery 2- Internal jugular vein 3- Vagus nerve.

Clinical note: Retropharyngeal space – located between the buccopharyngeal fascia (posterior aspect of the pretracheal fascia) and the prevertebral fascia. Extends from the base of the skull to the posterior mediastinum of thorax. So the infection could spread from neck to chest through this space.



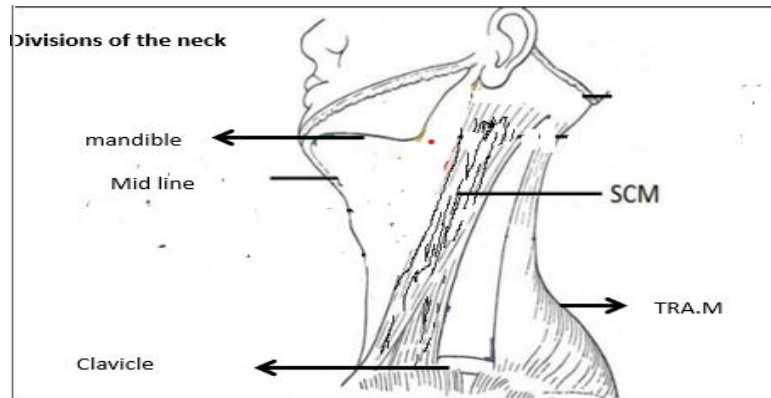
POSTERIOR TRIANGLE

- **Boundaries:**

Base: middle third of the clavicle.

Anterior border: posterior border of sternomastoid muscle.

Posterior border: anterior border of Trapezius muscle.



- **Roof:**

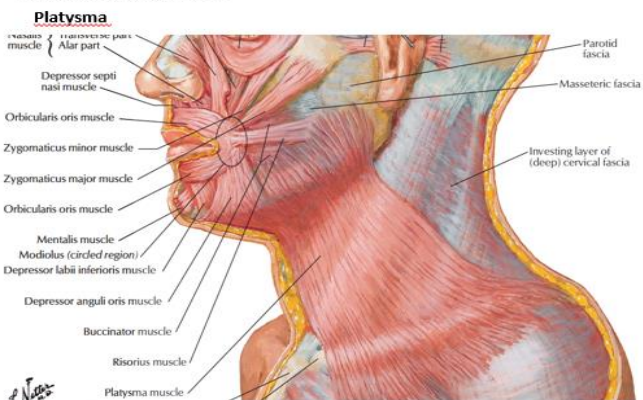
1. Skin
 2. Superficial fascia and platysma muscle (which is one of the muscles of facial expressions within the superficial fascia)
- Origin of platysma muscle:** from pectoral fascia.

Inserts in the corner of the mouth and the lower border of the mandible.

Action: tense the skin of the neck.

Nerve supply: cervical branch of facial nerve.

Posterior triangle: Roof



Posterior triangles: boundaries



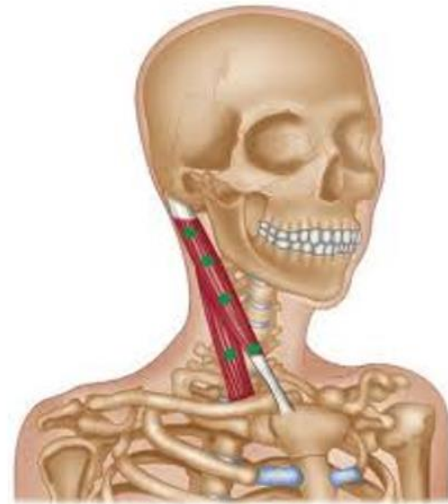Sternomastoid muscle:

Origin and insertion: from two bones, one of them is from the head of the manubrium of sternum and the second is from the medial third of clavicle. They are directed upward and backward to insert in mastoid process and lateral half of superior nuchal line.

Action: Bilaterally > flex the neck.

Unilateral > flex and rotate the head to opposite side.

Nerve supply: spinal part of the accessory nerve.



Congenital Torticollis

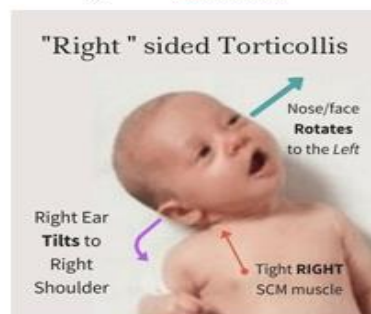Most cases of congenital torticollis are a result of excessive stretching of the sternocleidomastoid muscle during a difficult labor. Hemorrhage occurs into the muscle after birth.

Later, this becomes invaded by fibrous tissue, which contracts and shortens the muscle.

Spasmodic Torticollis (wry Neck)

Spasmodic torticollis, which results from repeated chronic contractions of the sternocleidomastoid and trapezius muscles, is usually psychogenic in origin.

Congenital Torticollis



Spasmodic Torticollis



Trapezius muscle:

It's found in the back of the neck and the back of the chest.

It's the largest muscle in the body.

Origin:

1. External occipital protuberance
2. Medial half of the superior nuchal line
3. Ligamentum nuchae
4. Lower cervical and all thoracic

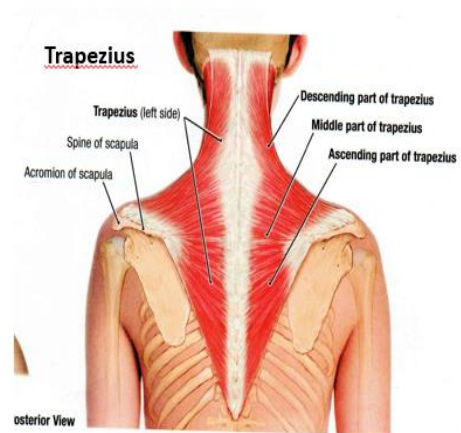
Insertion: Upper part (head) > lateral third of the clavicle.

Lower > spine of the scapula.

Action: Bilateral > extension

Unilateral > elevate and rotate the scapula

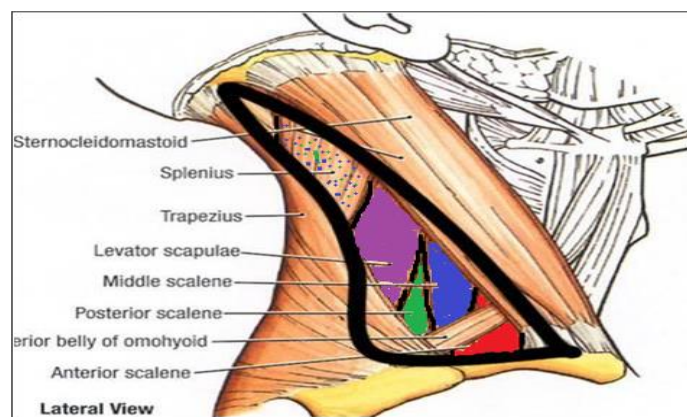
Nerve supply: Spinal part of the accessory nerve.



- **Floor of the posterior triangle:**

1. Splenius capitis
2. Levator scapulae
3. Scalenus posterior
4. Scalenus middle
5. Scalenus anterior

Floor of posterior triangle



- **Contents of the posterior triangle:**

- 1) **External Jugular vein:**

The retromandibular vein divides into anterior and posterior branches. The **posterior branch** and **posterior auricular** form the **EJV**, which passes downwards to the posterior triangle.

It receives 3 tributaries:

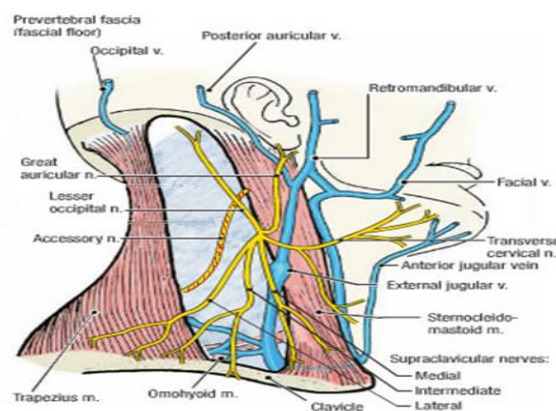
- Transverse cervical vein
- Suprascapular vein
- Anterior jugular vein

The external jugular vein may be used as a venous manometer because in a supine patient the venous blood pressure is not high enough to engorge this vessel much above the clavicle. During failure of the right side of the heart, constriction of the superior venae cavae and increased pressure in the thorax induces a pressure buildup in the venous side of the circulatory system, and this is evidenced by engorgement of the external jugular vein. Under severe conditions, the vessel may be filled as high as the base of the mandible. This extremely important sign should be recognized by dental professionals in their practice; the patient should be referred immediately for possible cardiac care.

The external jugular vein tends to be enlarged and often tortuous in professional singers because of prolonged periods of raised intrathoracic pressure.

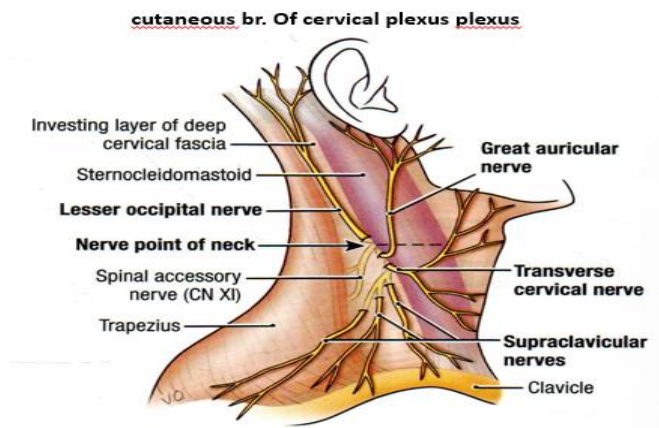
The **Anterior jugular vein** located in the anterior aspect of the neck on each side, descends downward vertically, above the jugular notch, it passes deep to the sternomastoid muscle and then empties in the external jugular vein.

The two anterior jugular veins communicate above the jugular notch which is called **Anterior jugular arch**



2) **Cervical plexus (will be discussed later)**: from the cervical plexus arise cutaneous nerves:

- I. **Lesser occipital nerve**: which passes upwards along the sternomastoid muscle and supplies the skin in the occipital and the mastoid regions.
- II. **Greater auricular**: it is a large nerve, crosses the sternomastoid muscle obliquely and divides into 2 branches:
Posterior >supplies the auricle.
Anterior >supplies the skin on the angle of the mandible and parotid region.
- III. **Transverse cervical**: it crosses the sternomastoid muscle transversely and enters the anterior triangle.
Supplies the skin in sides and front of neck.

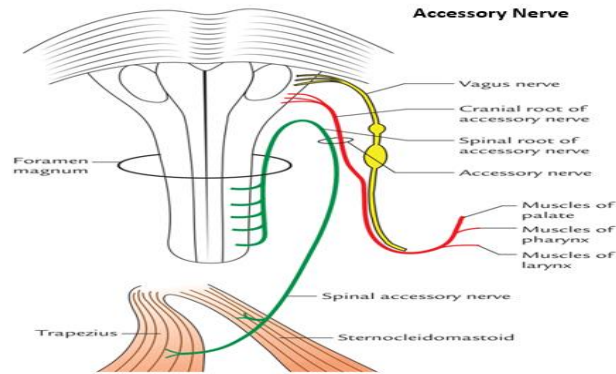


- IV. **Supraclavicular**: descends downward and divides into 3 divisions: **Medial, intermediate and lateral**.
Supply the skin of the neck from the head of the sternum to the lateral aspect of clavicle.

2) **Accessory nerve: XI**

From the cervical portion of spinal cord, the spinal part of accessory nerve arises and enters the cranial cavity **through foramen magnum**. The cranial root of accessory nerve arises from the **medulla oblongata**. These two parts join together to form the accessory nerve and leave the cranial cavity through the **Jugular Foramen**.

- The cranial part joins the vagus and is distributed in its branches to the muscles of the soft palate and pharynx (via the pharyngeal plexus) and to the muscles of the larynx (except the cricothyroid muscle) .
- The spinal part supplies **Sternomastoid**. and **Trapezius muscles**.



Accessory nerve injury:

The accessory nerve, as it progresses subcutaneously through the neck, is subject to injury, (e.g., during lymph node biopsy, carotid artery and/or internal jugular vein surgical procedures). Injury produces weakness in the sternocleidomastoid and trapezius muscles, impairing neck movement and resulting in a drooping of the shoulder.

3) **Brachial plexus:** it's found in the lower region of the posterior triangle.

Its nerves supply the **upper limb**

The anterior rami of C5, C6, C7, C8 and T1 communicate together, as follows:

C5+C6 >>> form the **superior trunk**

C7 >>> form the **middle trunk**

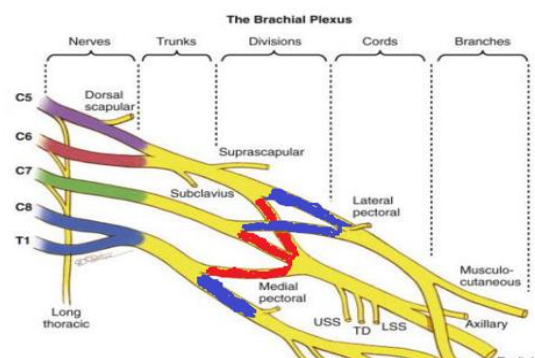
C8+T1 >>> form the **inferior trunk**

Brachial plexus

* Each trunk is divided into anterior and posterior divisions.

- The posterior 3 divisions join together to form the **posterior cord**.
- The upper 2 anterior divisions form the **lateral cord**.
- The lower anterior forms the **medial cord**.

- From these cords arise nerves that supply the upper limb.



In the posterior triangle, we'll see the roots and trunks, and from there, the following nerves arise:

- 1- **Dorsal scapular:** arises from C5 and supplies Levator scapulae
- 2- **Nerve to subclavius:** Clavius muscle (C5 + C6)
- 3- **Suprascapular:** supplies scapula (C5 + C6)
- 4- **Long thoracic:** (5,6,7)

- **Arteries in the posterior triangle:**
- **Transverse cervical + Suprascapular**
 - ** In the lower part of the posterior triangle >> **Subclavian Artery.**

Subclavian Artery: aorta arises from the heart which has three parts:

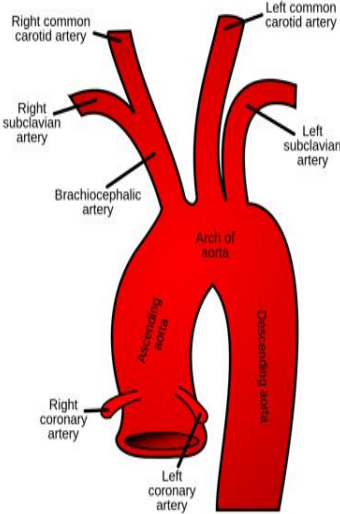
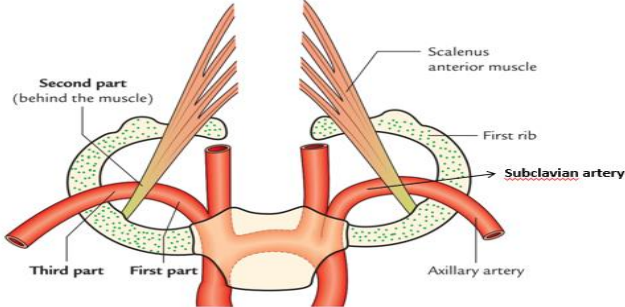
- The first part ascends upwards >> **Ascending aorta** and forms arch called the **Aortic arch.**
- **From the right side** of the aortic arch, there is a trunk called **Brachiocephalic artery** which will divide into two branches:
 - 1- Right subclavian artery
 - 2- Right common carotid artery
- **From the left side:**
 - 1- Left subclavian artery
 - 2- Left common carotid artery

They both arise directly from the aortic arch.

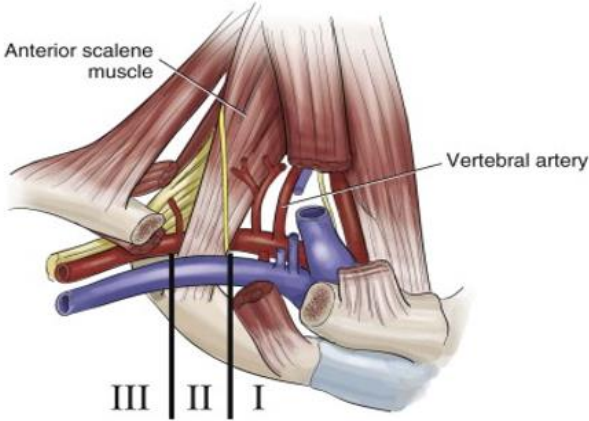
** In the left side, there's no brachiocephalic artery.

- ❖ The subclavian artery loops laterally and crosses the first rib, here it changes its name into **Axillary artery**, which supplies the upper limb.
- ❖ Anterior to the subclavian artery the Subclavian vein, which also changes its name, and it's separated from the artery by the scalenus anterior muscle.

Subclavian Artery



Subclavian Vein



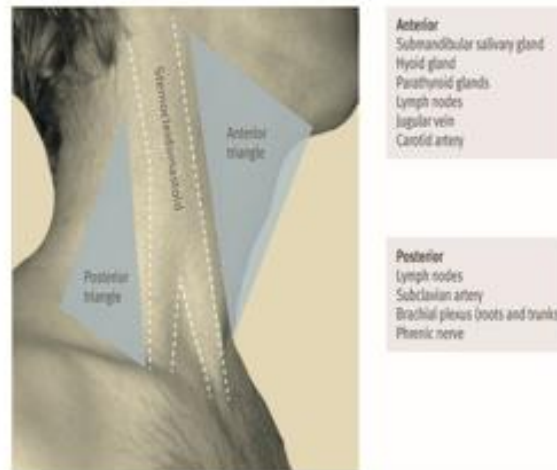
ANTERIOR TRIANGLE

Borders: anteriorly >> midline of the neck

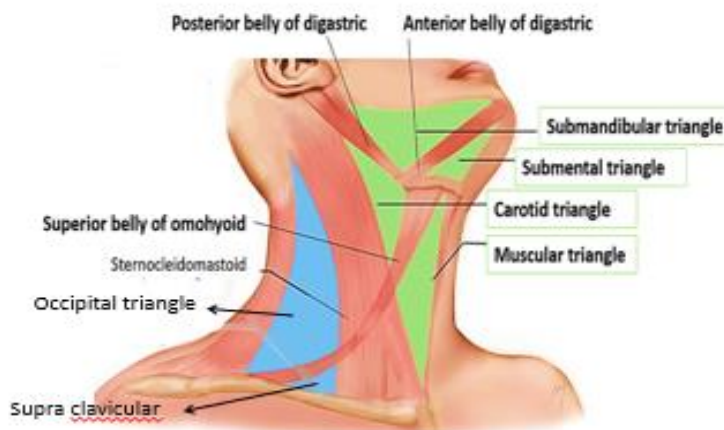
Posteriorly >> anterior border of sternomastoid muscle

Superiorly >> inferior border of the mandible.

It subdivided into many triangles.



SUBMANDIBULAR OR DIGASTRIC TRIANGLE



BORDERS: lower border of the mandible.

Posterior and anterior bellies of digastric and stylohyoid muscle.

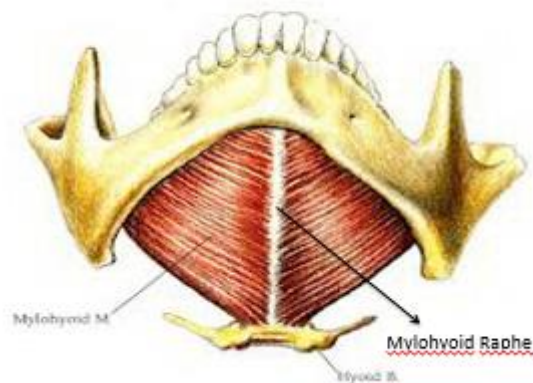
ROOF: skin + superficial fascia + platysma muscle + investing fascia

** All triangles have the same roof.

FLOOR: it's formed by two muscles:

- The mylohyoid muscle anteriorly.
- The hyoglossus muscle posteriorly.
- **Mylohyoid muscle:**

Mylohyoid muscle



In the inner aspect of mandible, there's the mylohyoid line or ridge, from this line, muscle fibers originate and direct medially to form the **mylohyoid raphe**.

Origin > Mylohyoid ridge/line >> pass medially >> inserted into the mylohyoid raphe((median fibrous raphe) and hyoid bone.

Posterior border of the muscle is free.

Action: helps to raise the hyoid bone and tongue in swallowing.

Nerve supply: nerve to the mylohyoid muscle.

Digastric muscle:

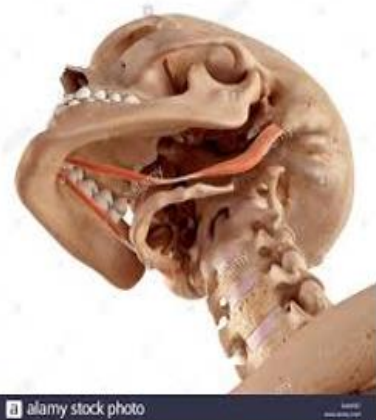Origin: from the digastric notch (deep to the mastoid process), the posterior belly arises and inserts in the hyoid bone to form the intermediate tendon, from this tendon, the anterior belly arises and inserts in the digastric fossae.

Action: Posterior > raise the hyoid bone upward during swallowing.

Anterior > drop the mandible downward.

Nerve supply: post. belly + stylohyoid muscle (posterior auricular N. of the facial N.)

Digastric Muscle



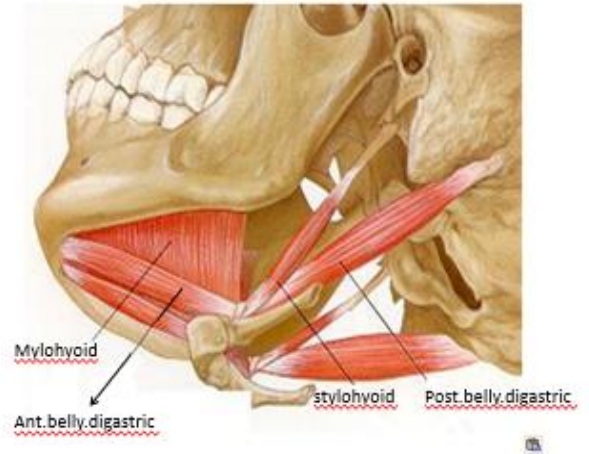
Stylohyoid muscle: (part of the posterior belly) •

Origin and insertion: from styloid process > inserts in the hyoid bone.

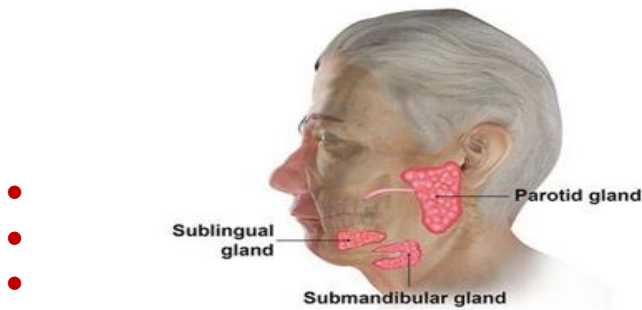
Action: resembles that of the posterior belly of digastric.

Nerve supply: posterior belly + stylohyoid >> facial nerve (posterior auricular branch).

Anterior belly >> nerve to the mylohyoid.



Salivary glands

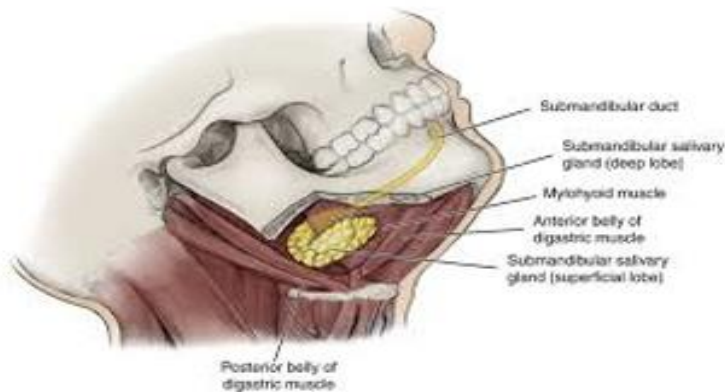


- **CONTENTS:**

Note: the three main salivary glands are Parotid, Submandibular and sublingual salivary glands.

1) Superficial part of the submandibular salivary gland

Note: there's superficial and deep part of the submandibular gland, the deep part cannot be seen with the contents of this triangle.

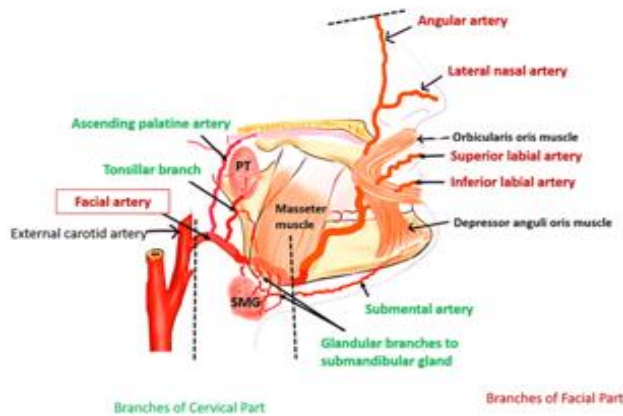


2) **Facial artery:** it's a branch from the external carotid artery.

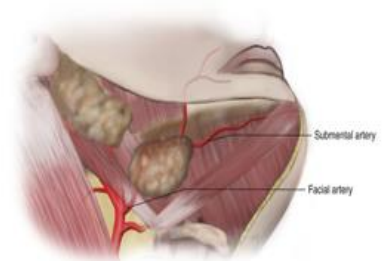Passes deep to the submandibular gland. It gives branches:

- a- Glandular branch
- b- Tonsillar branch
- c- Ascending palatine
- d- Submental branch

Facial artery:



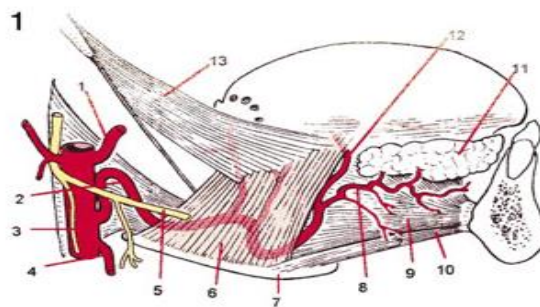
Facial artery



3) **Lingual artery:** a branch from the external carotid artery, it passes deep to the posterior belly of digastric and disappears by passing deep to the hyoglossus.

*Short course and gives no branches.

Lingual artery



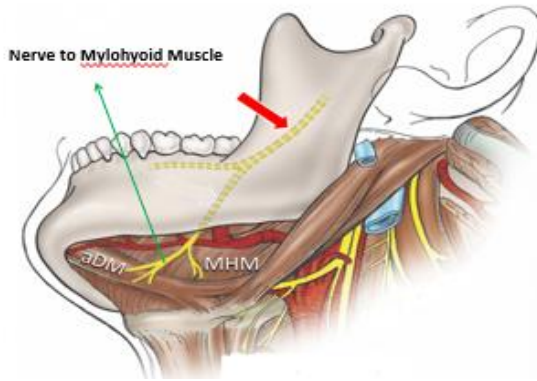
4) **Nerves:**

- a- Nerve to the mylohyoid muscle (**branch from the inferior alveolar nerve**) which passes along the lower border of the mandible and supplies the mylohyoid muscle and anterior belly of digastric.

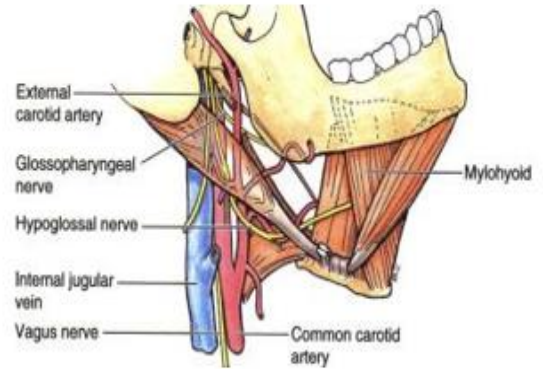
(it can be seen with the submental triangle)

b- Hypoglossal nerve (cranial nerve 12) which supplies the muscles of tongue, it also passes deep to the posterior belly of digastric (short course) and gives no branches.

Nerve to Mylohyoid Muscle:



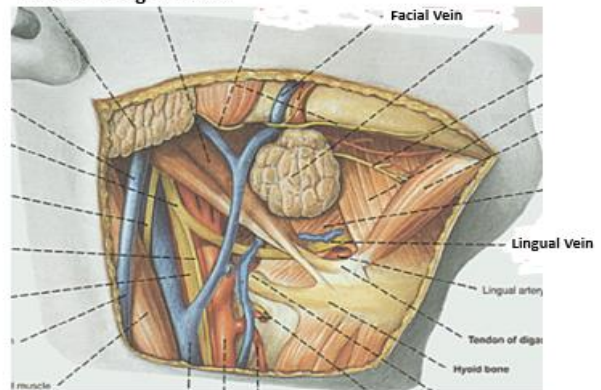
Hypoglossal Nerve



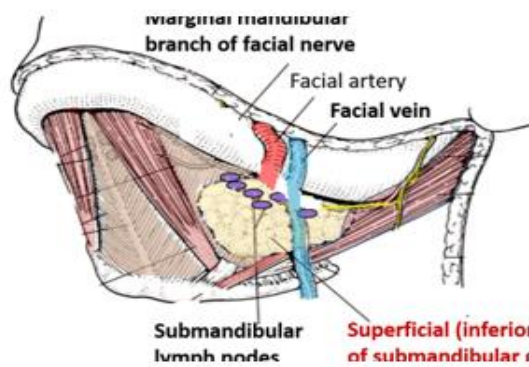
5) **Facial and lingual veins:** superficial (above the gland)

6) **Submandibular lymph nodes:** clusters of lymph nodes located on the submandibular salivary gland (can be seen in tonsillitis).

Facial and lingual veins



Submandibular L.Ns.



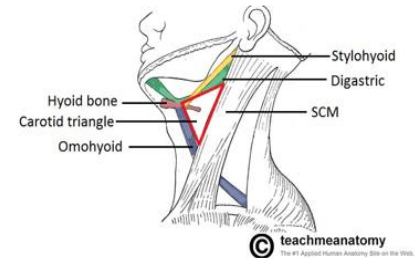
CAROTID TRIANGLE

- **Carotid triangle:** one of the subdivisions of the anterior triangle.

BORDERS:

- Posterior belly of digastric
- Superior belly of omohyoid
- Sternomastoid muscle

Carotid triangle (boundaries)



Its main content is the **carotid sheath**.

Carotid sheath: it's a tube of fascia that extends from the base of the skull to the inlet of the root of the neck and contains **artery**, **vein** and **nerve**:

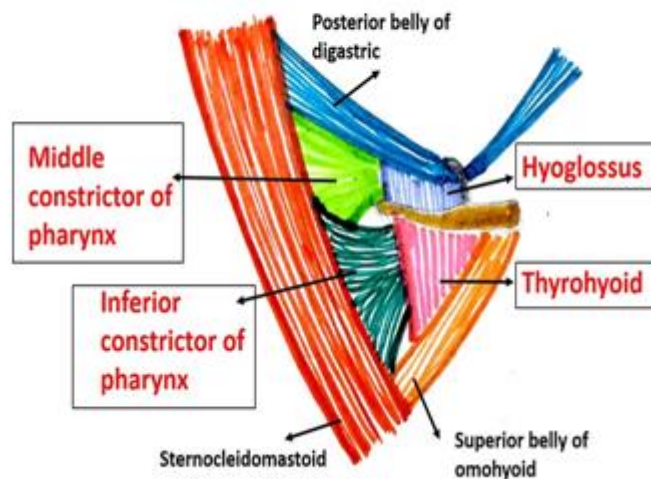
- **The common carotid artery and its branches.**
- **The internal jugular vein.**
- **The vagus nerve (cranial nerveX)**

ROOF: mentioned previously (same as anterior and posterior triangles)

FLOOR:

- Anteriorly > thyrohyoid + hyoglossus muscles
- Posteriorly > middle + inferior constrictor of pharynx

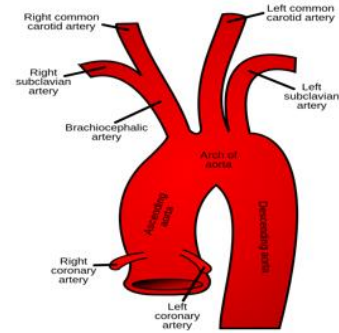
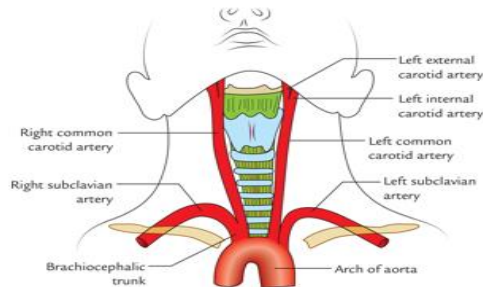
Floor of carotid triangle



CONTENTS:

I. Common carotid artery(C.C.A):

It arises from the aortic arch,



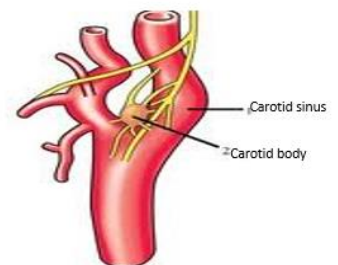
From the right side of aortic arch, the **brachiocephalic artery** arises and divides to the **right subclavian artery** and the **right common carotid artery**. While in the left side, the **left subclavian artery** and the **left common carotid artery** arise **DIRECTLY** from the aortic arch (there is **NO** brachiocephalic artery in the left side).

** The common carotid artery arise at the level of the sternoclavicular joint and ascends upward till the level of the upper border of thyroid cartilage and divides into **internal** and **external** carotid arteries.

At the point of division of the terminal part of C.C.A., the beginning of internal carotid artery shows a localized dilatation called **the carotid sinus**, which contains in its wall numerous nerve fibers derived from the glossopharyngeal nerve.

** The carotid sinus serves as a reflex pressoreceptor (contains baroreceptor): In an increased blood pressure, it causes a slowing of heart rate and makes vasodilation.

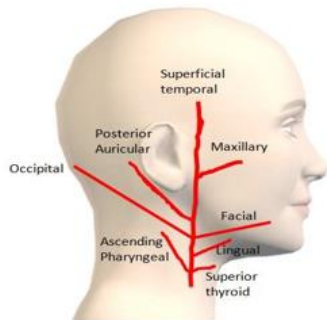
Carotid sinus and body



Carotid sinus syndrome may result in loss of consciousness due to simple head movements. The syndrome relates to the hypersensitivity of the carotid sinus due to an unknown etiology. Sudden slight pressure changes, such as that occasioned by movement of the head, may result in stimulation of the carotid sinus. Impulses relayed by the sinus reduce blood pressure and slow the pumping action of the heart, thus decreasing blood supply to the brain, resulting in sudden loss of consciousness.

** Between the bifurcation of internal and external, there's a brown body called the **carotid body**, it contains chemoreceptors that sense to excess carbon dioxide and reduced oxygen in blood. The stimulation of carotid body makes a rise in blood pressure and heart rate and increases the respiratory movements.

Branches of external carotid artery



❖ Branches of the external carotid artery(E.C.A):

1) **Superior thyroid artery**: it arises from the front of the E.C.A. near its origin, it passes downward vertically to enter the thyroid gland and gives:

a- **Superior laryngeal artery**: which pierces the thyrohyoid membrane with the

internal laryngeal nerve.

b- **Branch to sternomastoid muscle**.

Note: thyrohyoid membrane extends from the upper border of thyroid cartilage to the hyoid bone.

2) **Lingual artery**: arises from the anterior surface of the E.C.A., it supplies the tongue.

- Its origin is from the external carotid artery.
- Enters the digastric or the submandibular triangle.
- Short course with no branches, then it passes deep to the hyoglossus muscle

3) **Facial artery**: arises from the anterior surface of E.C.A.

- Enter the digastric or the submandibular triangle and passes deep to the posterior belly of digastric.
- Gives 4 branches:

a- Glandular b- Tonsillar c- Submental d-Ascending palatine

4) **Occipital artery**: arises from the posterior surface of E.C.A. opposite to the facial artery.

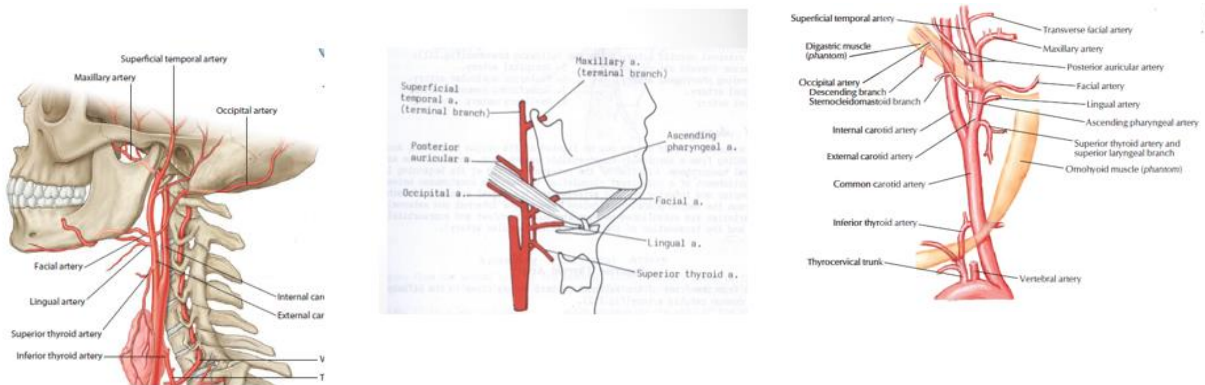
It supplies the occipital region.

5) **Posterior auricular**: arises from the posterior surface of E.C.A., supplies the auricle and mastoid region.

6) **Ascending pharyngeal artery**: arises from the deep surface of E.C.A., it's a long artery that supplies the pharynx.

Then it divided into two terminal branches within the parotid region:

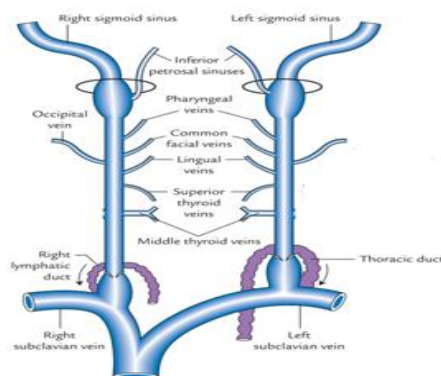
- 7) Superficial temporal artery
- 8) Maxillary artery



II. Internal jugular vein (I.J.V):

- The internal jugular vein is formed by the sigmoid sinus + inferior petrosal sinus (** Veins of the brain are called Sinuses **) at the level of the jugular foramen. It descends vertically within the carotid sheath. It shows 2 dilatations: superior and inferior bulbs.
- It receives the following tributaries:
 - a) Pharyngeal veins
 - b) Facial vein
 - c) Lingual vein
 - d) Occipital vein
 - e) Superior thyroid vein
 - f) Middle thyroid vein
- Thyroid gland has 3 veins (superior, middle and inferior veins)

Internal Jugular Vein



III. Nerves within the carotid triangle

- 1) **Accessory nerve:** (explained previously)
- 2) **Hypoglossal nerve:** it's a motor nerve which supplies the muscles of tongue.
 - It arises from medulla oblongata through the hypoglossal canal.
 - It descends downward vertically at the level of post. belly of digastric M., it passes forward and deep to this muscle to enter the submandibular triangle and disappear.
 - **Hypoglossal nerve, crosses the occipital, internal & external carotid and lingual arteries.**

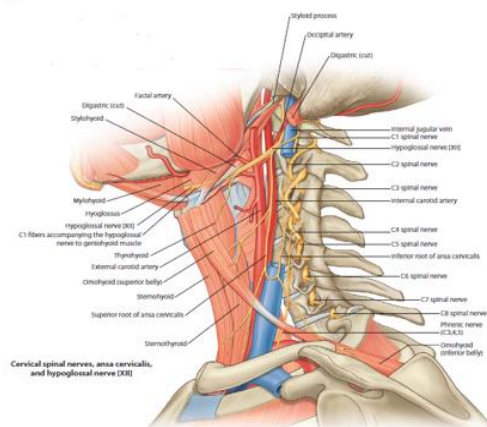
The hypoglossal nerve joins a branch in the upper part of its course, this branch is from **C1** and **C2**:

- a- **Meningeal branch:** the first branch **re-enters** the cranial cavity and supplies the meninges in the posterior cranial fossae.
- b- **Nerves to geniohyoid and thyrohyoid:** to supply these muscles.
- c- **Muscular branches:** to supply the muscles of tongue.
- d- **Superior root of Ansa cervicalis.**

Ansa cervicalis: a loop of nerves found in the cervical plexus within the carotid triangle. The **superior root** of Ansa cervicalis is formed by **C1**, which travels with the hypoglossal nerve, the **inferior root** is formed by **C2** and **C3**.

- **Ansa cervicalis gives branches to the infrahyoid muscles, a group of muscles located inferior to the hyoid bone:**
 - Sternohyoid
 - Sternothyroid
 - Omohyoid
 - Thyrohyoid

Hypoglossal Nerve:



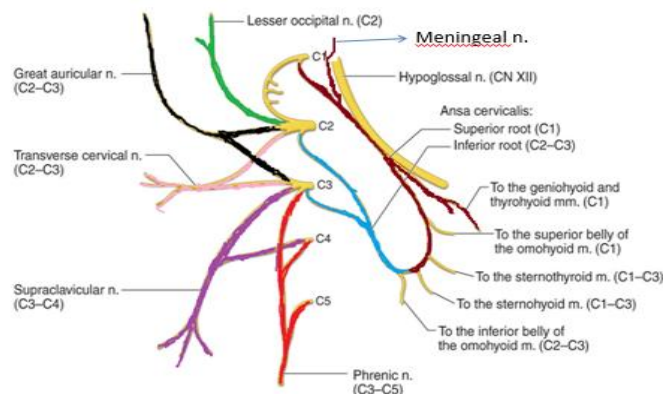
3) **Cervical plexus:** it's formed by the anterior rami of the first four cervical nerves. Located deep to the sternomastoid muscle.

A- **Cutaneous branches:** which are located in the posterior triangle, they are:

- Lesser occipital
- Greater auricular
- Transverse cervical
- Supraclavicular

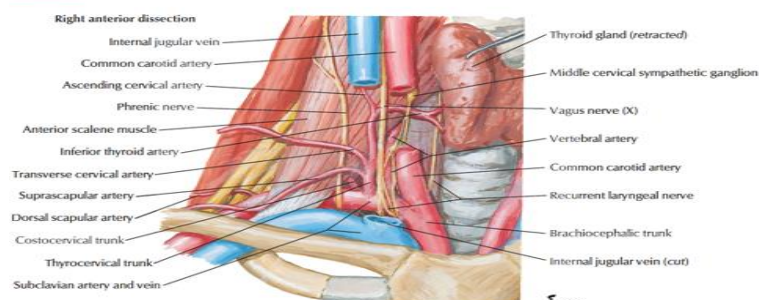
B- **Inferior root of Ansa cervicalis:** which is formed by the branches from C2 + C3 and joins the superior root of Ansa cervicalis from the hypoglossal nerve to form Ansa cervicalis which supplies the infrahyoid muscles.

Cervical Plexus



C- **Phrenic nerve:** a motor nerve to the diaphragm and sensory to its central part, it arises from C3 + C4 + C5 (mainly from C4) and crosses the anterior scalenus muscle from its **lateral border to medial border** and **enters the thorax by passing in front of the subclavian artery.**

Phrenic nerve



The phrenic nerve can be injured by penetrating wounds in the neck. If that occurs, the paralyzed half of the diaphragm relaxes and is pushed up into the thorax by the positive abdominal pressure.

D- **Direct muscular branches.**

4) **Vagus nerve (tenth cranial nerve X):** (motor+sensory+parasympathetic)

- Originates from **medulla oblongata**
- Leaves the skull through **the jugular foramen**
- It possesses two sensory ganglia:

a- **Superior ganglion:** located at the level of jugular foramen.

b- **Inferior ganglion:** located just below the foramen.

The vagus nerve is joined by the cranial root of the accessory nerve (CN XI), at the jugular foramen.

The vagus nerve trunk passes down the neck between the carotid artery and the internal jugular vein, within the carotid sheath. At the base of the neck, the nerve enters the thorax.

❖ **BRANCHES OF THE VAGUS NERVE IN THE NECK**

A) **Meningeal branch:** arises from superior ganglion and supplies the dura mater in the posterior fossa of the skull.

B) **Auricular branch (Arnold's nerve) :** arises from the superior ganglion to supply the auricle, external auditory meatus and tympanic membrane.

Arnold's nerve ear-cough reflex is mechanical stimulation of the external auditory meatus can activate the auricular branch of the vagus nerve (Arnold's nerve)

C) **Pharyngeal branch:** arises from the inferior ganglion to supply the muscles of pharynx (except the *stylopharyngeal* muscle) and the muscles of soft palate (except the *tensor palatine* muscle).

These motor t fibers are supplied by the accessory nerve (cranial part - CN XI) which joins the vagus nerve at the jugular foramen.

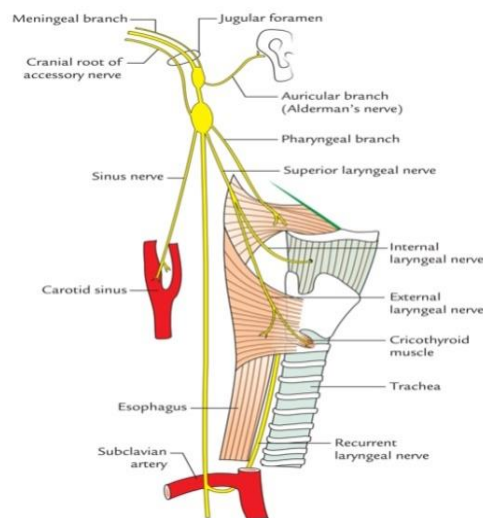
D) **Superior laryngeal nerve:** arises from the inferior ganglion and divides into:

- **Internal laryngeal nerve(sensory):** pierces the thyrohyoid membrane with the **superior laryngeal artery**, it's a sensory nerve that supplies the mucous membrane of larynx above the true vocal folds.
- **External laryngeal nerve (motor):** supplies the cricothyroid muscle.

E) **Cardiac branches:** two or three parasympathetic branches that join the cardiac branches of sympathetic trunk.

F) Recurrent laryngeal nerve:

- ✱ **The right recurrent laryngeal nerve** arises from the vagus as it crosses the 1st part of the subclavian artery, courses upwards in the tracheoesophageal groove (between trachea and esophagus) to supply:
 - **all muscles of larynx except cricothyroid** which is supplied by laryngeal nerve.
 - The mucous membrane of the larynx below the vocal folds.
- ✱ *The left vagus nerve gives the left recurrent laryngeal nerve after crossing the aortic arch, courses upwards in the tracheoesophageal groove (between trachea and esophagus) .*



5) Sympathetic trunk (cervical portion):

In the cervical region of the sympathetic trunk, there are three major ganglia:

- a- **The superior cervical ganglion:** it's long and extended from vertebral level C1 to C2 or C3.

Its post ganglionic branches are:

- Gray rami communicants to spinal nerves C1 to C4.
- Cardiac branches to the heart.
- Glandular branches to the thyroid gland.
- Carotid branches that follow the external and internal carotid arteries as perivascular nerve plexus.

b- The middle cervical ganglion: it's found in at vertebral level C6. Its post ganglionic branches are:

- Gray rami communicants to spinal nerves C5 and C6.
- Cardiac branches to the heart.
- Glandular branches to the thyroid gland.
- Ansa subclavian which loops around the subclavian artery to the cervicothoracic (inferior cervical) ganglion, it supplies the subclavian artery .

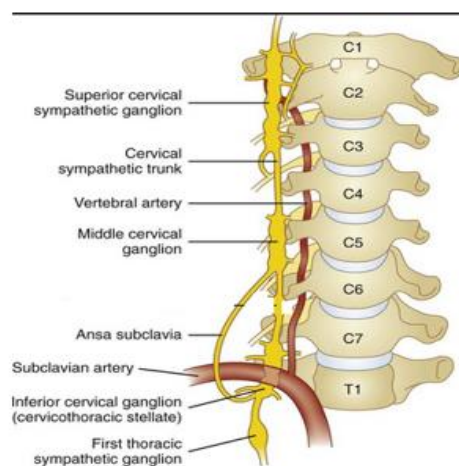
c- Inferior cervical ganglion: it's found just above the subclavian artery. Its post ganglionic branches are:

- Gray rami communicants to spinal nerves C7 and C8.
- Cardiac branches to the heart.

The inferior cervical ganglion is usually fused with the ganglion of T1 to form stellate or cervicothoracic ganglion.

Note: all the sympathetic nerves that supply the head and neck are from the superior cervical ganglion through the perivascular plexus which surrounds the common carotid artery and its branches.

Cervical portion of the sympathetic trunk



Horner's syndrome, also known as oculosympathetic paresis, is a combination of symptoms that arises when the sympathetic trunk is damaged. The signs and symptoms occur on the same side (ipsilateral) as it is a lesion of the sympathetic trunk. It is characterized by miosis (constricted pupil), partial ptosis (a weak, droopy eyelid), apparent anhidrosis (decreased sweating), with apparent enophthalmos (inset eyeball)

MUSCULAR TRIANGLE

✿ BOUNDARIES:

- Midline
- Sternocleidomastoid muscle
- Superior belly of omohyoid muscle

✿ Muscles: they are called **infrahyoid muscles** (**Strap Muscles**).

1- Omohyoid muscle: contains the inferior belly which arises from the scapular and forms the intermediate tendon deep to the sternomastoid muscle, from this tendon, the superior belly arises and attaches to hyoid bone.

Action: depress the larynx and hyoid bone .

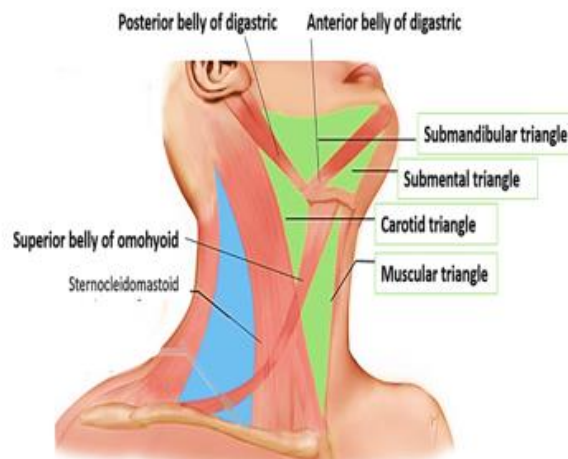
2- Sternohyoid muscle: arises from the posterior aspect of head of sternum and medial end of clavicle, inserts in the hyoid bone.

Action: depress the larynx and hyoid bone

3- Sternothyroid muscle: originates from the 1st rib cartilage (costal), and inserts in the oblique line of thyroid gland cartilage.

Action: depress the larynx and hyoid bone.

Muscular triangle:

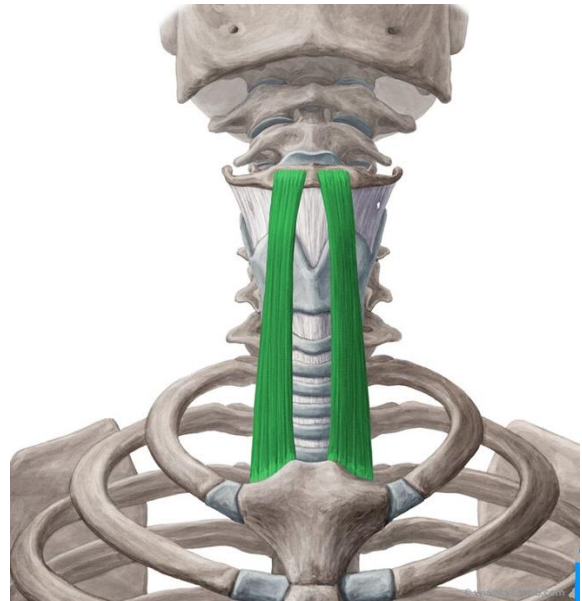
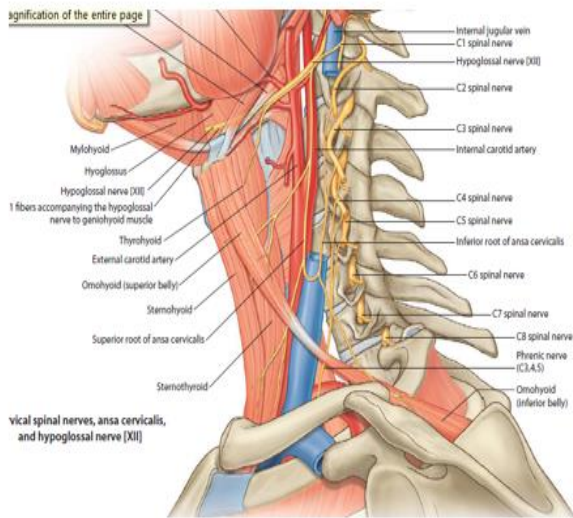


4- Thyrohyoid muscle: originates from the oblique line of thyroid gland cartilage, and inserts in the hyoid bone.

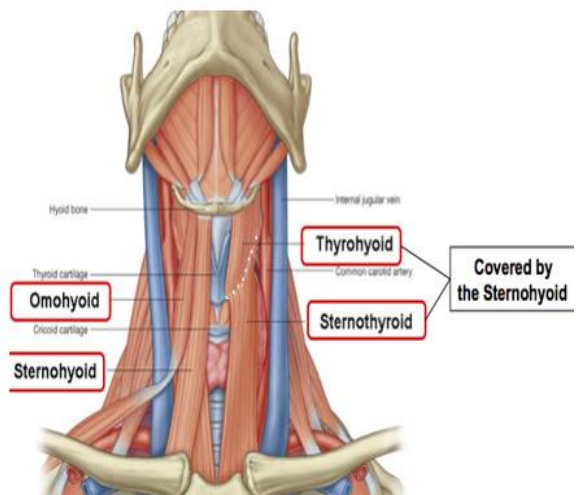
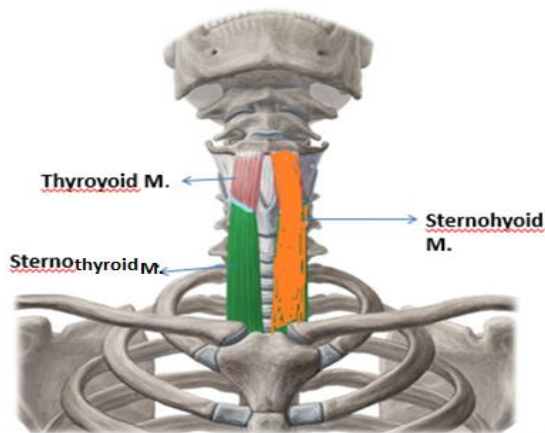
Action: depress or elevate the larynx.

Nerve supply: from **Ansa cervicalis** (*except the thyrohyoid muscle from the hypoglossal nerve*).

Omohyoid muscle



Sternothyroid and Thyrohyoid muscles

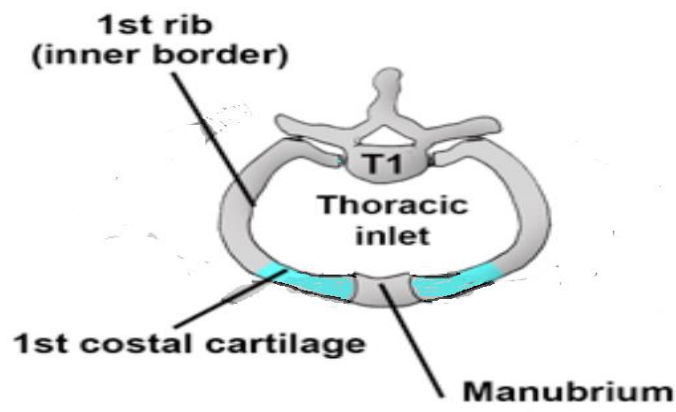


ROOT OF THE NECK

It is the region that connects the head above with the chest below (inlet of the chest). Through it pass a number of important structures to or from the neck to the thorax.

Boundaries:

- **Anteriorly:** head of the sternum.
- **Laterally:** first rib
- **Posteriorly:** vertebra T1



Contents:

❖ The subclavian artery:

- The right arises from the brachiocephalic artery.
- The left arises directly from the aorta.

The subclavian artery passes through the root of the neck and when crossing the 1st rib, it changes its name to the **axillary artery**, which is the main blood supply of the upper limb.

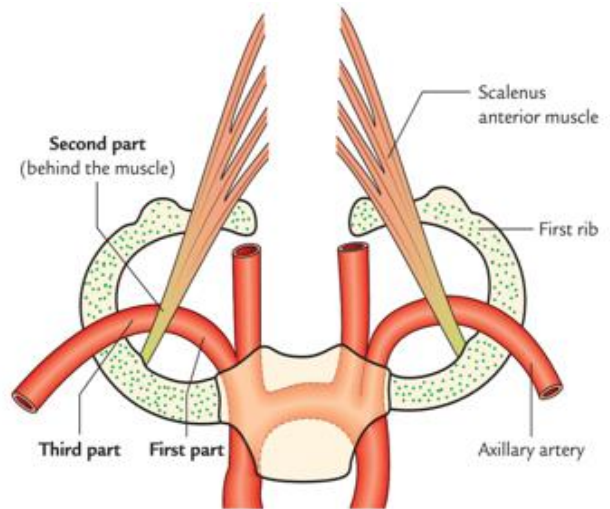
The subclavian artery in the root of the neck divides into **three parts** by the **anterior scalenus muscle**:

- The first part is medial to the muscle.
- The second is posterior to it.
- The third is lateral to it.

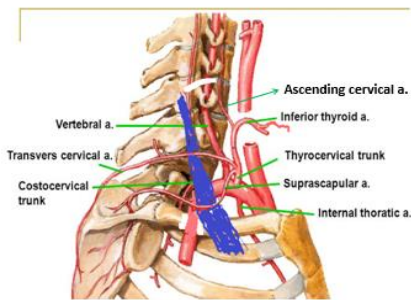
1- The first part:

It gives the following branches:

- a) **Vertebral artery:** it's the first branch, arises from the upper aspect of the subclavian artery, it ascends upward to the transverse foramen of C6, then it ascends through successive transverse foramina to reach the foramen magnum. It enters the skull and joins its opposite to form the **basilar artery** which supplies the brain.

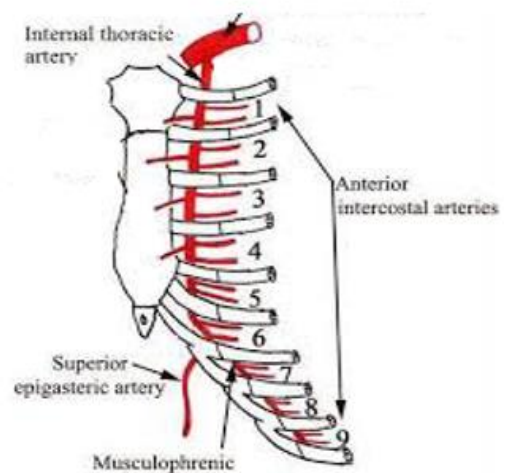


1st Part: Vertebral Artery



- b) **Internal thoracic artery:** arises from the lower surface, descends downward parallel to the sternum which gives anterior intercostal arteries.

Internal thoracic artery



- c) **Thyrocervical trunk:** it gives three arteries:
1. **Suprascapular**
 2. **Transverse cervical** divides into:

a. Deep, supplies the muscle in scapular region.

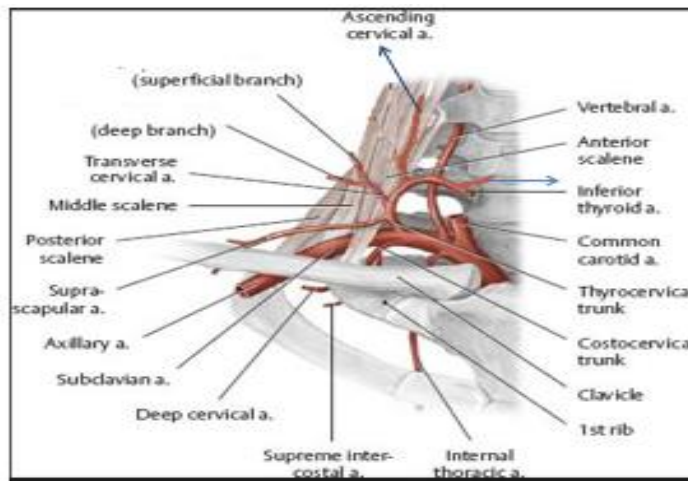
b. Superficial which supplies trapezius muscle

Note: the structure that crosses the muscle transversely is the phrenic nerve (beside suprascapular & transverse cervical arteries).

3. Inferior thyroid artery: gives:

a. Inferior laryngeal artery, supplies the larynx.

b. Ascending cervical artery(muscular branch).

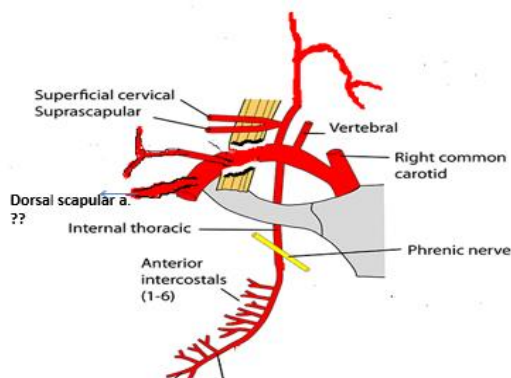


2- **The second part:** arises from the post surface of the artery, it gives a trunk called costocervical trunk, which passes laterally to the neck of the 1st rib, and in divides into two arteries:

a- **Deep cervical artery:** passes into the muscles of the back of the neck.

b- **Highest intercostal artery:** it gives 1st and 2nd posterior intercostal arteries, supplies the 1st and 2nd intercostal spaces .

3- **The third part:** it gives no branches, except it may give descending or dorsal scapular.



✱ It gives the branch only when the transverse cervical artery doesn't divide.

❖ **The subclavian vein:**

It's the axillary vein after crossing the 1st rib, it's called subclavian, located anterior to the scalenus muscle and

there are two tributaries empty into it:

External jugular vein. -

Vertebral vein. -

❖ **Thoracic duct:** it's a large lymphatic vessel, ascends on the left side of esophagus, then it makes a loop medially and empties in the junction between the left internal jugular and the left subclavian veins.

❖ **Trachea.**

The trachea, or windpipe, is a 10-11 cm long fibrocartilaginous tube of the lower respiratory tract. The trachea extends between the larynx and thorax, consisting of two parts; cervical and thoracic.

The cervical part of trachea, which is located inside the anterior visceral (pretracheal) compartment of the neck. It begins at the inferior border of the larynx (cricoid cartilage) located at the level of vertebra C6. It descends anterior to esophagus and ends at the level of the jugular notch of sternum.

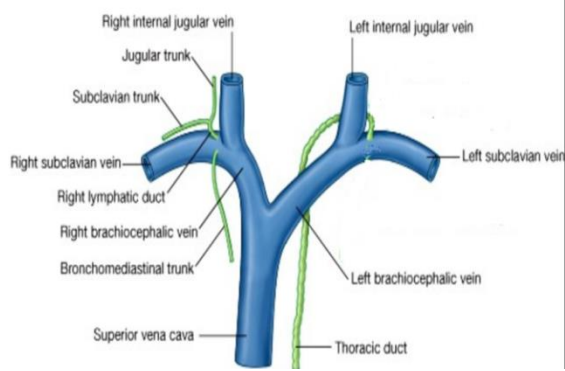
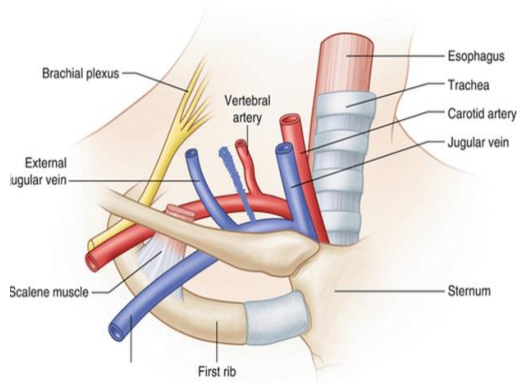
❖ **Esophagus.**

The esophagus (oesophagus) is a 25 cm long fibromuscular tube extending from the pharynx (C6 level) to the stomach (T11 level).

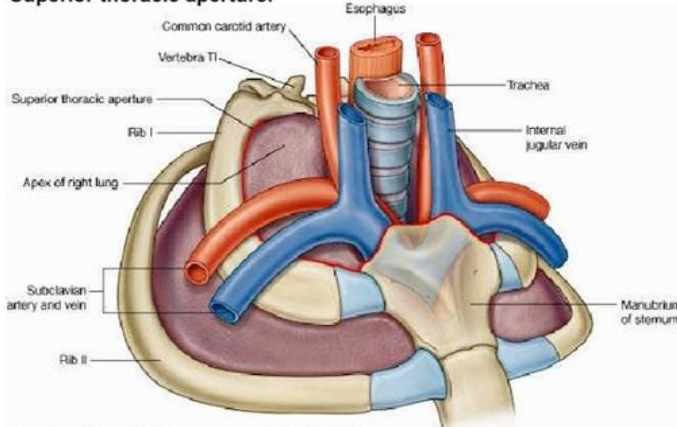
The esophagus is divided into three parts:

- 1- Cervical which travels through the neck
- 2- Thoracic which is located in the thorax.
- 3- Abdominal which travels past the diaphragm into the abdomen, reaching the stomach.

The trachea and esophagus travel closely together through the neck, with the vertebral column situated posterior to the esophagus.



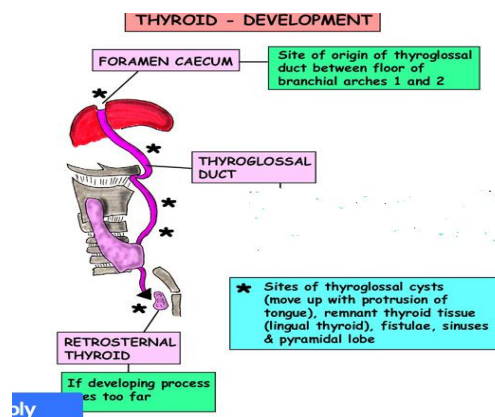
Superior thoracic aperture.



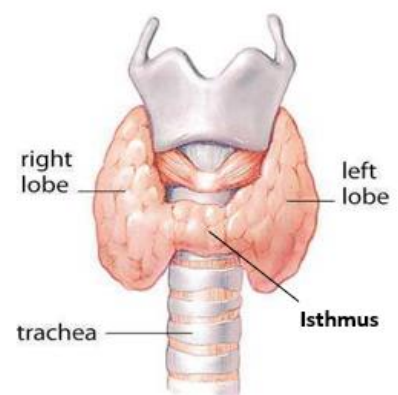
THYROID GLAND

The thyroid gland is an endocrine organ located in the neck. It secretes thyroid hormones that regulate body metabolism (thyroxin) and calcium homeostasis(calcitonin).

It develops as invagination of oropharyngeal epithelium(in adult represented by **foramen cecum**) and migrates downward along the anterior aspect of the neck as a cord called thyroglossal duct.it then developed anterior to trachea as the thyroid gland.



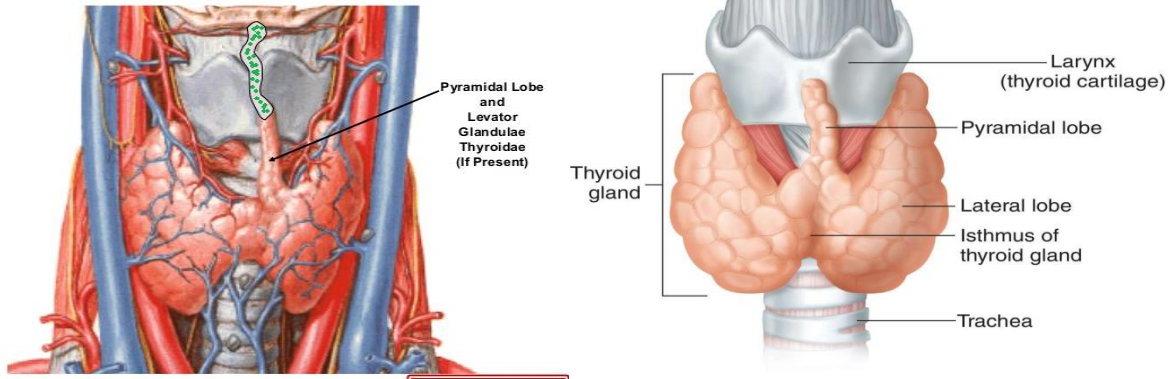
Thyroid gland:



It consists of two lobes (H shaped), each lobe is pyramidal in shape, these two lobes are located on either side of lower larynx and upper trachea, connected by a medial part called **isthmus** (overlies from the 2nd to 4th tracheal cartilage).

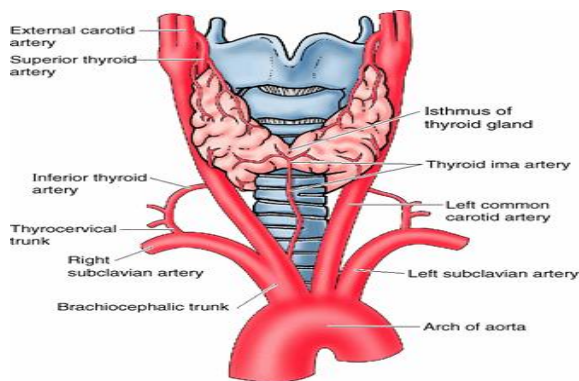
In some individuals, there may be a third lobe of the thyroid gland known as the pyramidal lobe.

From the pyramidal lobe or isthmus, a band of fibers to the hyoid bone called **Levator glandulae thyroideae** which represents the remnant of the thyroglossal duct.

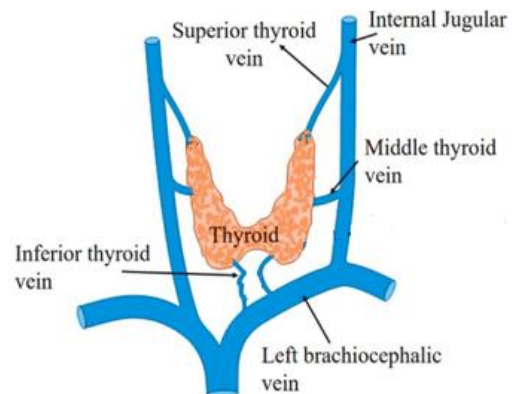


Blood supply:

- 1- Superior thyroid artery (from external carotid artery).
- 2- Inferior thyroid artery (from subclavian artery)
- 3- Thyroidea ima (in 10 % of people) arise from the brachiocephalic artery or aortic arch to the trachea and enters the isthmus.



Veins of Thyroid gland



Veins:

- 1- Superior
- 2- Middle
- ⊙ They both empty in the internal jugular vein
- 3- Inferior, empties in the left brachiocephalic vein.

Nerve supply:

Principal innervation of the thyroid gland derives from the autonomic nervous system. Parasympathetic fibers come from the vagus nerves, and sympathetic fibers are distributed from the superior, middle, and inferior ganglia of the sympathetic trunk.

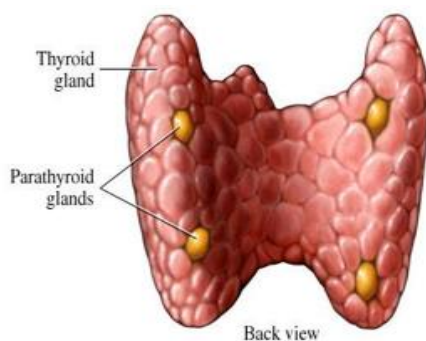
Lymphatic drainage:

Lymphatic drainage of the thyroid gland involves the lower deep cervical, prelaryngeal, pretracheal, and paratracheal nodes.

Parathyroid gland:

small rounded lobes on the posterior surface of thyroid gland, it's brown to yellowish in color, secretes **parathormone** which regulates calcium and phosphorus metabolism.

The parathyroid glands are supplied by the inferior thyroid artery.



- ⊙ Increased parathormone increases the level of Ca in blood and results in osteoporosis and deposited Ca in kidneys.
- ⊙ Decreased parathormone decreases the level of Ca which causes the muscle spasm (tetany).

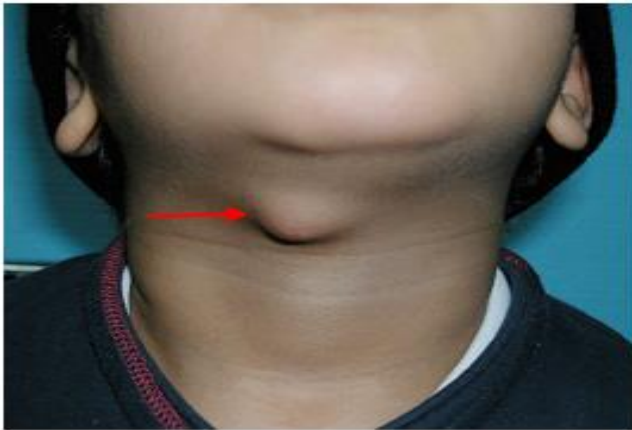Thyroid Arteries and Important Nerves:

- ⊙ It should be remembered that the two main arteries supplying the thyroid gland are closely related to important nerves that can be damaged during thyroidectomy operations (removal of thyroid gland).
- ⊙ The superior thyroid artery on each side is related to the external laryngeal nerve, which supplies the cricothyroid muscle.

- ⊙ The terminal branches of the inferior thyroid artery on each side are related to the recurrent laryngeal nerve.
- ⊙ Damage to the external laryngeal nerve results in an inability to tense the vocal folds and it cause Hoarseness.
- ⊙ Bilateral sectioning of the recurrent laryngeal nerve occasionally may result in dyspnea and, unless surgical intervention ensues, even in death.
- ⊙

- Thyroglossal Cyst:

- Cysts may occur at any point along the thyroglossal duct.
- They occur most commonly in the region below the hyoid bone.



- Thyroglossal Sinus (Fistula):

- Occasionally, a thyroglossal cyst ruptures, producing a sinus.
- Decrease secretion of thyroxin leads to cretinism characterized by physical and mental retardation.
- Increase secretion of thyroxin (hyperthyroidism) which is characterized by increase metabolic activity, enlargement of the gland (goitre) and protrusion of eyeball (exophthalmic goitre)
- Enlargement of thyroid gland (goitre) may cause:
 - Strider (high respiratory sound; wheezing).
 - Dyspnea (difficulty in breathing).
 - Dysphagia (difficulty in swallowing).

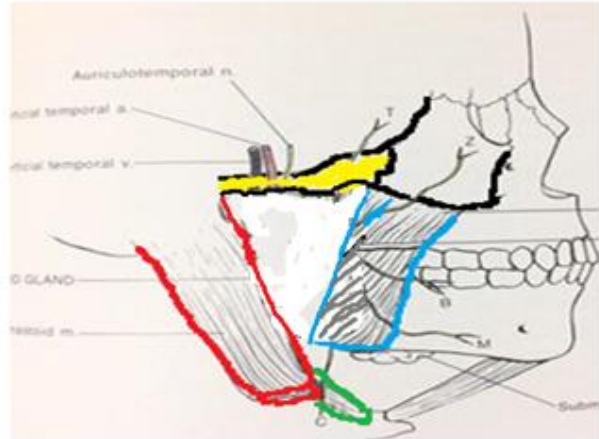
PAROTID REGION

- It's triangle in shape and mostly occupied by parotid gland

Boundaries:

- Anteriorly > ramus of the mandible and masseter muscle.
- Posteriorly > mastoid process and sternocleidomastoid muscle.
- Superiorly > zygomatic arch.
- Inferiorly > posterior belly of digastric with stylohyoid muscle.
- Medially > styloid process and muscles with ligaments attached to it.
- Laterally > skin.

Parotid Region : Boundaries



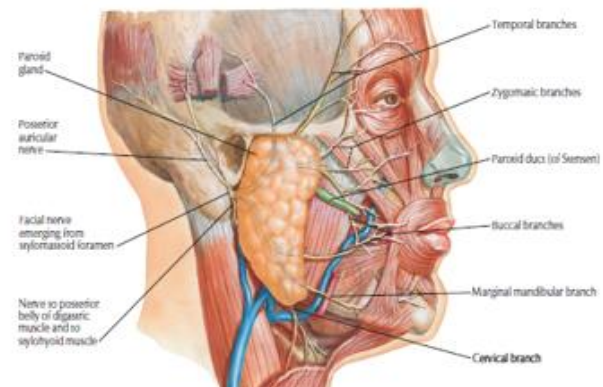
Contents:

1) Parotid gland :

Each individual has a pair of parotid glands that are situated in the preauricular area (flattened region anterior to the tragus) on each side of the face. It is the largest of the three major salivary glands (the others being the submandibular and sublingual glands), and weigh around 15 – 30 grams each. Each gland is irregular, consisting of a superficial and a deep lobe, and is tan-yellow in appearance. Its general outline is that of an inverted pyramid, the base is the most superior part of the gland, while the blunted apex points inferiorly. It also has anteromedial, posteromedial, and superficial surfaces.

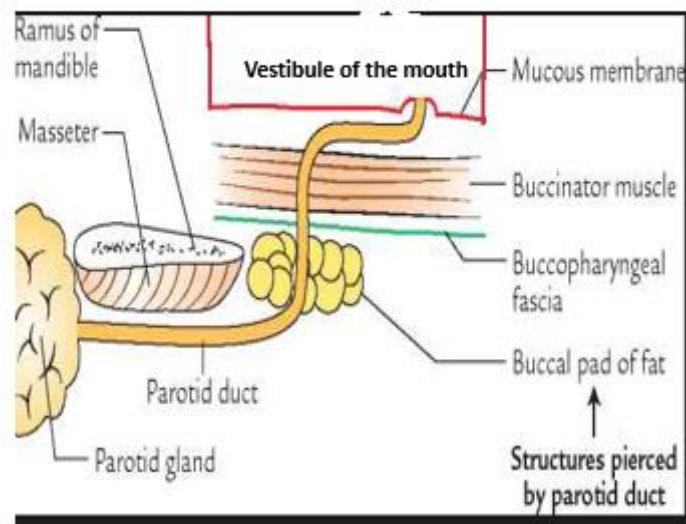
It secretes serous fluid and is surrounded by thick capsule or fascia (investing cervical fascia). It's wedge in shape and yellowish in color.

Occasionally, there is an isolated accessory parotid gland



- ✱ The stylomandibular ligament runs between the styloid process to the angle of the mandible.
 - ✱ From the anterior surface of the gland, the duct extends and passes above the masseter muscle and to the buccinator muscle, in which it pierces it. (there's buccal pad or fat in the buccinator muscle)
 - ✱ The parotid duct(Stensen duct) is roughly 7 cm x 3 mm long and leaves the upper part of the anteromedial surface of the gland. It passes horizontally over the surface of the masseter muscle. The duct then makes an abrupt right turn to cross the buccinator muscle and associated buccal fat pad.
- ✱ **Parotid duct: masseter M. → buccal pad → buccinator M. → vestibule.**
(opens in the vestibule through a papilla opposite to the crown of 2nd maxillary molar)

How does the parotid duct opened into the vestibule??



2) Branches of facial nerve: (5 branches)

- a- Temporal.
- b- Zygomatic.
- c- Buccal.
- d- Marginal mandibular.
- e- Cervical.

3) Terminal branches of external carotid artery:

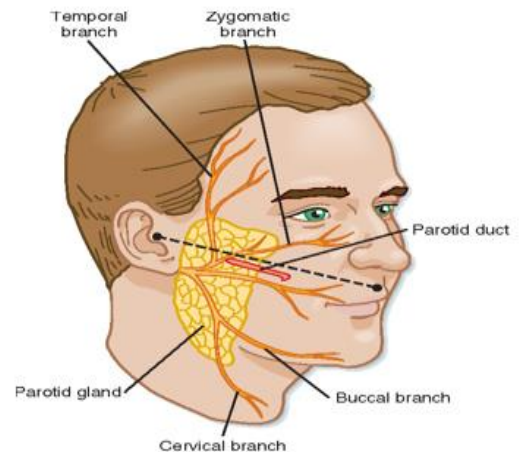
a- Maxillary artery.

b- Superficial temporal artery.

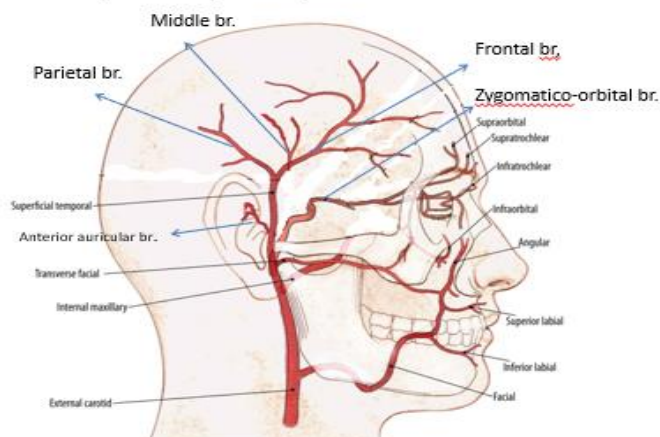
- **The superficial temporal artery:** it's located anterior to the auricle and extended to the temporal region; it gives the following branches:

- 1- **Transverse facial:** arises within the parotid gland and supplies glandular branches to the parotid gland, the duct and the masseter muscle.
- 2- **Articular branches:** supply posterior portion of the temporomandibular joint (TMJ).
- 3- **Anterior auricular branches:** supply external auditory meatus and the anterior portion of the auricle.
- 4- **Zygomatico-orbital branches:** located above the zygomatic arch, supply the skin of the lateral angle of the eye and orbicularis oculi muscle.
- 5- **The frontal branch:** follows a tortuous course.
- 6- **The temporal branch:** supplies portion of the temporalis muscle.
- 7- **The parietal branch.**

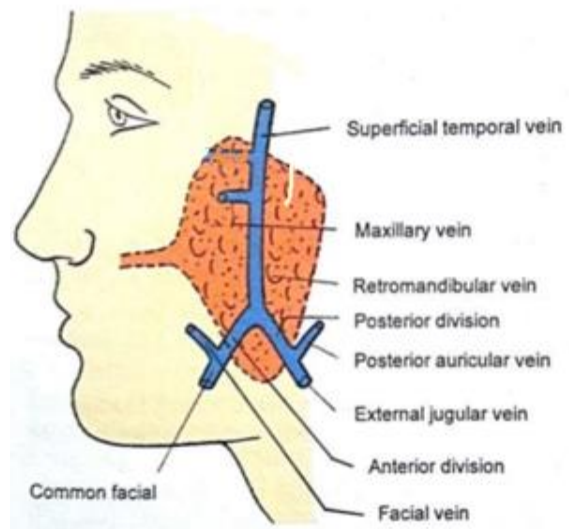
Branches of the Facial Nerve



Branches of the superficial temporal artery



- 4) **Retromandibular vein:** it is formed by **maxillary vein** + **superficial temporal vein** in the parotid gland, then it descends downwards to the angle of the mandible to divide into:
- a- Posterior division (unites with posterior auricular to form the external jugular vein).
 - b- Anterior division (unites with the facial vein to give the common facial vein)



5) **Auriculotemporal nerve:** it's a sensory nerve.

6) **Greater auricular nerve.**

7) **Parotid lymph nodes.**

➤ **Blood supply:**

➤ the parotid gland receives glandular branches from external carotid through the maxillary and superficial temporal arteries.

➤ **Venous drainage**

➤ The maxillary and superficial temporal veins, which unite to form the retromandibular vein.

Innervation:

The gland is under parasympathetic regulation. It receives these fibers via the lesser petrosal nerve, which is a branch of the glossopharyngeal nerve (CN IX) and synapses on the otic ganglion. The postganglionic secretomotor fibers that emerge from the otic ganglion reach the parotid gland via the auriculotemporal nerve (a branch of the mandibular division of the trigeminal nerve).

The sympathetic supply is derived from the adjacent sympathetic plexus of the carotid sheath.

The auriculotemporal nerve is also responsible for carrying general (sensory) stimuli from the gland.

Lymphatic drainage

There are numerous lymph nodes (parotid lymph nodes) distributed throughout and around the substance of the parotid gland and empty into deep cervical lymph nodes.

- Sialography of parotid duct: occasionally, calculus accumulations occur in the parotid duct, thereby obstructing salivary flow. Radiologic examination on injecting radiopaque dye into the parotid duct opening (sialography) identifies the blocked region, and the obstruction may have to be relieved surgically.

The parotid duct, which is a comparatively superficial structure on the face, may be damaged in injuries to the face or may be inadvertently cut during surgical operations on the face.

In relation to surface feature, it is represented by the middle third of the line drawn from the tragus of the ear to the mid point of vertical line extending from the ala of the nose to the red margin of the upper lip

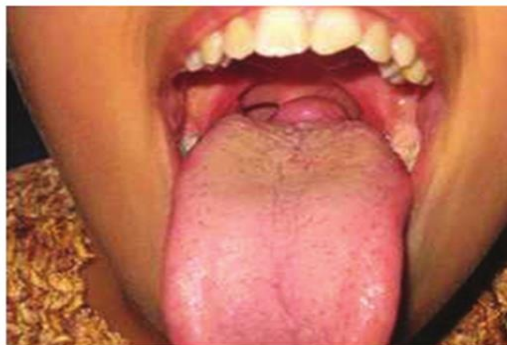- Mumps, a viral infection of the parotid gland (parotitis) that causes acute inflammation and profuse swelling of the gland, impinges on the auriculotemporal and great auricular nerves, causing much pain as the gland is pressured during mastication. Occasionally, it causes orchitis, pancreatitis, and encephalitis. Fortunately, this condition has been mostly eradicated as a result of vaccination .
- Infections of the parotid gland may be confused with toothache as a result of trigeminal nerve involvement. An inflamed parotid papilla (the orifice of the parotid duct in the oral cavity) may be an indication that the problem may be caused by the parotid gland rather than by a tooth. Diseases of the parotid gland cause pain to be referred to the ear, the TMJ, and the external auditory meatus. This is due to the overlapping of sensory branches of various nerves serving the regions of the parotid bed, ear, and TM.

- Tumors of the parotid gland may be excised, but extreme care must be exercised during surgery because any damage to the facial nerve will result in at least partial facial paralysis. Total destruction of the facial nerve results in complete facial paralysis (Bell palsy).
- Frey's Syndrome : is an interesting complication that sometimes develops after penetrating wounds of the parotid gland. When the patient eats, beads of perspiration appear on the skin covering the parotid. This condition is caused by damage to the auriculotemporal and great auricular nerves. During the process of healing, the parasympathetic secretomotor fibers in the auriculotemporal nerve grow out and join the distal end of the great auricular nerve. Eventually, these fibers reach the sweat glands in the facial skin. By this means, a stimulus intended for saliva production produces sweat secretion instead.

Lingual thyroid gland

Ectopic thyroid glands at the base of the tongue have been classified as lingual thyroid glands. This is occurred when a part of or all of the thyroid gland fails to descend. Patients may experience obstructive symptoms (i.e. difficult swallowing, problems with phonation, and difficult breathing).

Some patients are fortunate to remain asymptomatic .



TEMPORAL FOSSA

The temporal fossa is a depression on the temporal region (lateral surface of the skull).

The temporal bone, the sphenoid bone, the parietal bone and the frontal bone contribute to form its concave floor

It is superior to the infratemporal fossa which lies beneath the zygomatic arch

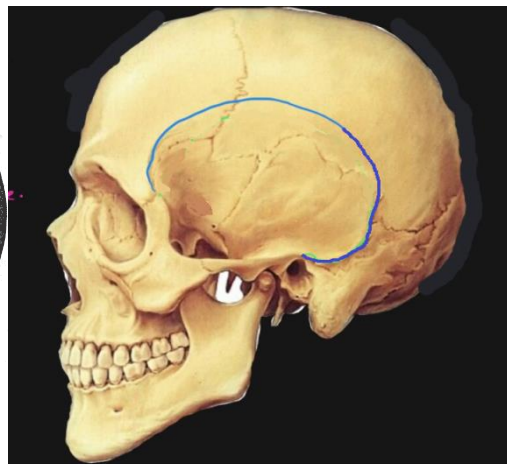
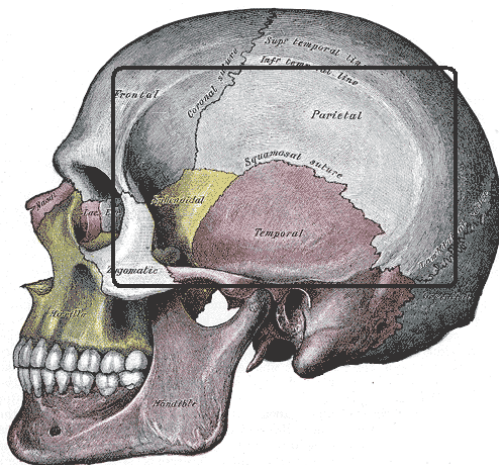
It contains and provides bony attachment for temporalis muscle

Borders:

Both superiorly and posteriorly the temporal fossa is bordered by the superior temporal line

The inferior border runs along the zygomatic arch

The anterior border is marked by the frontal process of the zygoma and the zygomatic process of the frontal bone.



INFRA TEMPORAL FOSSA

It is irregular space located deep to the ramus of mandible

Boundaries:

Superiorly: the infratemporal crest (inferior region of the greater wing of .
.(sphenoid bone

.Medially: lateral surface of the lateral pterygoid plate

.Laterally: the medial surface of the ramus of mandible

.Anteriorly: the posterior surface of the maxilla

.Posteriorly: styloid processes and the stylomandibular ligament

Inferiorly: Imaginary line extend from the maxillary alveolar process and directed posteriorly

Main features :

1-Infraorbital fissure: It is located in the upper part of the infraorbital surface

It is a horizontal cleft between the infratemporal fossa and the floor of the . orbit

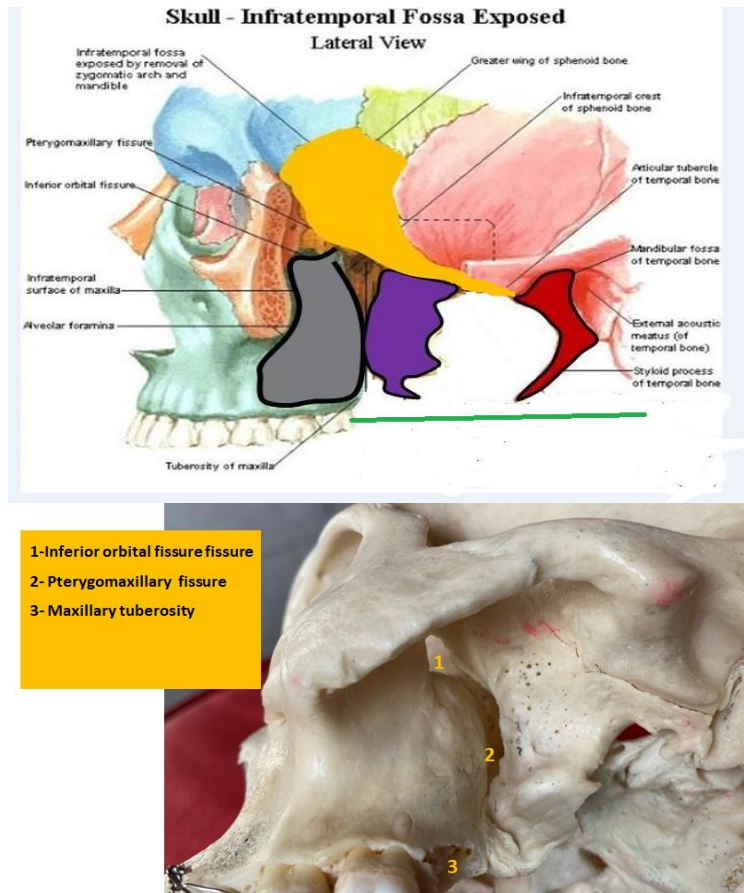
2- Pterygomaxillary (pterygoplatine) fissure:

It is a cleft located between the lateral pterygoid plate and the maxilla and leads from the infratemporal fossa to the pterygoplatine fossa.

3- The foramen ovale and foramen spinosum located at its roof and they communicate the fossa with the middle cranial fossa

4- Posterior superior alveolar foramina: group of foramina located on the posterior surface of maxilla.

5- maxillary tuberosity: a rounded elevation distal to the last maxillary molar tooth.



MUSCLES OF MASTICATION

The muscles of mastication are a group of muscles that consist of the temporalis, masseter, medial pterygoid and lateral pterygoid muscles. The temporalis muscle is situated in the temporal fossa, the masseter muscle in the cheek area, while the medial and lateral pterygoids lie in the infratemporal fossa.

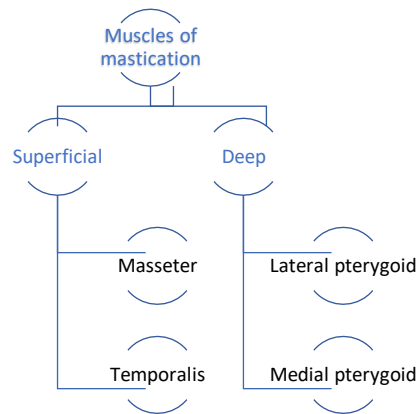
The masticatory muscles attach to the mandible, and thus produce movements of the lower jaw at the temporomandibular joint (TMJ) to enable functions such as chewing and grinding.

These movements include:

Protrusion (protraction), which moves the mandible forwards

Retraction, which pulls the mandible backwards

Elevation, which elevates the mandible and closes the mouth
 Depression, which depresses the mandible and opens the mouth
 Rotation, which produces side-to-side movements of the mandible.

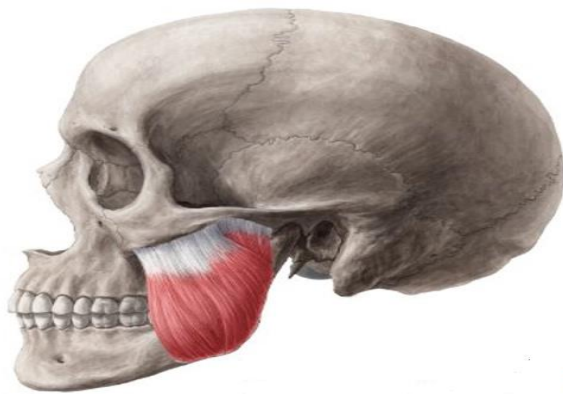


1- **Masseter muscle**: it's quadrant in shape, contains two types of fibers:

- The 1st originates from the lower part of the zygomatic arch, called **superficial fibers** (horizontal fibers).
- The 2nd originates from the inner surface of the zygomatic arch, called **deep fibers** (vertical).

Then the two types of fibers insert in the lateral surface of the ramus of mandible.

The function of the masseter muscle is to elevate and protrude the mandible.

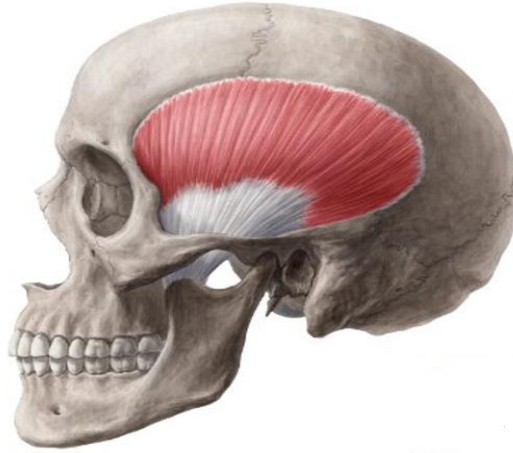

2- **Temporalis muscle**: it has a fan shape, originates from the temporal fossa , temporal lines and the temporalis fascia, it also has two types of fibers:

- Anterior fibers (vertical)
- Posterior fibers (horizontal)

They pass deep to the zygomatic arch and then insert in the coronoid process and the anterior border of the ramus of mandible.

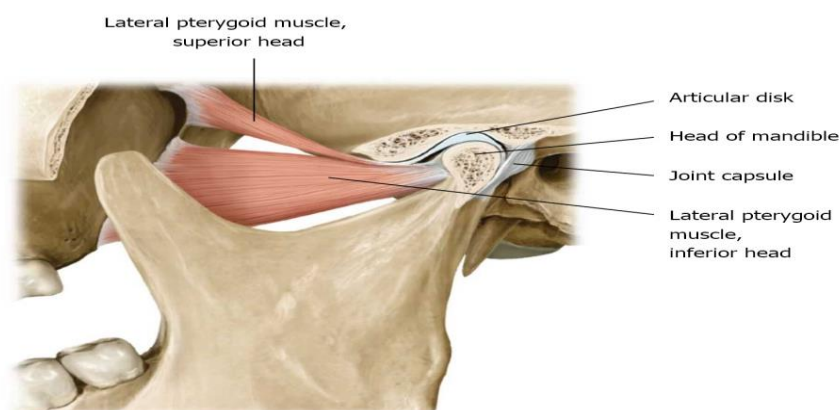
The temporalis muscle functions mainly as an elevator(vertical fibres) and retraction(horizontal fibers) of the mandible. In addition, the temporalis muscle contributes to grinding movements by moving the mandible from side to side.



3- Lateral pterygoid muscle: it has two heads:

- a- Upper head (small): originates from the infratemporal crest, inserts in the TMJ.
- b- Lower head (large): originates from the lateral surface of the lateral pterygoid plate, inserts in the pterygoid fovea.

Bilateral contraction of the lateral pterygoid muscles protrudes and depresses the mandible. A unilateral contraction on a particular side, in conjunction with the ipsilateral medial pterygoid muscle, moves the mandible to the opposite side. This allows for alternating side-to-side movements during chewing.



- 4- **Medial pterygoid muscle:** it has two heads:
- a- Superficial (small): arises from the maxillary tuberosity.
 - b- Deep (large): arises from the medial surface of the lateral pterygoid plate.

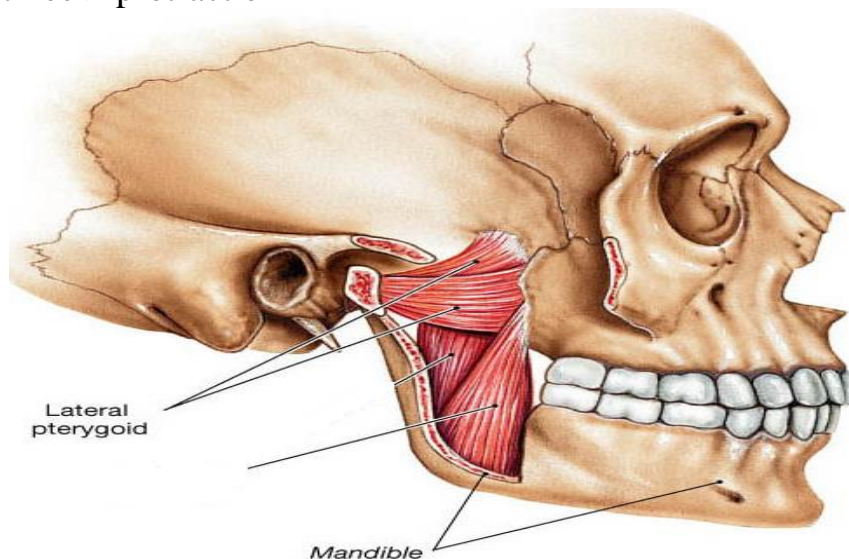
They both insert in the inner surface of the mandible.

The two heads separated by the lower head of the lateral pterygoid muscle.

The major functions of this muscle are elevation of the mandible and side-to-side movements when grinding and chewing. The medial pterygoid is also involved in protrusion of the mandible.

Action (in general):

- Lateral pterygoid > open.
All other three > close
- Temporalis > retraction
All other three > protraction



- Each one of these muscles has two types of fibers, thus it has two functions.

Nerve supply: by the motor branch from the mandibular nerve.

Arterial supply: from the 2nd part of the maxillary artery.

MANDIBULAR NERVE

- ✱ The mandibular nerve originates from the trigeminal ganglion
- ✱ **Trigeminal nerve (the fifth cranial nerve is considered as a ganglion).**

It's divided into 3 divisions, ophthalmic, maxillary and mandibular, all these divisions are sensory.

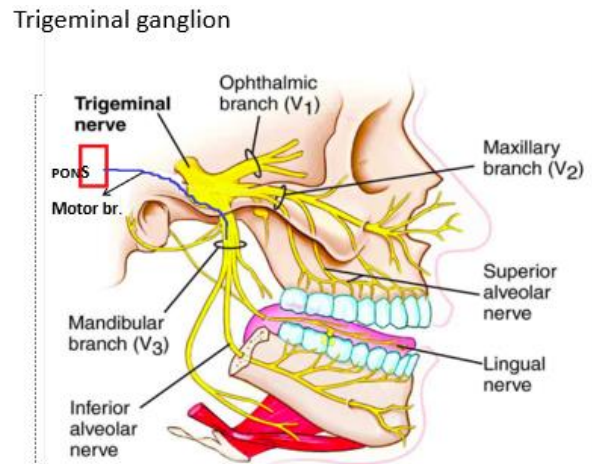
A motor root originates from the pons (part of brain) and passes below the trigeminal ganglion and joins the mandibular nerve

So, the mandibular nerve is considered as motor and sensory nerve.

- ✱ The mandibular nerve has a short course in the cranial cavity then it leaves the cavity by passing through **the foramen ovale** → to the **infratemporal fossae** and becomes deep to the lateral pterygoid muscle. Then it divides into 2 divisions, **anterior (small)** and **posterior (large)**.
- Prior to its anterior and posterior divisions, its main trunk gives 4 branches (3 of them are motor and one is sensory):
 - **The 1st branch:** tensor tympani which supplies the tensor tympani muscle.
 - **The 2nd branch:** tensor palati which supplies the tensor palati muscle in the soft palate.
 - **The 3rd branch:** medial pterygoid, supplies the medial pterygoid muscle.
 - **The 4th branch:** (**sensory**) reenters the cranial cavity through foramen spinosum, it's called **nervus spinosus**, supplies the dura of the middle cranial fossae.

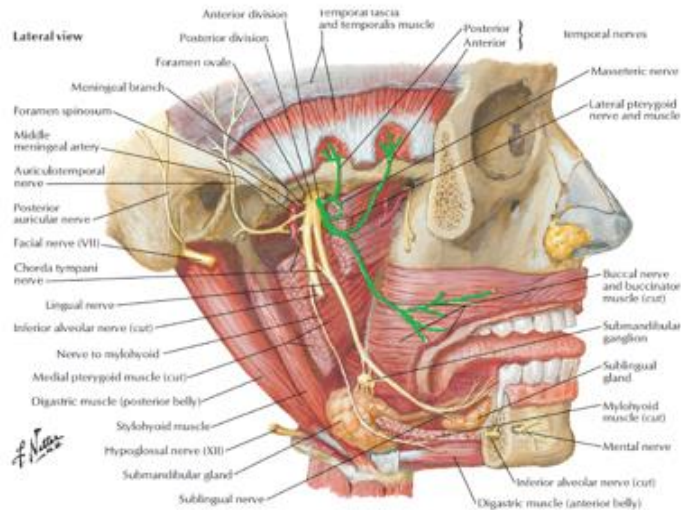
It also gives 3 motor branches and 1 sensory branch:

- 1- Deep temporal branches for temporalis muscle (3 or 2 branches).
- 2- Masseteric branches for masseter muscle (passé through mandibular notch).
- 3- Branch for lateral pterygoid muscle (2 branches).



4- Buccal nerve, courses between the heads of the lateral pterygoid. It then descends over the masseter and buccinator muscles. It supplies the skin of cheek and adjacent gingiva of the molar region.

Anterior Division



- **The posterior division: (large)**

It gives **3 sensory** branches and **one mixed** branch (motor and sensory).

1- (Auriculotemporal nerve):

It's a sensory nerve, begins in the form of two roots, between these two roots, the middle meningeal artery passes. It runs backwards and makes a loop around the TMJ, then it ascends upward to the auricle. During its course, it gives several branches:

- Auricular branches (sensory) that supply the external auditory meatus and the lateral aspect of the tympanic membrane.
- Articular branches that supply the posterior portion of the TMJ.
- Secretory fibers from otic ganglion to the parotid gland.
- Temporal branches that continue superiorly to supply overlying skin and the lateral aspect of the scalp.

- **The otic ganglion:**

- **The otic ganglion is a small parasympathetic ganglion located immediately below the foramen ovale in the infratemporal fossa and on the medial surface of the mandibular nerve and the lesser petrosal (pre-parasympathetic) nerve synapse within it.**

lesser petrosal nerve: •

In the middle ear, the **glossopharyngeal nerve** (cranial nerve IX) gives a branch called **tympanic** branch which makes a plexus called **Tympanic plexus**, supplies mucosa of the middle ear, from this tympanic plexus, arise a branch called **Lesser petrosal nerve** which is a (*pre-parasympathetic*). After it leaves the middle ear, it enters the cranial cavity and leaves it through foramen ovale to the infratemporal fossa and enters the otic ganglion and make a synapse to become post-parasympathetic.

The **outgoing fibers** (parasympathetic fibers) join the auriculotemporal nerve to continue their course to the parotid gland.

☀ Damage of auriculotemporal nerve leads to:

A - Decrease in saliva.

B- Loss of sensation in the temporal region.

2- Lingual nerve:

It is a large branch that passes downward forward on the lateral and ☀ medial pterygoid muscles and then it enters the oral cavity and the floor of the mouth by running ***postero-inferior to the last molar tooth.***

Lingual nerve is a sensory nerve, supplies the floor of the mouth, ☀ adjacent gingiva and anterior two thirds of the tongue (general sensation).

Chorda tympani:

In the middle ear, there's the facial nerve that gives a branch called chorda tympani, which is consisted of two types of fibers (special sensory fibers + pre-parasympathetic fibers).

Chorda tympani leaves the middle ear by passing through the ☀ petrotympanic fissure, then it enters the infratemporal fossae and joins the posterior aspect of lingual nerve at an acute angle.

In the floor of the mouth the pre-parasympathetic fibers leave the lingual nerve and enter the submandibular ganglion (parasympathetic ganglion located in floor of the mouth) and synapse within it.

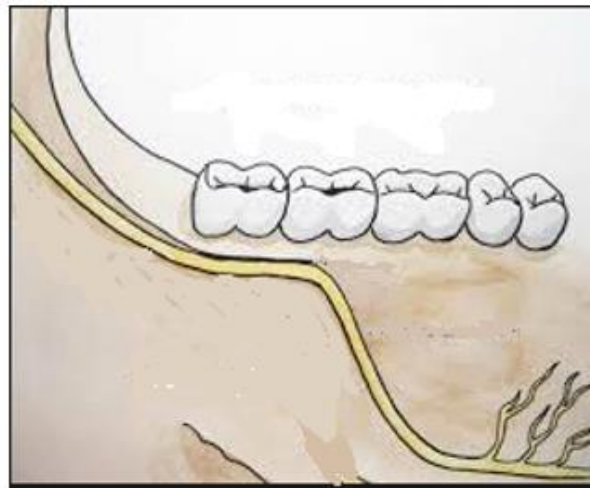
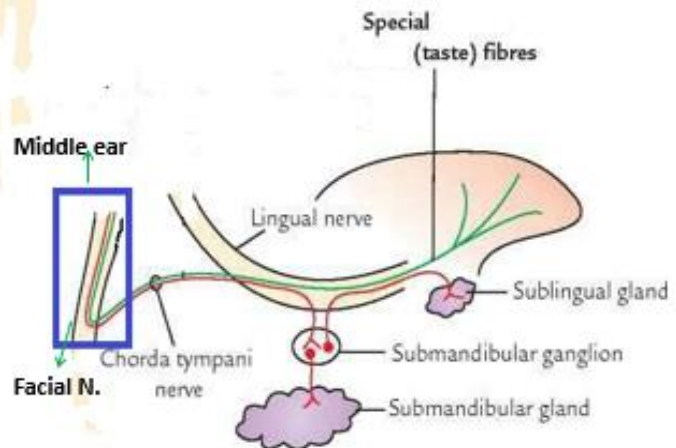
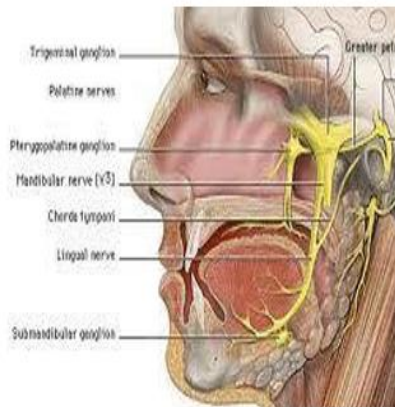
The submandibular ganglion, *suspended by short nerve filaments from the lingual nerve as it passes on the hyoglossus muscle, receives the preganglionic parasympathetic fibers of the chorda tympani nerve via the parasympathetic root.*

Postganglionic parasympathetic fibers from the submandibular ganglion pass to the submandibular gland or rejoin the lingual nerve to be distributed to the sublingual gland and minor salivary glands in the floor of the mouth, providing them with secretomotor(parasympathetic) innervation.

The post-parasympathetic fibers passes directly or re-join the lingual nerve to supply the submandibular and sublingual salivary glands, as well as the lingual glands and small glands in floor of the mouth .

Lingual Nerve and Chorda tympani:

Lingual Nerve



lingual nerve injury may be caused by: third molar removal, local anesthesia, implants.

Symptoms after an injury to the lingual nerve include the following:

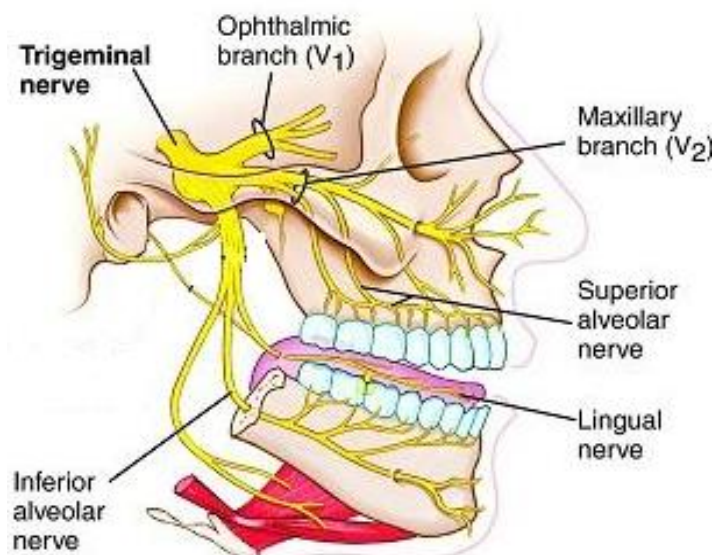
- 1- Numbing of the tongue.
- 2- loss of general sensation to the anterior 2/3 of tongue and the floor of mouth.
- 3- Loss of taste or altered taste of the anterior 2/3 of tongue.
- 4- Decrease secretion of saliva.
- 5- A tingling or burning sensation in the tongue
- 6- Impaired speech.

If the chorda tympani is damaged it leads to:

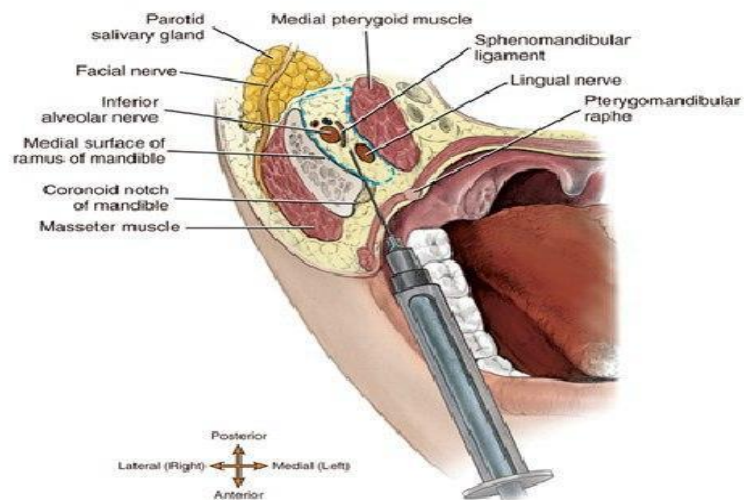
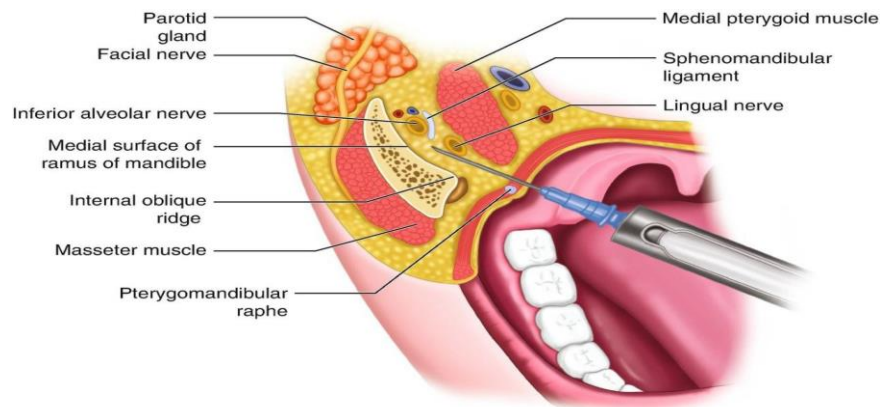
Decrease salivation and loss of taste in the anterior two thirds of tongue.

3- Inferior alveolar nerve: (sensory and motor)

- ✱ It enters the mandibular foramen, passes through the mandibular canal and supplies all the lower teeth. At the level of mental foramen it divides into mental and incisor nerves. The mental nerve exits from mental foramen and supplies the (lower lip, skin of chin, vestibular gingiva). The incisor nerve supplies the incisor teeth and *in some cases the canine*.
- ✱ Before it enters the mandibular foramen, it gives a branch called **Nerve to the mylohyoid** (a motor nerve), to supply the mylohyoid and the anterior belly of digastric.



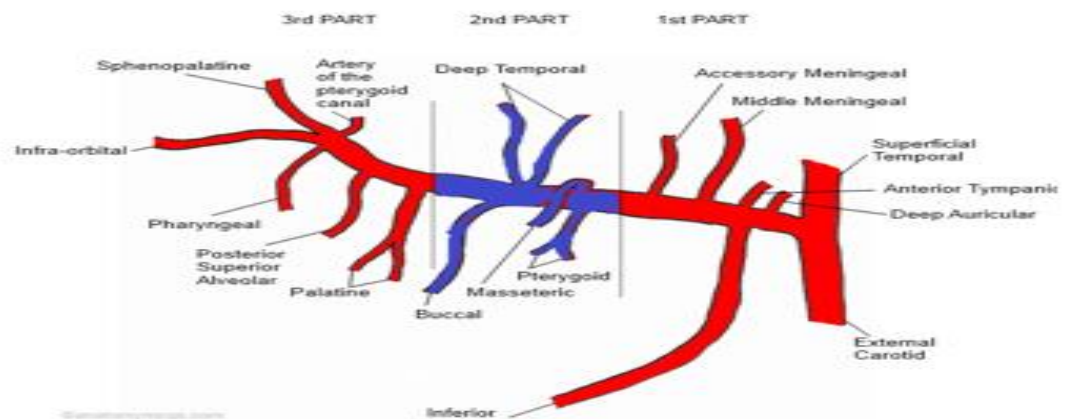
- **Clinical notes:** the inferior alveolar nerve block is commonly used with dental injection to obtain local anesthetic of the mandibular teeth.
- The area where the local anesthetic solution must be deposited is called **pterygomandibular space**, it's a narrow gap located between the medial pterygoid muscle, the mandibular ramus and it's bounded posteriorly by the parotid gland.
- The space contains: the mandibular foramen, the inferior alveolar nerve and vessels enter the foramen, and the lingual nerve located anterior to the inferior alveolar nerve and the Sphenomandibular ligament (from sphenoid to the lingula) located between the inferior alveolar nerve and the lingual nerve.



MAXILLARY ARTERY

- ✿ The external carotid artery divides into superficial temporal and maxillary arteries, the maxillary artery enters the infratemporal fossa (ITF) and passes deep to the neck of condyle.
- ✿ In the ITF, the maxillary artery is divided into 3 parts by the lateral pterygoid muscle:

Maxillary Artery



- The 1st part (mandibular portion): from the neck of condyle to lateral pterygoid muscle.
 - The 2nd part(pterygoid portion):it is inconsistent because it may be passes either superficial or deep to the lateral pterygoid muscle,
 - The 3rd part(pterygopalatine portion) : enters another region (pterygopalatine fossa).
- 1) The 1st part: it gives the following branches:
- **Deep auricular:** supplies the skin of the external auditory meatus and tympanic membrane.
 - **Anterior tympanic:** the 2nd branch,opposite to the chorda tympani, it enters the petrotympanic fissure to supply the middle ear.
 -
 - **Inferior alveolar artery:** it has the same course of the alveolar nerve that supplies all of the lower teeth,and ends as incisive and mental arteries. also gives an artery to the mylohyoid.
 - **Middle meningeal artery:** located between the two roots of the auriculotemporal nerve, ascends upward, enters the foramen spinosum, divides into anterior “frontal” and posterior “parietal”, then it’s directed to the meninges (dura mater).

★ **Clinical notes:** the anterior branch passes deep to a region called “pterion”, which is a fontanelle found in fetus, bones in this area are fragile. Since the middle meningeal artery passes deep to it, so at any accident, the bones will fracture and the MMA will tear. After the MMA is ruptured, it will form a hematoma between the dura mater and the bone, so the pressure will be on the brain especially on the motor area that is located in the front of the pterion which will cause paralysis in the opposite part of the body (hemiplegia).

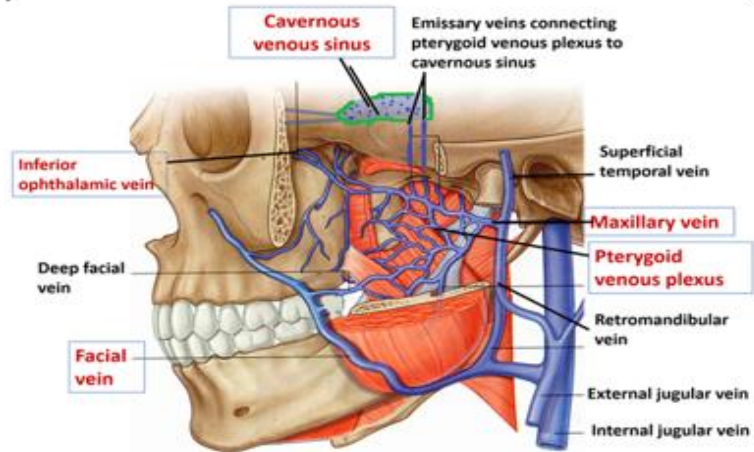
- **Accessory meningeal artery:** it also supplies the meninges, enters the cranial cavity by passing through the foramen ovale (sometimes it exists, sometimes not).

2) **The second part:** it gives muscular branches to the muscles of mastication and buccinator muscle.

- The anterior and posterior deep temporal arteries
- pass superiorly, deep to the temporalis muscle that
- they supply.
- ■ The short pterygoid arteries arise from this portion
- to supply the medial and lateral pterygoid
- muscles.
- ■ The masseteric artery, accompanied by the same named nerve, passes through the mandibular notch
- .
- ■ The buccal artery accompanies the buccal nerve
- to supply the cheek and the buccinator muscle.

Pterygoid Plexus and Maxillary Vein:

The pterygoid plexus of veins is a massive network of venous channels lying on the surfaces of the lateral and medial pterygoid muscles. The plexus receives venous tributaries from vessels corresponding to the named arteries branching from the maxillary artery. This plexus is in direct or indirect communication with a different area, including the cranial cavity and cavernous sinus, the nasal cavity, facial vein, deep facial veins.



The maxillary vein is the short venous trunk that accompanies the maxillary artery passes deep to the neck of condyle and enters the parotid region to join the superficial temporal vein to form the retromandibular vein

Improper administration of anesthesia for a maxillary molar tooth may cause the needle to puncture the pterygoid venous plexus, resulting in a hematoma with noticeable swelling. The pterygoid plexus or veins have communications with the cavernous sinuses (veins in the brain) through emissary veins .

Cavernous sinus thrombosis is a life-threatening complication that may result from infection spreading back through the emissary veins from infected thrombi in the pterygoid plexus of vein .

Pterygopalatine fossa

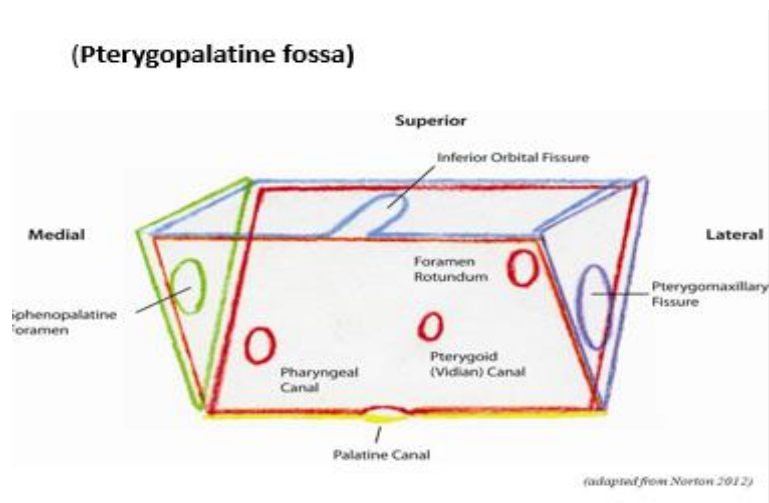
The boundaries of the pterygopalatine fossa are the:

- ***Pterygomaxillary fissure (laterally)***
- ***Perpendicular plate of palatine bone (medially)***
- ***Pterygoid plates (posteriorly)***
- ***Maxilla (anteriorly)***
- ***Greater wing of sphenoid (superiorly)***

Pterygopalatine fossa: the right and left pterygopalatine fossae are separated by the vertical plate of palatine bone.

This region has a communication with ITF (Infratemporal fossa) through pterygomaxillary fissure.

- ✿ Also, with the orbit through **inferior orbital fissure**.
- ✿ With oral cavity → through the **greater and lesser palatine** and **incisive foramens**.
- ✿ With nasal → through **sphenopalatine foramen** which is located on the upper part of the



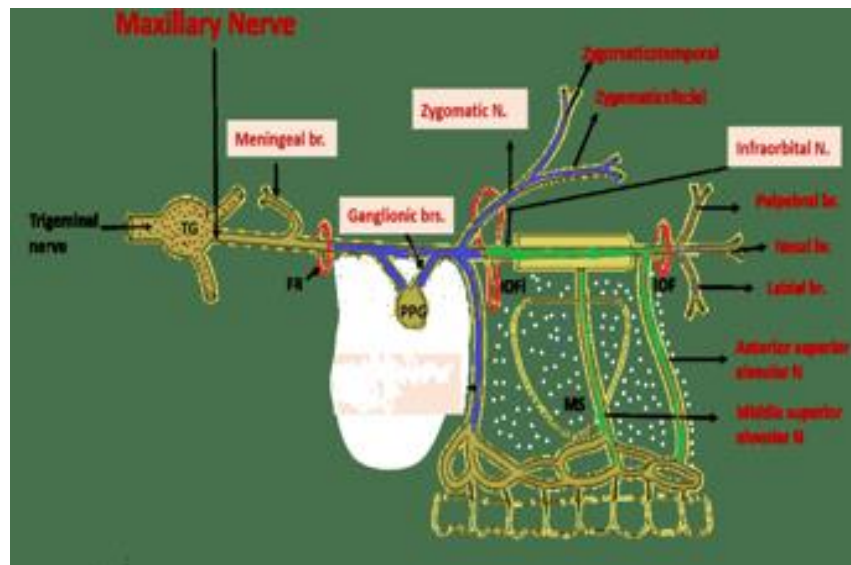
- ✿ **vertical plate of palatine bone**.
- ✿ With ITF → through the **pterygomaxillary fissure**.
- ✿ With face → through the **infraorbital foramen**.
- ✿ With middle cranial fossa → through the **foramen rotundum** and **pterygoid canal**.

MAXILLARY NERVE

The maxillary division of trigeminal nerve (arises from the trigeminal ganglion), it is sensory and located in the middle cranial fossa.

Its course is divided into parts:

- The 1st course: intra cranial portion which is a short course, extends from the trigeminal ganglion to the foramen rotundum , then enters the pterygopalatine fossa by passing through the foramen rotundum.
- It gives a single branch called **meningeal branch** that supplies **meninges** in the middle cranial fossa.



The 2nd course:

pterygopalatine portion(after entering the pterygopalatine fossa) , it gives 3 branches:

1-Zygomatic branch:, enters the inferior orbital fissure which leads it to the orbital cavity along its lateral wall, then it divides into two branches, **zygomaticofacial** (supplies zygoma), and **zygomaticotemporal** → supply the skin of temporal fossa.

2- Ganglionic branches: supply sensory fibers to the pterygopalatine ganglia(parasympathetic ganglion) which located in the pterygopalatine fossa.

3- Posterior superior alveolar nerve: which enters the maxilla by passing through small foramina located on the posterior surface of maxill and enter the maxillary sinus .Then descends downward to the root of molar teeth to supply molar teeth, gingiva and maxillary sinus.

-

➤ The 3rd course **infraorbital portion**: enters the inferior orbital fissure to the infraorbital groove, it changes its name to **infraorbital nerve**, it gives two branches:

- 1- **Middle superior alveolar nerve**: passes inferiorly through the floor of the orbit to enter the maxillary sinus. supplies the premolar teeth until canine, adjacent gingiva and also maxillary sinus.
- 2- **Anterior superior alveolar nerve**: before the exit of infraorbital nerve into the face it gives this nerve and enters the maxillary sinus supplies canine, anterior teeth, gingiva and maxillary sinus, it also gives a branch called nasal branch to supply nasal septum.

The anterior, middle and posterior alveolar nerves form plexus called superior dental plexus which supply the upper teeth.

➤ The 4th course **facial portion**: the infraorbital nerve exits into the face through the infraorbital foramen and divided into three groups of branches:

- 1- **Inferior palpebral branches**: ascending upward to supply the skin and conjunctiva of lower eyelid
- 2- **Superior labial branches**: descend downward to supply the skin and the mucous membrane of the upper lip.
- 3- **Lateral nasal branches**: passes toward the lateral aspect of the external nose and supply the skin of the lateral aspect of the nose and the mucous membrane of the cartilaginous portion of the nasal septum.

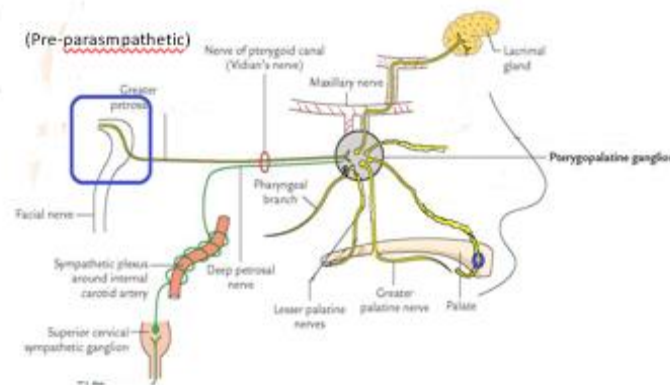
Pterygopalatine ganglion: •

It is parasympathetic ganglion that hangs from the maxillary nerve in the pterygopalatine fossa. It receives three types of fibers (sensory, sympathetic and pre-parasympathetic) and only the pre-parasympathetic synapses in the ganglion.

Postganglionic parasympathetic fibers distributed to the lacrimal gland, mucosal glands of the nasal fossa, palate and pharynx.

- ☀ The middle ear is located in the petrous portion of temporal bone. The facial nerve is located in the middle ear.
- ☀ The facial nerve in the middle ear gives a branch called **Greater petrosal nerve**, which is a pre-parasympathetic nerve, it leaves the middle ear by passing through hiatus

Pterygopalatine ganglia



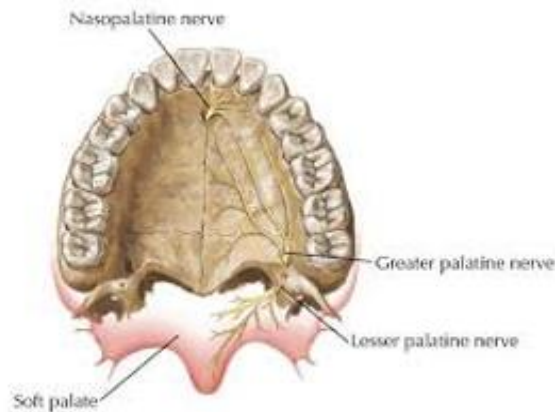
- called “hiatus for greater petrosal nerve” and it passes to the middle cranial fossa.

Within the middle cranial fossa, the internal carotid artery is located, which is the main blood supply of the brain.

Around this artery, there’s a plexus of nerves (Sympathetic nerve plexus). From this plexus, a nerve called **deep petrosal nerve** arises (it’s a sympathetic nerve which had been synapsed in the superior cervical ganglion).

- These two nerves (deep + greater petrosal nerves) join together in the middle cranial fossa to form a nerve called **Vidian nerve** or **nerve of the pterygoid canal**.
- This nerve enters the pterygoid canal.
- The pterygoid canal leads this nerve to the pterygopalatine fossa, and then enters the ganglia “**pterygopalatine ganglion**”.
- So, there are **3 types** of fibers entering the ganglion:
 - 1- **Sensory fibers** → from **maxillary nerve**.
 - 2- **Sympathetic fibers** → from **deep petrosal nerve**.
 - 3- **Pre-parasympathetic fibers** → from **greater petrosal nerve**.
- ***Important Note: only the fibers of the greater petrosal nerve synapse within this ganglion (pterygopalatine ganglia).***

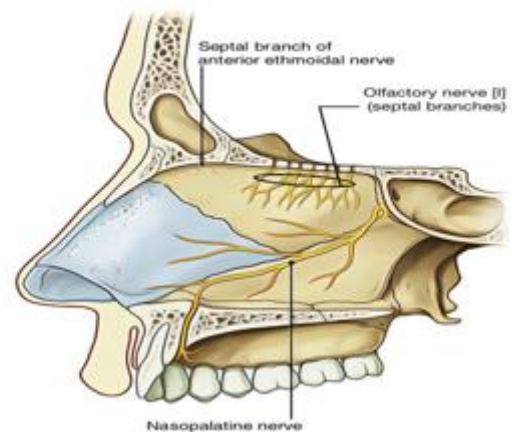
From pterygopalatine ganglion, the following nerves arise:



- 1) **Nasopalatine nerve:** also called “long sphenopalatine nerve”. It passes through “sphenopalatine foramen”, foramen leads to the nasal cavity, so this nerve will pass to enter the nasal cavity and descends along the nasal septum until it reaches the incisive fossa, it passes through this fossa, enters the oral cavity and supplies the mucous membrane of the hard palate to the maxillary canine. (it also supplies the nasal septum during its course).

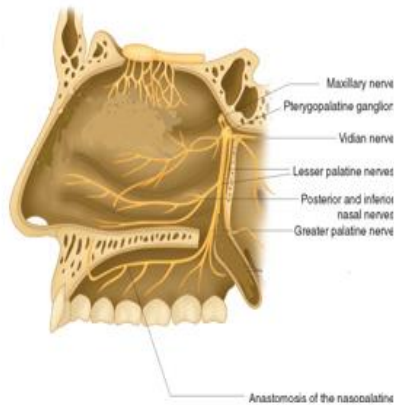
Nasal septum

- 2) **Greater palatine nerve:** it descends downward through a canal called “palatine canal” and exits through the greater palatine foramen. It passes forward to supply the mucous membrane of the hard palate till the level of the maxillary canine.



- 3) **Lesser palatine nerve:** it descends vertically through the lesser palatine canal, exits through the lesser palatine foramen to the oral cavity and directed backward to supply the mucous membrane of the soft palate.

Lateral wall of the nasal cavity



membrane of the pharynx.

4) Posterior lateral nasal nerve: also called “short sphenopalatine nerve” this nerve enters the nasal cavity by passing through sphenopalatine foramen. It supplies the mucous membrane of the posterior part of the lateral wall of the nasal cavity.

5) Pharyngeal nerve: it passes backward, enters small foramina (pharynx canal) to supply part of the mucous

6) Orbital nerve: this nerve passes through the inferior orbital fissure to enters the orbit to supply the periosteum of the orbit and small muscle (orbitalis muscle) and joins the zygomaticotemporal nerve (branch of zygomatic nerve).

✿ **The lacrimal gland** is supplied by **lacrimal nerve**. (which is sensory nerve and it passes through the lateral wall.

A communication occurred between zygomaticotemporal and lacrimal nerves, through this communication, the lacrimal nerve picks up the sympathetic and parasympathetic from the zygomaticotemporal and carries these branches to the lacrimal gland.

✿ **So, the damage to the facial nerve will decrease the lacrimation.**

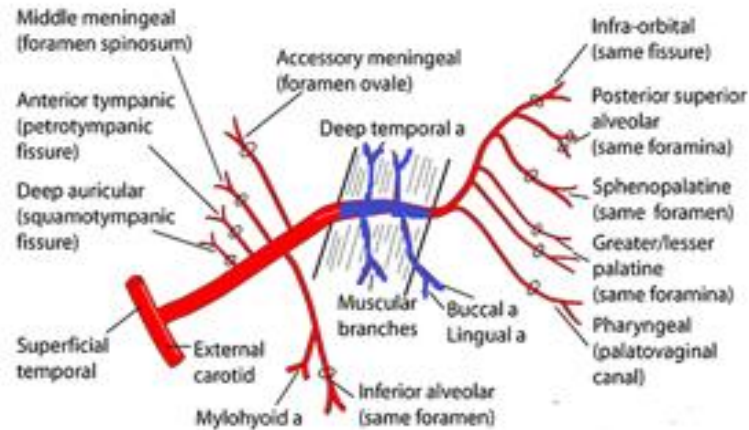
Maxillary artery (part 3):

The third portion of the maxillary artery enters the pterygopalatine fossa via the pterygopalatine fissure (pterygomaxillary fissure). Branches of the pterygopalatine artery supply structures in the orbit as well as the maxilla and teeth, palate, pharynx, paranasal sinuses, nasal cavity, and auditory tub.

✿ *In general, the branches of the part 3 follow the different branches of the maxillary nerve and pterygopalatine ganglion.*

✿ As well as with these arteries, there are veins of the same names.

Maxillary artery (part 3)



❖ Clinical notes for maxillary nerve:

1)

- The upper teeth (maxillary teeth) are supplied by the maxillary nerve through the anterior superior alveolar nerve, the middle superior alveolar nerve and posterior superior alveolar nerve.

The 3 nerves are from plexus called “superior dental plexus”, supply all of the upper teeth. These 3 nerves also supply the maxillary sinus.

- Sinusitis: it's the inflammation of the maxillary sinus causing a toothache especially the upper molar, that's because the root of the maxillary teeth and especially the molar region is closely related to the maxillary sinus, so, any inflammation in these sinuses will cause a pressure to the roots of molar teeth and cause “referred pain”*

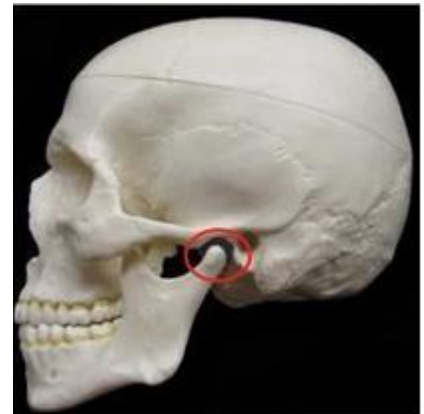Referred pain: it's when the pain is located away from or adjacent to the organ involved. For example, in the case of “Heart attack” and “Gallstones”.

2)

Damage or cut in the facial nerve will leads also decrease in lacrimation because the facial nerve gives the greater petrosal nerve which gives scretomotor (parasympathetic) to many glands including the lacrimal gland)

TEMPROMANDIBULAR JOINT(TMJ)

- It is also called mandibular or jaw joint.
- It is bilateral synovial joint and the articulation occurs between the **condyle of the mandible** and the **mandibular fossa** and the **articular eminence(tubercle) of temporal bone**. The articular surfaces covered by layer of fibrous cartilage.
- The joint is surrounded by a capsule (joint capsule) which is attached superiorly to the periphery of mandibular fossa and inferiorly to the neck of condyle. The inner aspect of the joint capsule is lined by synovial membrane.



Important Relations of the Temporomandibular Joint:

Anteriorly: The mandibular notch and the masseteric nerve and artery.

Posteriorly: The tympanic plate of the external auditory meatus and the glenoid process of the parotid gland.

Laterally: The parotid gland, fascia, and skin.

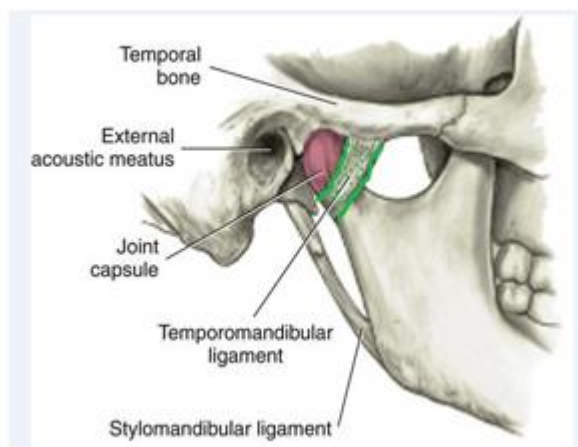
Medially: The maxillary artery and vein and the auriculotemporal nerve.

✿ Ligaments of the joint:

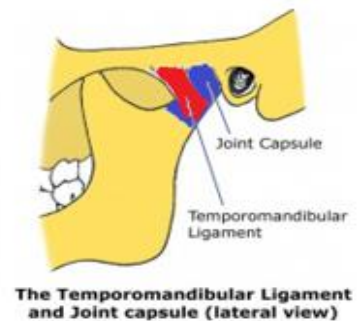
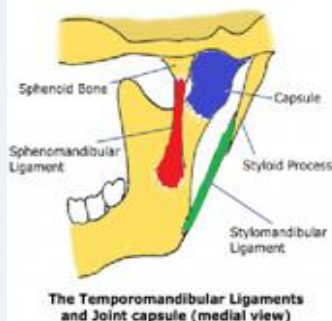
- The temporomandibular ligaments (collateral ligaments): is a lateral thickening of the capsule and it extends from the articular eminence to the posterior aspect of the neck of condyle, so it prevents posterior and inferior displacement of the condyle.

✿ There are two other accessory ligaments:

Joint capsule and ligaments;



Joint capsule and ligaments;

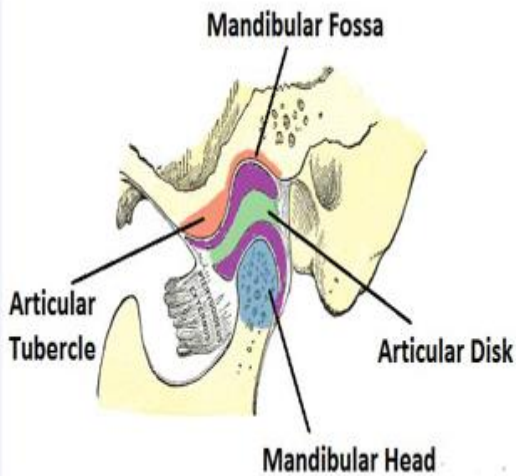
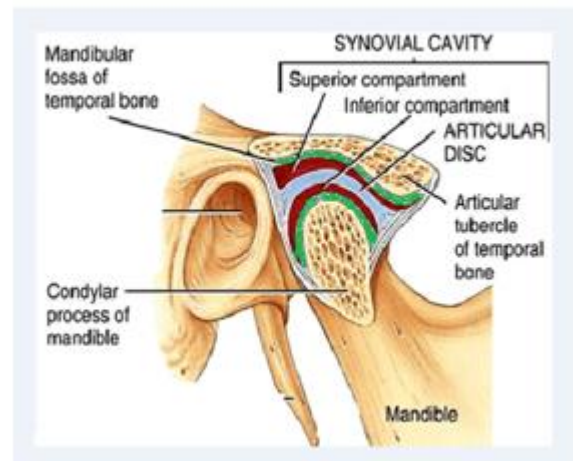


- 1- **Sphenomandibular ligament:** It extends from the spine of sphenoid bone to the lingula of the mandible, it is a band of fibrous thickening and is regarded as the remnant of Meckel's cartilage.
- 2- **Stylomandibular ligament:** It extends from the styloid process to the angle of the mandible. It forms a thickening which separates the parotid region from the infratemporal fossa.

✿ Articular Disc (Meniscus):

- A dense fibrous tissue located within the synovial cavity called articular disc. It is located between condyle and mandibular fossa and it is attached to the internal periphery of the joint capsule.

Articular Disc (Meniscus):

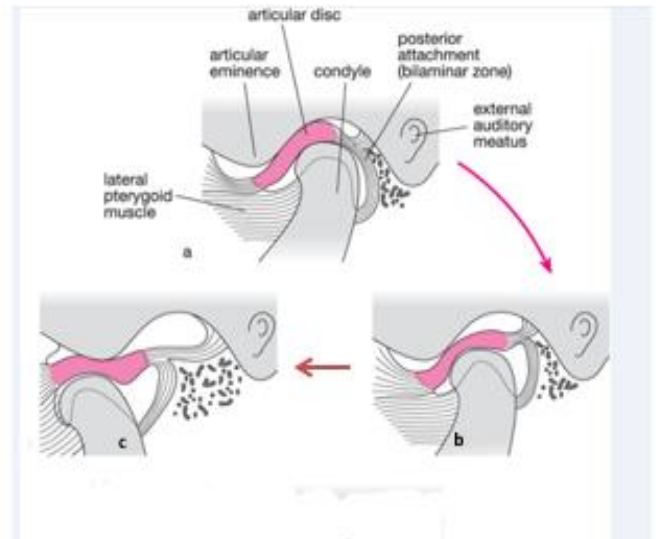
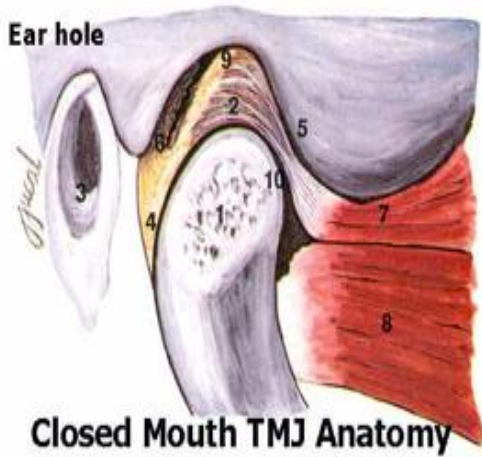


- It is biconcave, serves to provide articular surfaces between its inferior surface and the condyle and between its superior surface and the mandibular fossa and articular eminence. The articular disc divides the joint into separate compartments: the superior compartment and the inferior compartment.

✿ Positions of the mandible:

- **Rest position:** In this position few millimeters separate the occlusal surfaces of teeth (freeway space). In this position the condyle rest on the posterior portion of the articular eminence.
- **Centric Occlusion:** Closing the freeway space and allowing the teeth to come into maximum contact in the midline.
- In this position the condyle sits within the mandibular fossa.

Centric occlusion



✿ **Types of mandibular movements:**

Two basic movements can take place at the TMJ, these are:

1- **Hinge or Rotational movement:**

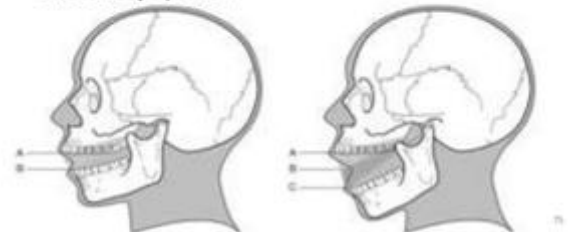
- It takes place between the inferior surface of the articular disc and the condyle.

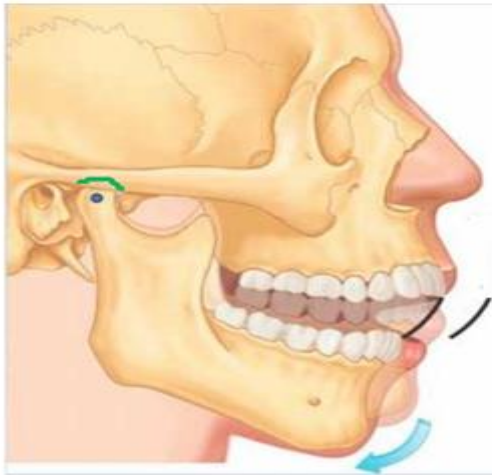
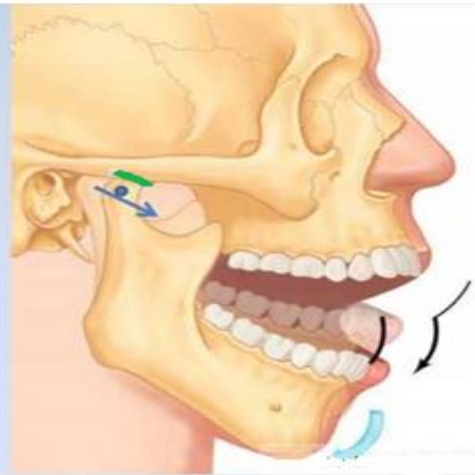
2- **Sliding or Translational movement:**

- It takes place between the superior surface of the disc and the mandibular fossa and eminence. In this movement, the disc with condyle move (sliding) together forward along the undersurface of mandibular fossa and the articular eminence.
- The combination of these two movements is required when the mouth is opened widely. Hinge opening in normal adult ranges 20- 25 mm between upper and lower anterior teeth. When it's companied with sliding movement, the range is increased to 35-45 mm.

MOVEMENTS

- **Rotational / hinge** movement in first 20-25mm of mouth opening
- **Translational** movement after that when the mouth is excessively opened.



Hinge movement**Sliding movement**

✿ Also, six movements can take place at the temporomandibular joint:

1- Protraction 2- Retraction 3- Depression 4- Elevation 5- Right excursion(deviation) 6- Left excursion(deviation).

✿ Nerve Supply of TMJ:

The joint supplied by the **mandibular nerve** through ∴

- 1-The auriculotemporal nerve supplies the posterior part of the joint.
- 2-Branches from the nerve to masseter (masseteric branches) supply the anterior part of the joint.

❖ **TMJ disorder:**

- TMJ is like all synovial joints, it is susceptible to painful arthritis (joint inflammation).

❖ **TMJ disorder characterized by:**

- Pain which may radiate to face or muscles of mastication, restricted movement(ankylosis) and joint clicking or (crepitus).
- Tender, sore jaw muscles (muscles of mastication); pain at opening or closing the jaw; inability to open or close the jaw; pain upon clenching; unusual headaches; clicking or grinding noise when chewing or yawning; and crunching sounds when chewing.

- The causes of TMD are not always clear but may include grinding the teeth when asleep, clenching during periods of stress, injury to the face and/or jaw, fractured mandible, whiplash, rheumatoid arthritis, unequal jaw growth, malocclusion, missing teeth, poor-fitting dentures, and periodontal disease. Any one or combination of these events may produce acute TMD that, if left to progress to a chronic state, may be difficult to manage and may eventually cause the addition of psychological factors to the problem. Persons experiencing TMD symptoms should consult a dentist or a TMD specialist.

The articular disc of the temporomandibular joint may become partially detached from the capsule, and this results in its movement becoming noisy and producing an audible click during movements at the joint.

Dislocation:

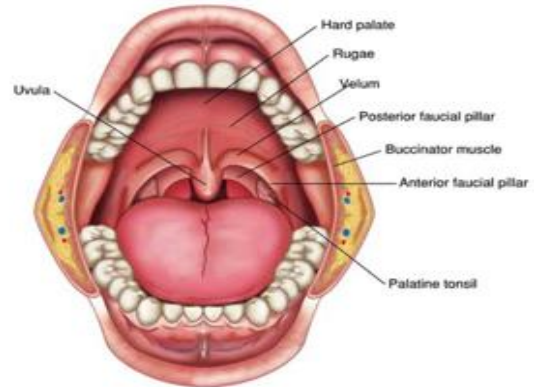
- When the condyle of the mandible is displaced from the mandibular fossa in the anterior direction and cannot return to its normal position without use of external forces.
- This occurs due to the loose or lax ligaments and during forceful yawn, or prolonged dental appointment.
- The dislocation occurs anteriorly because there are no ligaments found anteriorly.
- In general, the TMJ regarded as a weak joint because it is mainly supported by muscles of mastication.

ORAL CAVITY

- Oral cavity or the mouth, it represents the first part of the digestive system, the main functions of this part are:

- 1- Mastication.
- 2- Salivation.
- 3- Swallowing.
- 4- Tasting.
- 5- Speech.

- The oral cavity opens anteriorly through the transverse oral fissure (which is guarded by upper and lower lip).



- Posteriorly, the oral cavity is connected with the oropharynx through the isthmus of the ***fauces(oropharyngeal isthmus)***, it is bounded by the soft palate superiorly, by the surface of the posterior one third of the tongue inferiorly and by the palatoglossal arches laterally.

- **Boundaries of the oral cavity:**

- Anterolaterally, or the anterior lateral wall is formed by the lips and cheeks.
- The roof is formed by the upper jaw (maxilla, hard and soft palate).
- The floor is formed by the lower jaw (mandible, mylohyoid muscle which forms the muscular diaphragm).

- **The oral cavity is divided into two parts:**

- 1) **The vestibule:** which is a narrow space located between the teeth and the mucosa (which lines the lips and cheeks).
- 2) **The oral cavity proper:** which is the space between the upper and lower dental arches.

- **The roof (palate):**

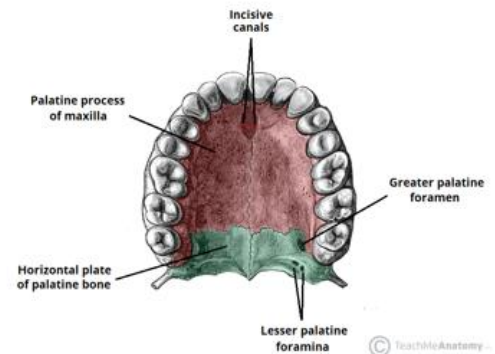
- The palate separates the nasal cavity above from the oral cavity below.
- The anterior two thirds of the palate contain a bony skeleton called the hard palate.
- The posterior third is formed by a movable portion which consists no bony skeleton and called the soft palate.

- ***The mouth is one of the important areas of the body that must be examined, to recognize all the structures visible in the mouth and be familiar with the normal variations in the color of the mucous membrane covering underlying structures. The sensory nerve supply and lymph drainage of the mouth cavity should be known.***

HARD PALATE

Palate(hard palate)

- **The hard palate:** it's formed by two bones:
 - **Anteriorly:** palatine process of the maxilla which forms the anterior two thirds of the hard palate.
 - **Posteriorly:** formed by horizontal plate of the palatine bone.

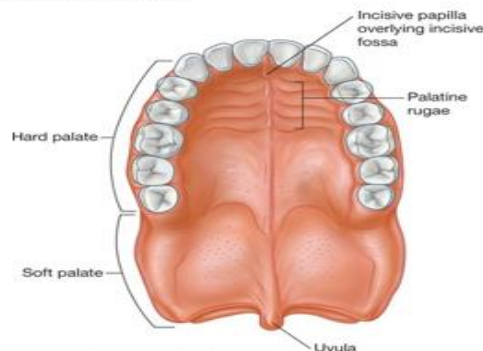


✿ **There are 3 foramina open in the hard palate:**

- 1- Anteriorly, **incisive foramen** (or fossa), opens behind the maxillary central incisors in the midline, and transmits the nasopalatine nerves and vessels.
- 2- **The greater palatine foramen**, located medial to the root of the third molar and transmits the greater palatine nerves and vessels.
- 3- **The lesser palatine foramen**, located posterior to the greater palatine and medial to the maxillary tuberosity, transmits the lesser palatine nerves and vessels.

- ✿ The mucosa of the hard palate is tightly bound to the underlying bones.
 - ✿ Behind the maxillary central incisors, the incisive papilla, which the incisive foramen is located beneath it.
 - ✿ Number of parallel transverse ridges known as rugae, radiate laterally from the incisive papilla.
 - ✿ The midline palatine raphe runs posteriorly from the incisive papilla.
- There are also numerous glands open into the mucosa as small pits.

Palate: Mucous membrane



SOFT PALATE

- **The soft palate:** (it has no bony parts)
- It is a movable portion, attached anteriorly to the posterior border of the hard palate, while posteriorly, it ends as a free edge with a small projection called **uvula**.
- The soft palate separates the oropharynx from the nasopharynx above. The superior surface is covered with respiratory mucosa while the inferior surface is covered with oral mucosa.
-
- It's composed of:
 - 1- **Palatine aponeurosis.**
 - 2- **Five pairs of muscles.**

✿ **Muscles of the soft palate:**

1) **Palatopharyngeal (Palatopharyngeus) muscle: (PPM)**

- It originates from the palatine aponeurosis and inserts in the lateral wall of pharynx.
- This muscle is covered by mucous membrane, that's why it's called "posterior pillar" or "palatopharyngeal arch".

2) **Palatoglossus muscle: (PGM)**

- Originates from the palatine aponeurosis and inserts in the side of the tongue.
- It's covered by mucous membrane to form the "anterior pillar" or "palatoglossus arch".

✿ **Isthmus of fauces is present in the space between the right and left palatoglossus arch.**

3) **Levator (velli) palatini muscle:**

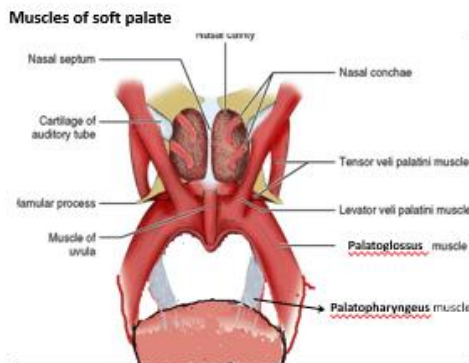
- Originates from the medial aspect of the auditory tube, it passes downward, medialward and inserts in the palatine aponeurosis.

4) **Tensor(velli) palatini muscle:**

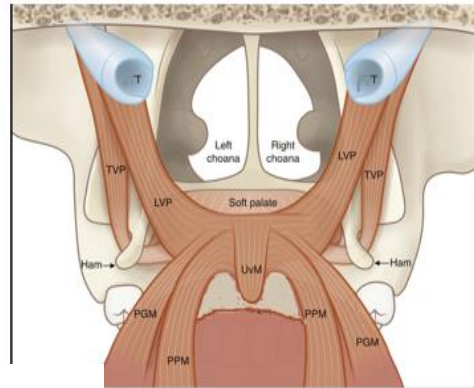
- Originates from the lateral surface of the auditory tube and inserts in the upper surface of the palatine aponeurosis.

5) Uvular muscle:

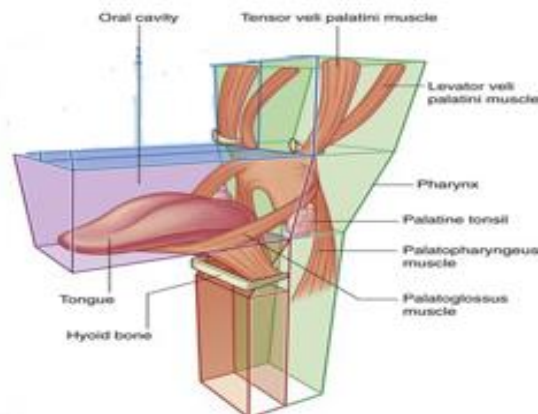
- Arises from the posterior nasal spine, directs posteriorly and inserts in the uvula.



Muscles of soft palate



Muscles of soft palate



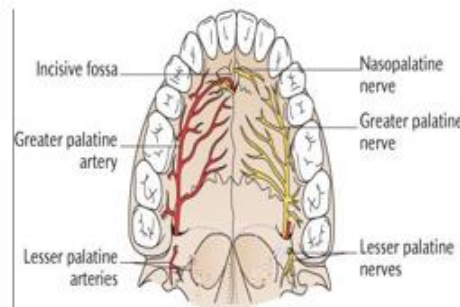
✿ Actions of these muscles:

- **Palatopharyngeus M. + Palatoglossus M.** (with the help of the uvular M.), they seal the oropharynx from the oral cavity by approximate the soft palate with the posterior third of the tongue.
- **Levator palatini M.:** it acts to elevate the soft palate in order to seal the nasopharynx from the oropharynx.
- **Tensor palatini M.:** it makes the soft palate rigid or tense in order to let the other muscles act.

✿ Nerve supply of the palate:

- The nerve supply is from the pterygopalatine ganglion associated with the maxillary nerve.
- 1- **Nasopalatine nerve:** arises from the pterygopalatine ganglion and passes to the nasal cavity along the nasal septum, it appears in the oral cavity by passing through the incisive foramen.

Blood and nerve supply



- It supplies the mucous membrane of the lingual mucosa and palatal mucosa anterior to the maxillary canines.
- 2- **Greater palatine nerve:** arises from the pterygopalatine ganglion and passes inferiorly through the greater palatine canal to appear in the oral cavity by passing through the greater palatine foramen.
 - It supplies the remainder part of the mucous membrane of the hard palate.
- 3- **Lesser palatine nerve:** arises from the pterygopalatine ganglion and passes inferiorly through the lesser palatine canal, it appears in the oral cavity by passing through the lesser palatine foramen
 - It supplies the mucous membrane of the soft palate.
- ✿ **Blood supply:**
 - The arterial supply is closely parallel to the nerve supply.
 - Arising from the 3rd part of the maxillary artery as:
 - 1- Nasopalatine artery.
 - 2- Greater palatine artery.
 - 3- Lesser palatine artery.
- ❖ **Clinical Notes (palate)**

a) Paralysis of the muscles of soft palate (because of the damage of vagus nerve or the cranial part of accessory nerve) is characterized by:

1- Nasal regurgitation of liquid.

2- Nasal twang in voice.

3- Flattening of palatal arches on the side of lesion and deviation of uvula to opposite side.

b) Osseous protrusions, palatal tori (is a bony protrusion on the palate). may be observed on the hard palate. These tori, usually bilateral, they can interfere with fitting of maxillary dentures. They may need to be removed surgically before the taking of impressions.

c) The soft palate is a movable structure and must be avoided by the posterior aspect of the maxillary denture because its muscular action will break the palatal seal and dislodge the prosthesis.

d) A cleft refers to a gap/split in the palate. It results from a defect during development when the palatal parts fail to fuse with each other. It may combine with cleft lip

- Unilateral cleft palate
- Bilateral cleft palate
- Incomplete or partial cleft
- Bifid uvula-cleft affecting only uvula
- Cleft of soft palate-affecting uvula and soft palate
- Cleft of soft palate-extending into the hard palate

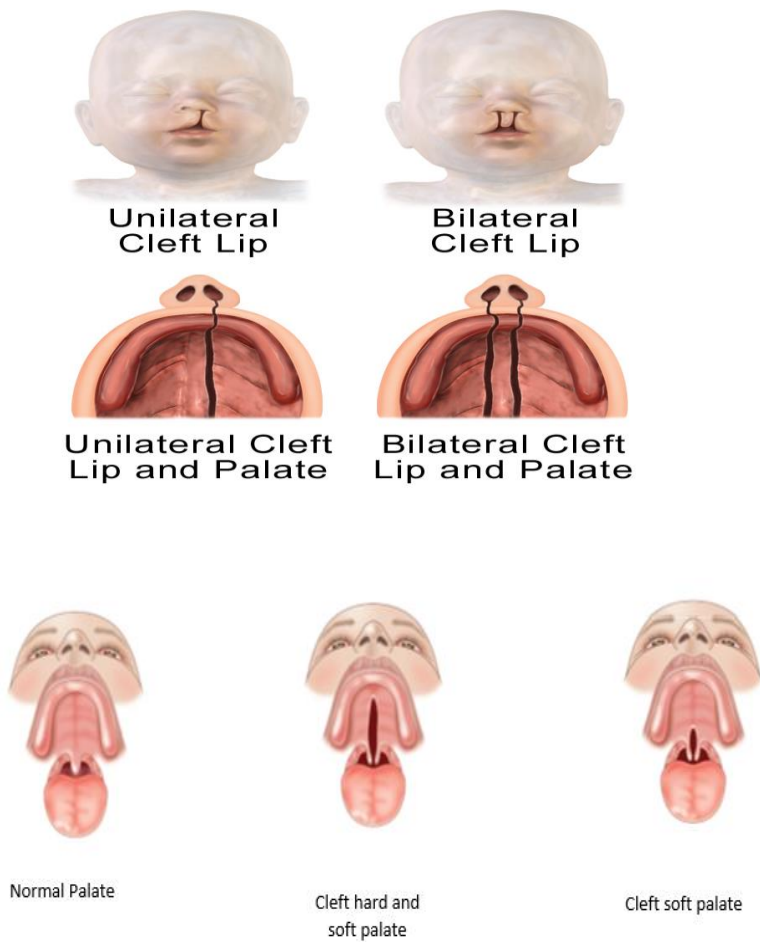


Figure 2: Types of cleft palate (7)

THE TONGUE

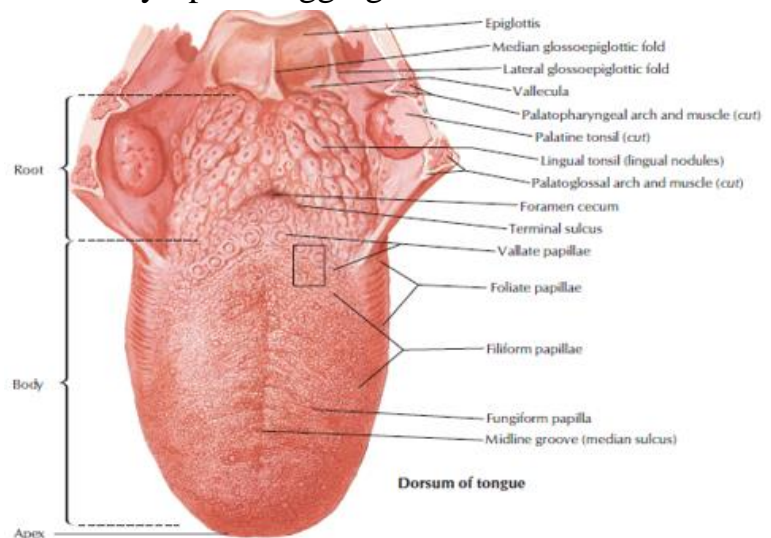
The tongue is a muscular organ covered by mucous membrane. It is located in **two regions**:

- 1- In the oral cavity (in the floor of the mouth).
- 2- In the oropharynx (ventral wall).

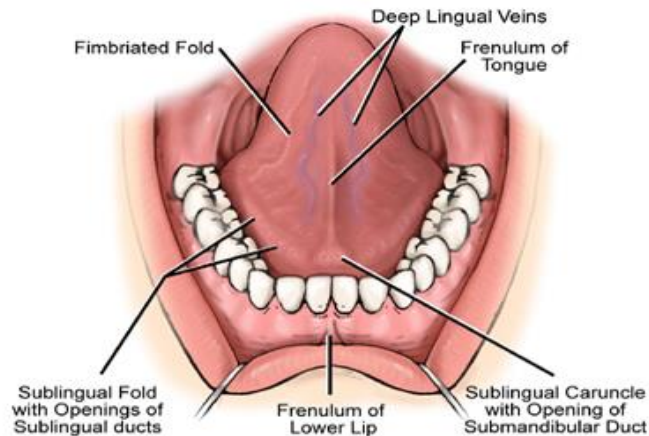
- It's an important organ in:
 - a) Mastication.
 - b) Swallowing.
 - c) Tasting.
 - d) Speech.

★ **Parts of the tongue**

- 1- **Body of the tongue**: it's the anterior two thirds of the tongue which is located in the oral cavity.
- 2- **The root of the tongue**: it's the posterior one third of the tongue, located in the oropharynx. It consists of numerous lymphoid aggregates known as the lingual tonsils.
- 3- **The sulcus terminalis**: a V-shaped groove, the apex of this groove is directed posteriorly. It divides the tongue into anterior two thirds and posterior one third.
- 4- **The foramen cecum**: a small pit at the apex of the sulcus terminalis.
- 5- **The dorsum**: it's the superior surface of the body which is characterized by rough appearance because of small numerous projections called "Lingual papillae" which are of 3 types:
 - a- Filiform.
 - b- Fungiform.
 - c- Vallate papilla.



- ★ Within the wall of some papillae (especially the vallate), there are receptor organs for special sensation of taste called "taste buds".



★ The dorsum of the body possesses the median sulcus, a shallow groove. Deep to this sulcus there is a vertical fibrous tissue called median lingual septum which partly dividing the tongue longitudinally in the midline into right and left halves.

This septum united posteriorly to hyoid bone and some muscle fibers of intrinsic muscles attach to it.

6- **Inferior surface of the body:** is covered by a thin mucous membrane without papillae.

In the median part, there's a prominent fold known as "Lingual frenulum" which connects the tongue with the mandible and the floor of the mouth.

★ On each side of the inferior surface, there's an irregular fold called "**fimbriate fold**", between the frenulum and the fold, there are **deep lingual veins**.

★ **Muscles of the tongue**

- The tongue is composed of voluntary striated skeletal muscle.
- A thin median fibrous septum divides the tongue into right and left halves.
- There are 2 types of muscles found within the tongue:

1) **Intrinsic muscles:** originate and insert within the tongue.

Action: change the tongue's shape.

2) **Extrinsic muscles:** originate from structures adjacent to the tongue and insert into the tongue.

Action: move the body of the tongue.

★ **Extrinsic muscles**

There are 3 muscles:

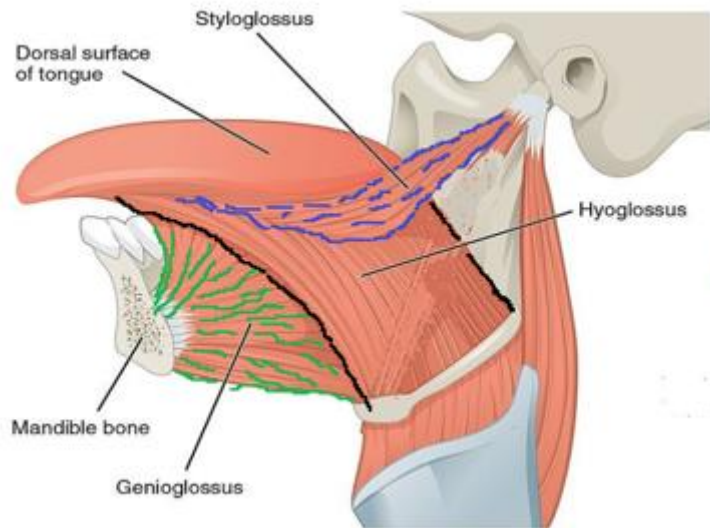
1- **Genioglossus muscle:** it has a fan shape.

Originates from the superior mental spine of the mandible and it is directed upward.

- Inserts into the posterior aspect of the tongue (along the entire length of the dorsum).
- Its action is to pull the dorsum of the tongue forward (protrude the tongue).

2- **Hyoglossus muscle:** it's quadrant in shape.

- Originates from the hyoid bone, directed upward and anteriorly.
- Inserts into the lateral aspect of the tongue.
- Its action is to pull the sides of the tongue downward, depress the dorsum and also help in the retraction of the tongue.



3- **Styloglossus muscle:**

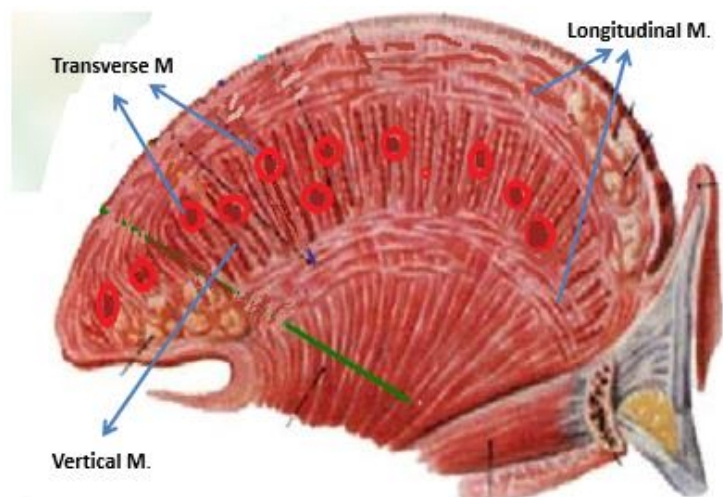
- Originates from the anterior aspect of the styloid process, passes downward and forward.
- Inserts into the lateral aspect of the tongue.
- It acts to draw up the sides of the tongue which helps for the swallowing, also helps in retraction of the tongue.

❁ **Intrinsic muscles**

- 1- **Longitudinal fibers:** they are distributed as superior and inferior bundles. Their action is to shorten the length of the tongue.

- 2- **Transverse fibers:** run horizontally at the right angles just below the superior longitudinal bundle. They act to narrow or broaden the tongue.

- 3- **Vertical fibers:** run from the dorsum of the tongue down to the inferior surface. They act to flatten and broaden the tongue.



✿ Nerve supply of the tongue

- **Motor nerve supply:** all muscles of the tongue (extrinsic + intrinsic) are supplied by the Hypoglossal N. (CN XII).
- **Sensory nerve supply:** the mucous membrane of the tongue is supplied by two types of fibers; **General sensation** and **special sensation** (taste).

1) General sensation:

a- The **lingual N.:** a branch of the mandibular nerve, it carries general sensation to the anterior two thirds of the tongue.

b- The **glossopharyngeal N. (CN IX):** carries general sensation to the posterior third of the tongue.

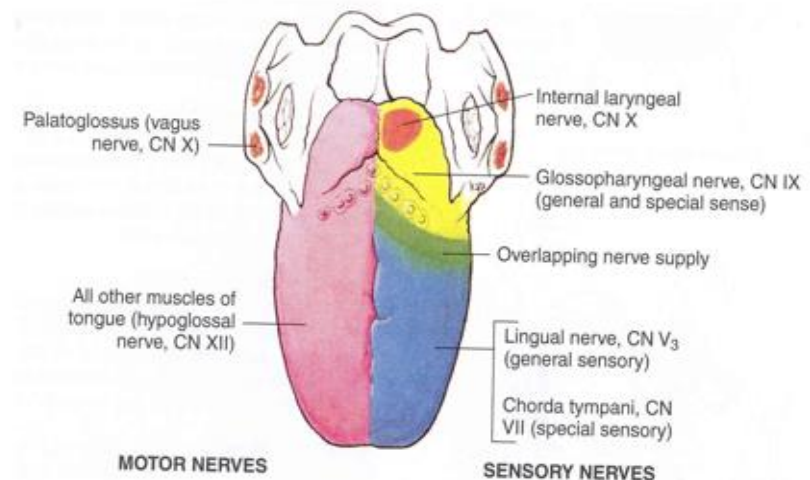
c- The **vagus N. (CN X):** carries general sensation to the area surrounding the epiglottis.

2) Special sensation:

a- The **facial N.:** through the chorda tympani, which conveys taste sensation to the anterior two thirds of the tongue.

b- The **glossopharyngeal N.:** carries taste sensation to the posterior one third of the tongue.

c- The **vagus N.:** carries taste sensation to the area surrounding the epiglottis.



✿ Blood supply

Through the **lingual artery** (branch of the external carotid artery). It gives:

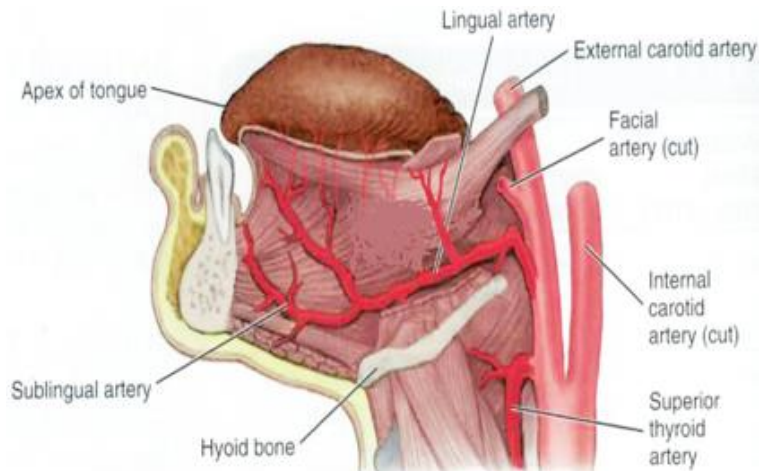
1 - **Dorsal lingual artery** : supply the root of the tongue.

2- **Sublingual artery:** supply the sublingual salivary gland and anastomosis with the submental artery of the facial artery.

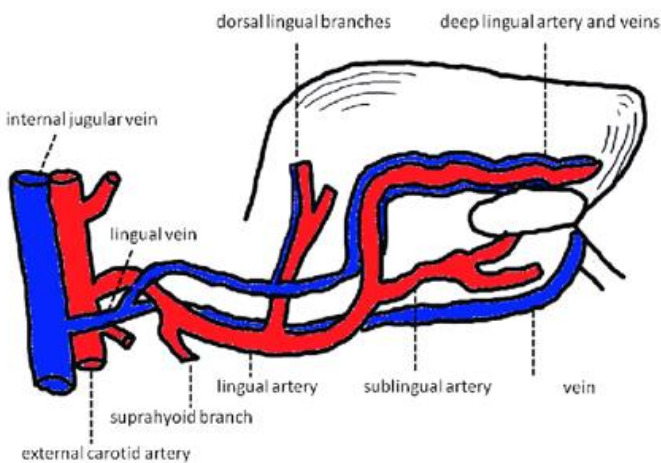
3- **Deep lingual artery:** as the lingual artery terminates near the lingual frenulum on the ventral surface of the tongue, it is called as the deep lingual artery.

Veins of the tongue:

The veins of the tongue are named similarly to the arteries that they accompany. As the deep lingual vein forms adjacent to the apex of the tongue, it courses along the ventral surface of the tongue (deep to the mucosa). As the deep lingual vein anastomosis with the sublingual vein, they become the lingual vein , which is usually empty into the internal jugular vein.



Lymphatic drainage of the tongue:



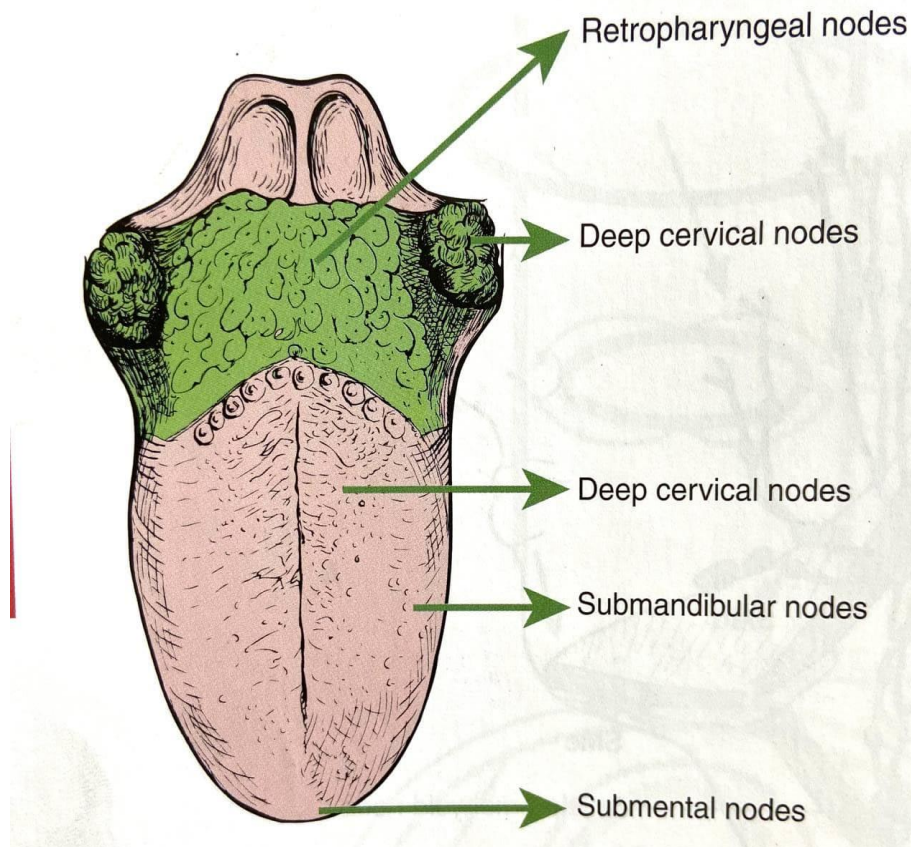
The tip of the tongue drains to **submental lymph nodes**.

The lateral aspect of the anterior two thirds drain into the **submandibular lymph nodes**.

The medial portion of the anterior two thirds drain into the **deep cervical lymph nodes**.

The posterior third drains posteriorly

to the *retropharyngeal lymph nodes*.



© **Clinical notes for tongue:**

- **The inflammation of the tongue is called “Glossitis”.**
 - **Any ulcer or lesion which fails to heal within one’s mouth should be considered to be malignant until proved innocent.**
- Injury to the hypoglossal nerve on one side results in paralysis of the tongue on that side and atrophy of its muscles. The tongue surface becomes wrinkled, and when protruded, it deviates to the injured side.
 - lingual nerve injury may be caused by: third molar removal, local anesthesia, implants.
 - Symptoms after an injury to the lingual nerve include the following:
 1. Numbing of the tongue and loss of general sensation to the anterior 2/3 of tongue and the floor of mouth.
 2. Loss of taste or altered taste of the anterior 2/3 of tongue.
 3. Decreased secretion of saliva.

4. A tingling or burning sensation in the tongue.
5. Impaired speech.
6. Damage of chorda tympani: Injury to the chorda tympani nerve leads to the loss (ageusia) or the distortion of taste from anterior 2/3 of tongue, and a decreased salivation which results to dryness of mouth (xerostomia).

Hypoglossal nerve injury:

Difficult third molar extractions and/or fractures of the mandible may damage the hypoglossal nerve (cranial nerve XII), causing paralysis of the tongue on the affected side. When the mouth is opened and the tongue is protruded, the genioglossus of the unaffected side will cause the tongue to deviate to the affected side. If the damage is prolonged, the tongue muscles will atrophy.

A wound of the tongue is often caused by the patient's teeth following a blow on the chin when the tongue is partly protruded from the mouth. It can also occur when a patient accidentally bites the tongue while eating, during recovery from an anesthetic, or during an epileptic attack. Bleeding is stopped by grasping the tongue between the finger and thumb posterior to the laceration, thus occluding the branches of the lingual artery.

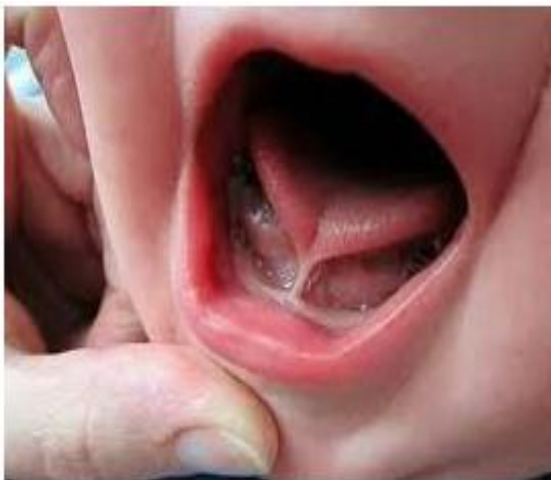© Congenital disorders

- Complete absence of the tongue – Aglossia.
- Short and incompletely formed tongue – Hypoglossia.
- Ankyloglossia (tongue-tie): refers to a condition in which the lingual frenulum that attaches the ventral surface of the tongue to the floor of the mouth is too short.
- The infant would be unable to protrude the tongue and some disorder may make breastfeeding. The frenulum tends to elongate over time. Some individuals may also present later in life with difficulties with articulation (disturbance of speech).
- The defect can be surgically corrected with a frenulectomy (surgical division of the frenulum).

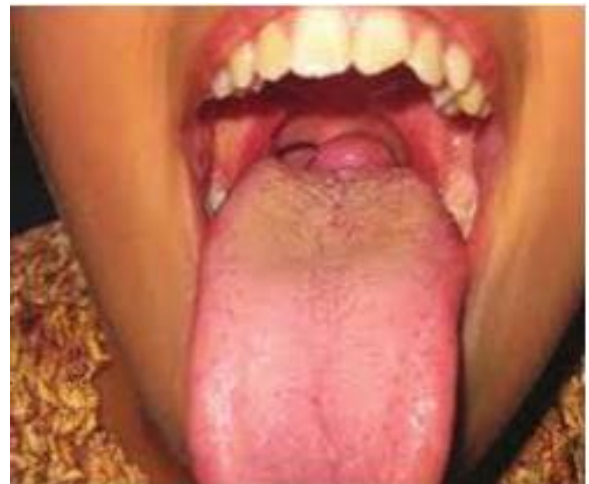© **Lingual thyroid gland** Ectopic thyroid glands at the base of the tongue have been classified as lingual thyroid glands. This is occurred when a part of or all of the thyroid gland fails to descend. Patients may experience obstructive symptoms (i.e. difficult swallowing, problems with phonation, and difficult breathing). Some patients are fortunate to remain asymptomatic.

© **Lingual cancer:**

Cancer of the tongue is the most common cancer of the oral cavity (36.2%). About 95% of the cancers located on the tongue and floor of the mouth are squamous cell carcinomas that are related with a history of high use of alcohol and tobacco.



Ankyloglossia (tongue-tie)



Lingual thyroid gland

FLOOR OF THE MOUTH (SUBLINGUAL SPACE)

The floor of the mouth is the space between the medial aspect of the mandible body above the mylohyoid line and the base of the tongue.

The sublingual space is V-shaped, with the apex pointing to the anterior.

Its boundaries are:

The mylohyoid muscle inferiorly.

The mucosa of the floor of mouth and the tongue superiorly.

The medial surface of the mandible anterolaterally.

The muscles along the base of the tongue (geniohyoid and genioglossus muscles) posteriorly.

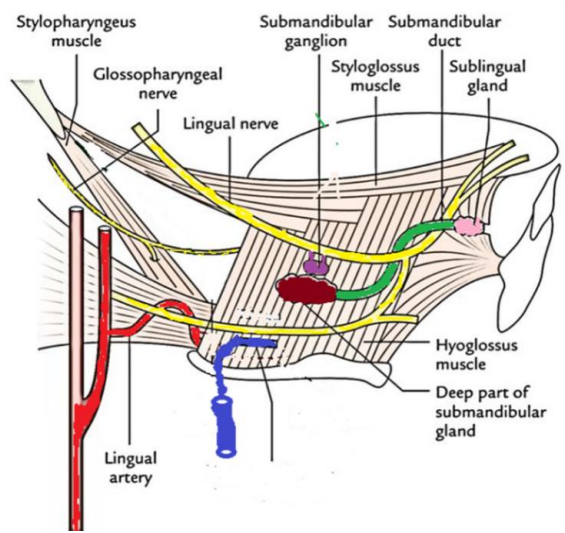
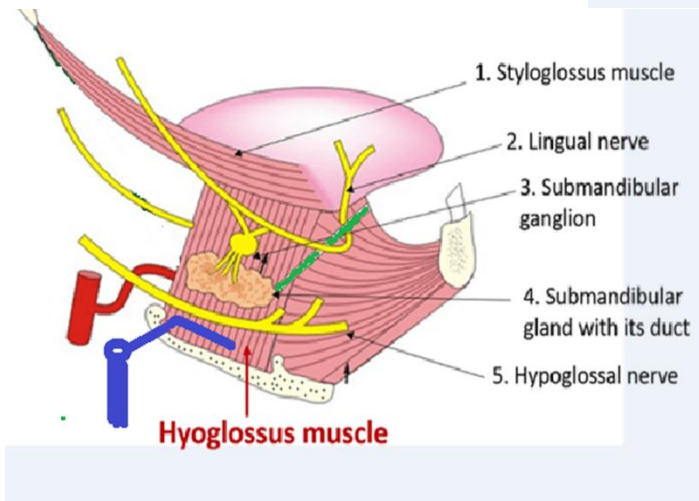
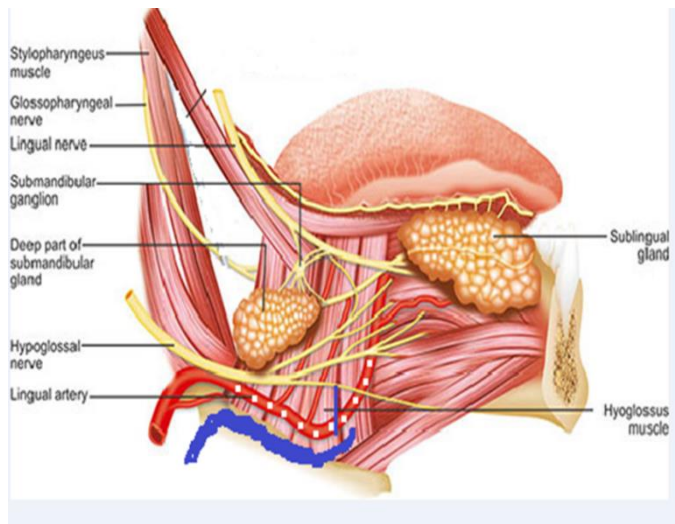
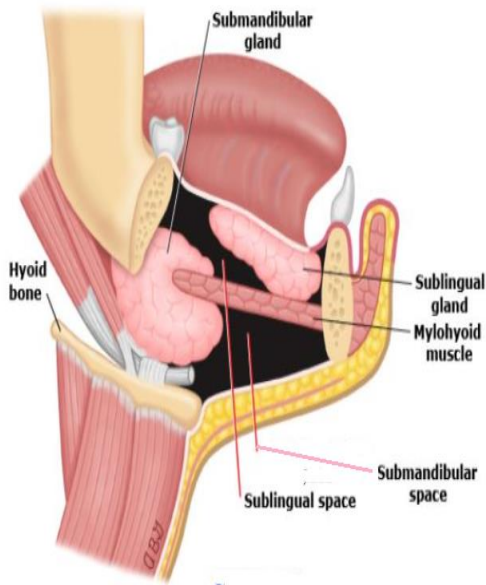
Inferiorly, the flat mylohyoid muscle limits the floor of the mouth and acts as a muscular diaphragm.

Superiorly, the contents of the floor are covered by a thin layer of mucosa.

The mucous membrane of the tongue continues with the mucous membrane of the floor of the mouth and in turn, this mucosa is reflected upward on the inner aspect of the mandible to end as lingual gingiva.

The sublingual space communicates posteriorly around the posterior free border of the mylohyoid muscle with the submandibular space.

- within the floor of the mouth, there is a number of important structures:
 1. Lingual nerve.
 2. glossopharyngeal nerve.
 3. Hypoglossal nerve.
 4. submandibular ganglion.
 5. Lingual artery.
 6. Deep part of submandibular gland.
 7. Sublingual gland.
 8. Lingual vein.



❁ **Lingual nerve**

- **Course:** the lingual nerve arises as a branch of the posterior division of the mandibular nerve, within the infratemporal fossa.
- It passes downward and forward to emerge between the medial and lateral pterygoid muscles. It joins at the point of the small chorda tympani branch of the facial nerve. The lingual nerve continues anteriorly and downward to enter the floor of the mouth just postero-inferior to the root of the mandibular third molar. In the floor of the mouth, it curves upward on the lateral surface of the hyoglossus muscle. The nerve ends by branches to the dorsum of the anterior two thirds of the tongue.

➤ **Branches:**

- 1) Two or more short ganglionic branches to the submandibular ganglion. the branches carry sensory and pre-parasympathetic fibers to the ganglion.
- 2) General sensory branches to the mucus of the anterior two thirds of the tongue.
- 3) Sensory branches to the floor of the mouth.

✳ **Submandibular ganglion**

- It is a small swelling which hangs by ganglionic branches from the lingual nerve, it receives pre-parasympathetic fiber from the facial nerve through the chorda tympani which joins the lingual nerve in the infratemporal fossa.
- The pre-parasympathetic fibers within the ganglion and the post parasympathetic fibers pass to supply the:
 1. Submandibular gland.
 2. Sublingual gland.
 3. Lingual gland (small gland within the tongue).
 4. Minor glands in the floor of the mouth.

✳ **Glossopharyngeal nerve (CN IX)**

- **Course:** It arises from the medulla oblongata and passes through the jugular foramen at the base of the skull. Here, it passes to the pharynx between the superior and middle constrictor pharyngeal muscles and continues forward to end into the posterior third of the tongue.
- Unilateral lesion of the glossopharyngeal nerve outside of the brainstem will cause loss of taste from the posterior one third of the tongue, loss of salivation from the parotid gland on the ipsilateral side, loss of gag reflex, and loss of carotid sinus reflex.

➤ **Branches:**

1. **Pharyngeal branches:** sensory branches to the mucus lining of the pharynx.
2. **Nerve to the stylopharyngeus muscle:** a single motor branch to this muscle.
3. **Glossal branches:** general and special sensation of taste buds of the posterior third of the tongue.

✿ Hypoglossal nerve (CN XII)

- **Course:** it arises from the medulla oblongata, exits through the hypoglossal canal and descends in the neck by crossing the carotid sheath and its contents. It curves anteriorly by crossing the occipital, internal carotid, external carotid and lingual arteries, and passes deep to the posterior belly of the digastric muscle to enter the sub mandibular triangle. It disappears by passing deep to the mylohyoid muscle to enter the floor of the mouth.

➤ Branches:

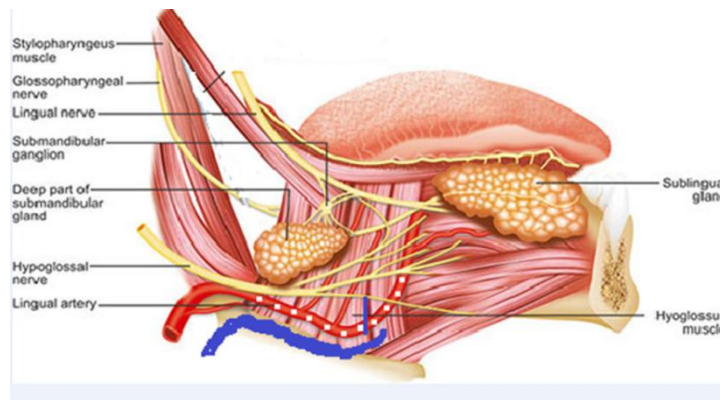
1. **superior root of Ansa cervicalis** (which contains fibers from the C1 spinal nerve). it leaves the hypoglossal nerve as the nerve loops anteriorly; the superior root continues downward in the neck to join the inferior root and form the Ansa cervicalis which in turn supplies the infrahyoid muscles.
2. **Nerve to the thyrohyoid and geniohyoid muscles** (these branches represent also the nerve fibers of the C1).
3. **Glossal motor branches** to the intrinsic and extrinsic muscles of the tongue.

Hypoglossal nerve injury:

Difficult third molar extractions and/or fractures of the mandible may damage the hypoglossal nerve (cranial nerve XII), causing paralysis of the tongue on the affected side. When the mouth is opened and the tongue is protruded, the genioglossus of the unaffected side will cause the tongue to deviate to the affected side. If the damage is prolonged, the tongue muscles will atrophy.

✿ Lingual artery

- It arises from the external carotid artery just above the tip of the greater horn of the hyoid bone, it enters the submandibular triangle by passing deep to the posterior belly of digastric muscle. Here, it passes deep to the hyoglossus muscle in the floor of the mouth.
- The artery has a somewhat tortuous course and it gives the following branches:
 - 1- **Dorsal lingual artery:** supplies the posterior end of the tongue.



2- **Sublingual artery:** supplies the sublingual gland.

3- **Terminal branch:** supplies the anterior two thirds of the tongue.

✿ **Submandibular gland**

➤ **The superficial part:**

- It lies below the mylohyoid muscle, below, it is separated from the skin by the superficial layer of the deep fascia and platysma muscles, and it is separated from the lower pole of the parotid gland by a thickening of deep fascia called stylomandibular ligament.
- The facial vein passes superficial to the gland while the facial artery passes deep to the gland.

➤ **The deep part:**

- It lies deep to the mylohyoid muscle, on the hyoglossus muscle. The lingual nerve runs above this part, while the hypoglossal nerve is located below this part. The deep part becomes continuous with the superficial part behind the free edge of the mylohyoid muscle.

➤ **The duct of the submandibular gland**

- It is also called Wharton's duct. It extends from the deep part of the gland; it passes forward and upward on the hyoglossus and then on the genioglossus muscles. The terminal part of the duct lies between the genioglossus muscle and the sublingual gland (in this portion, it's crossed twice by lingual nerve).
- The duct opens beneath the tongue on the floor of the mouth at the summit of a small sublingual papilla, a short distance behind the lower incisor teeth. It is about 5 cm in length and 3 mm in diameter.

- **Calculus Formation** :the submandibular salivary gland is a common site of calculus formation. This condition is rare in the other salivary glands. The presence of a tense swelling below the body of the mandible, which is greatest before or during a meal and is reduced in size or absent between meals, is diagnostic of the condition. Examination of the floor of the mouth will reveal absence of ejection of saliva from the orifice of the duct of the affected gland. Frequently, the stone can be palpated in the duct, which lies below the mucous membrane of the floor of the mouth.

➤ **Nerve and blood supply:**

- By postganglionic fibers from the submandibular ganglia. Glandular branches from the facial artery supply the gland.

-

✱ **Sublingual gland**

- It is the smallest salivary gland, lies on the mylohyoid muscle between the mandible and genioglossus muscle. It raises the mucous membrane covering its superior surface to form the sublingual fold.

- The right and left glands meet anteriorly above the origin of the genioglossus muscle(horseshoe configuration around the lingual frenulum) .

- About 12 small ducts (ducts of Rivinus) empty directly upward through the sublingual fold to the oral cavity. Some ducts may unite to form the sublingual duct (duct of Bartholin), opening into the submandibular duct.

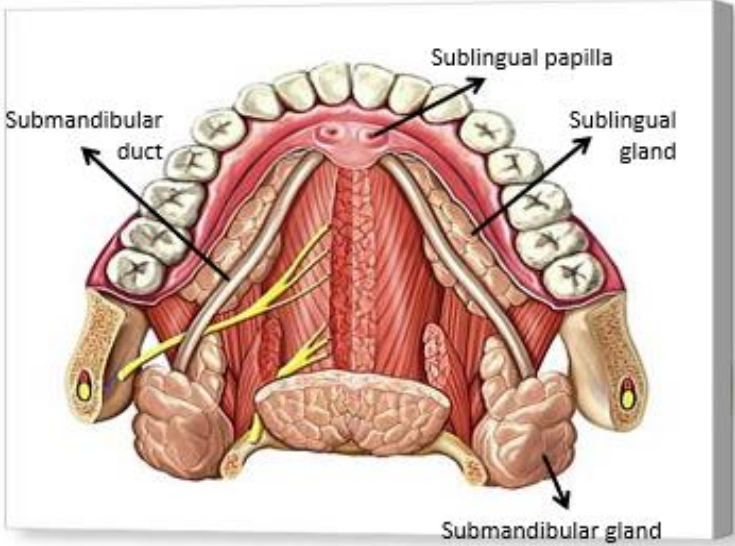
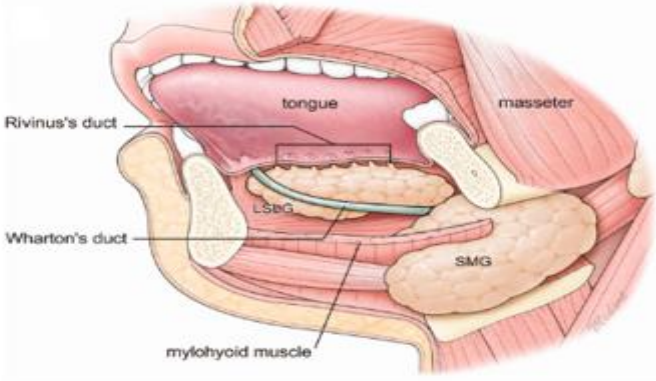
➤ **Nerve and blood supply:**

- Like the submandibular gland, it receives post ganglionic fibers from the submandibular ganglia. The blood supply is from the sublingual artery, a branch from the lingual artery and submental artery from facial artery.

The sublingual artery, occasionally injured during dental procedures, may present problems to the surgeon attempting to ligate its source because it may arise from the submental branch of the facial artery rather than from the lingual artery.

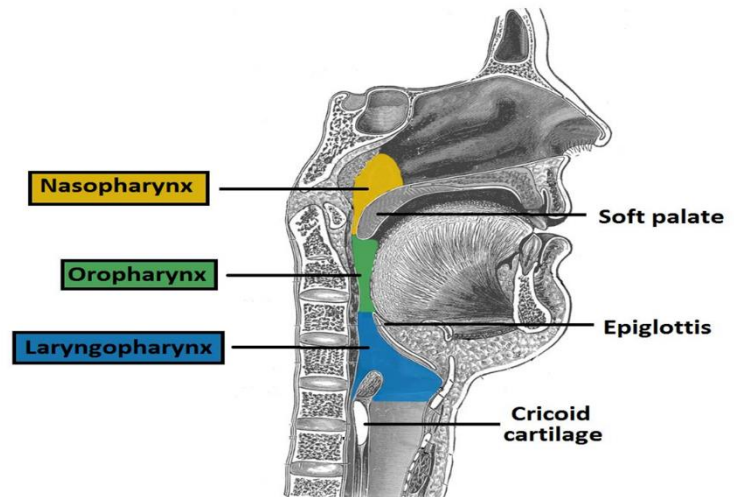
The sublingual salivary gland, which lies beneath the sublingual fold of the floor of the mouth, opens into the mouth by numerous small ducts. Blockage of one of these ducts is believed to be the cause of cysts under the tongue.

Submandibular and sublingual salivary glands



PHARYNX

- The pharynx (throat) is a muscular fibrous tube, extending from the base of the skull superiorly to the esophagus at the level of the cricoid cartilage, it is anterior to the bodies of the six cervical vertebrae.
- Anteriorly, its cavity communicates, from superior to inferior, with the nasal cavity, the oral cavity and the laryngeal cavity.
- The pharynx is divided into three parts on the basis of its communication with the nasal cavity, oral cavity and laryngeal cavity, the nasal pharynx is respiratory in function, the oral pharynx is both respiratory and alimentary and the laryngeal pharynx is also both respiratory and alimentary.
- The average length of the pharynx is about 12 cm, it is wide at the nasal pharynx, with little constriction at the junction with oral pharynx and another narrowing
- at the junction of the oral and laryngeal pharynx.



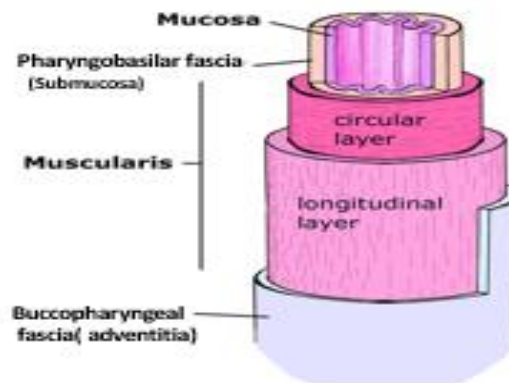
© teachmeanatomy
The #1 Appointed Human Anatomy Site on the Web.

- 1- Passageway for air and food-as studied earlier, the pharynx works for both respiratory and digestive system, as air passes through the nasal and oral cavities while food passes through oral and laryngeal sections
- 2- Warming and humidifying-as the air passes towards the lungs it is warmed and humidified from all the regions that it crosses
- 3- Hearing-the auditory tube extends from the nasopharynx to each middle ear and allows the air to enter the middle ear. this makes the air in the middle ear be at the same pressure as in outer ear in order to protect the eardrum
- 4- Protection-the pharyngeal and laryngeal tonsils present produces antibodies against the swallowed or inhaled unwanted particle
- 5- Speech-the pharynx act as a resonating chamber for sound towards the larynx. It also helps along with sinuses of nasal cavity to give voice its individual characteristics.

✿ Walls of the pharynx

The pharyngeal walls contain four basic layers:

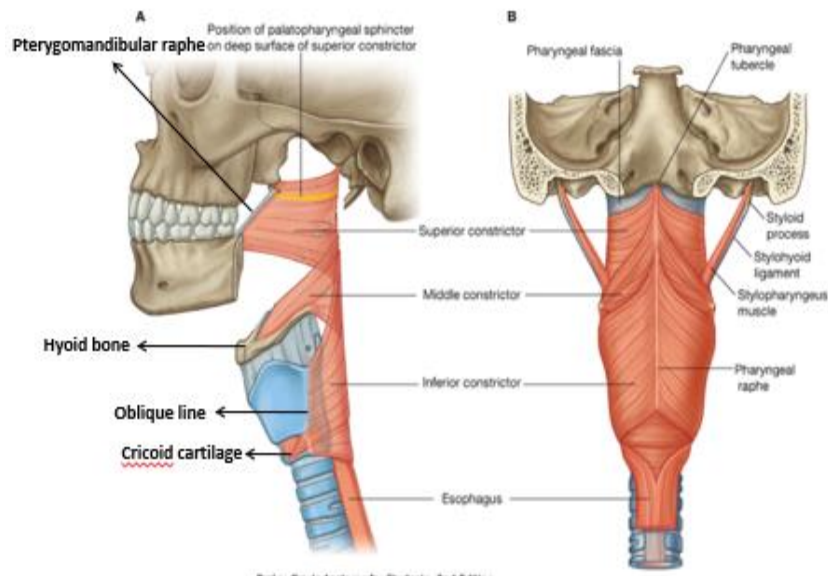
- 1- **Adventitia (or) the buccopharyngeal fascia:** in this fascia there is pharyngeal plexus of veins and nerves.
- 2- **Muscular coat:** consists of five pairs of muscles, outer semicircular layer and two inner longitudinal muscles.
- 3- **The submucosa or pharyngobasilar fascia:** It is a fibrous coat, which attaches the pharynx to the base of the skull.
- 4- **Mucosa.**



✿ Muscles of the pharynx

A) Semicircular Constrictor muscles

- 1- **Superior constrictor muscle:** it arises from the pterygomandibular raphe, medial pterygoid plate and mylohyoid line of the mandible. The muscle fibers are directed posteriorly and turned medially to meet their opposite muscle in a midline in the pharyngeal raphe. Superiorly, the pharyngeal raphe is attached to the pharyngeal tubercle at the base of the skull.
- 2- **Middle constrictor muscle:** it arises from the greater & lesser horns of the hyoid bone and from the lower part of the stylohyoid ligament. The fibers sweep posteriorly and medially to join their opposite muscle at the median pharyngeal raphe, the fibers of the middle constrictor muscle partially overlap the superior constrictor muscle above
- 3- **Inferior constrictor muscle:** It arises from the side of the cricoid cartilage and the oblique line of the thyroid cartilage. The fibers sweep posteriorly and medially to meet fibers of the opposite muscle in the midline pharyngeal raphe



- **Function:** during the act of swallowing, the constrictor muscles contract as peristaltic waves from superior to inferior.
- **Nerve supply:** pharyngeal plexus of the glossopharyngeal and vagus nerves.

B) Longitudinal muscles

- 1- **Salpingopharyngeus muscle:** few fibers arise from the mouth of the auditory tube as “Salpingopharyngeus muscle” and pass inferiorly to insert into the posterolateral aspect of the pharynx.
 - 2- **Stylopharyngeus muscle:** it originates from the medial aspect of the styloid process and passes medially and inferiorly through the gap between the superior and middle constrictors to insert into the posterolateral wall of pharynx.
- **Function:** the two muscles act to raise the pharynx and larynx during the act of swallowing.
 - **Nerve supply:** from the pharyngeal plexus (glossopharyngeal and vagal complex).

✿ Pharyngeal gaps

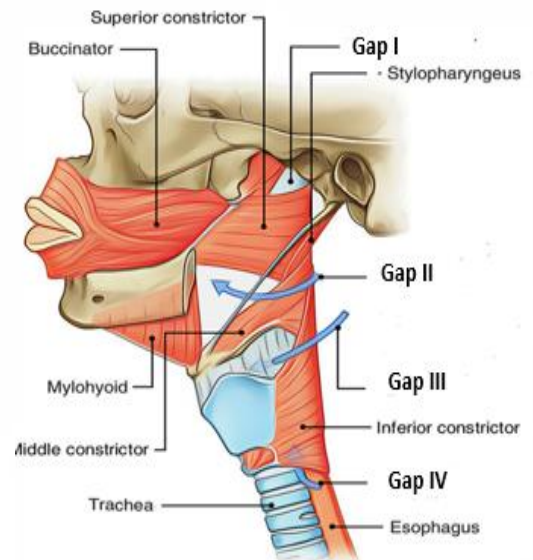
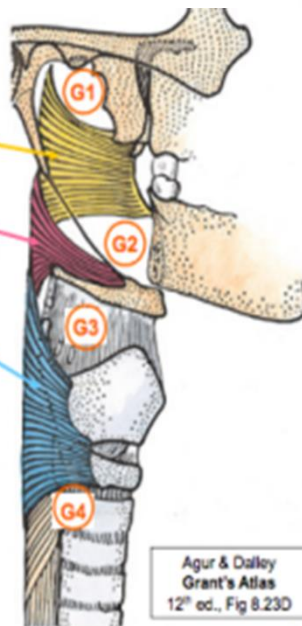
The superior and inferior borders of the constrictor muscles form four gaps through which several structures pass:

- **Gap 1:** is located between the base of the skull and the sup. const. muscle, passing through this gap, the auditory tube, the Levator palatine muscle.
- **Gap 2:** is located between the sup. Const. muscle & the middle const. muscle, passing through this gap, stylopharyngeus muscle, and glossopharyngeal nerve.
- **Gap 3:** located between the middle & inferior const. muscles and it transmits the internal laryngeal branch of vagus and the superior laryngeal branch of the superior thyroid artery.

Pharyngeal Constrictors:

- Superior
- Middle
- Inferior

- 3 voluntary muscles comprise an outer "circular" layer
- Overlap posteriorly to form one continuous sheath.
- Anterior attachments (origins) are not continuous; there are 4 gaps above, between, and below the muscles.



- **Gap 4:** is located between the inferior const. M. and the esophagus, passing through this gap, the recurrent laryngeal nerve and the inferior laryngeal branch of the inferior thyroid artery.

Interior of the pharynx:

The interior of the pharynx is lined by mucosa and divided into 3 functional areas:

- 1- Nasopharynx
- 2- Oropharynx
- 3- Laryngopharynx

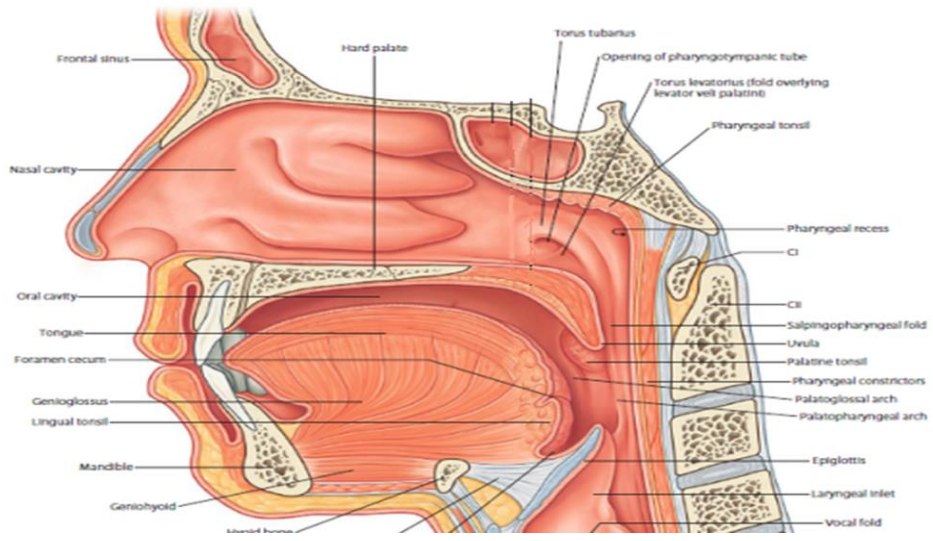
I- Nasopharynx

- It is the superior portion of the pharynx lying above the soft palate, it communicates with the nasal cavity anteriorly through the choanae.
- The nasopharyngeal cavity opens into the cavity of the oropharynx through the pharyngeal isthmus, which lies between the posterior free border of the soft palate and the posterior pharyngeal wall.

■ Features:

- 1- **Pharyngeal orifice of the auditory tube:** bulges out into the lateral wall of the nasopharynx about 1.5 cm behind the inferior concha. It is bounded superiorly and posteriorly by rounded tubal ridge (elevation) around which lies the tubal tonsil. The tubal ridge is caused by the projecting cartilage of the auditory tube.
- 2- **Salpingopharyngeal fold:** Consists of a small muscle with mucous membrane. The fold continues inferiorly from the posterior aspect of the tubal ridge and blends with the lateral wall of the nasopharynx.
- 3- **Pharyngeal recess:** it is a vertical cleft between the salpingopharyngeal fold and the posterior wall of the pharynx.
- 4- **Pharyngeal tonsil:** is a collection of nodular lymphoid tissue found on the superoposterior wall of the nasopharynx, which are often clinically referred to as the **adenoids** when enlarged.

Adenoids is the term that commonly refers to the pathologic state when the pharyngeal tonsil becomes hypertrophied due to infection. Excessive hypertrophy partially (or completely) blocks the posterior choanae, necessitating mouth breathing and causing nasal speech and loud snoring during sleep. Persistent inflammation and infection of the pharyngeal tonsil may lead to spreading of the infection into the internal auditory tube, resulting in otitis media, with subsequent temporary or permanent hearing loss. Adenoidectomy is the treatment of choice for hypertrophied adenoids with infection.



II- Oropharynx

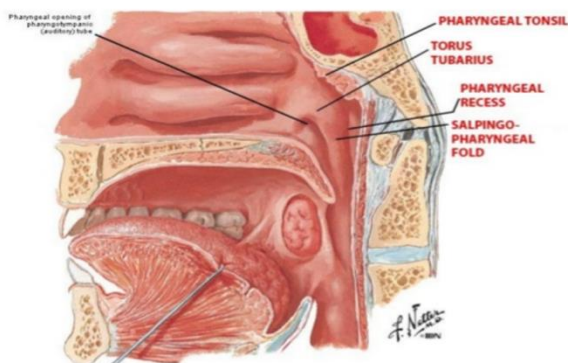
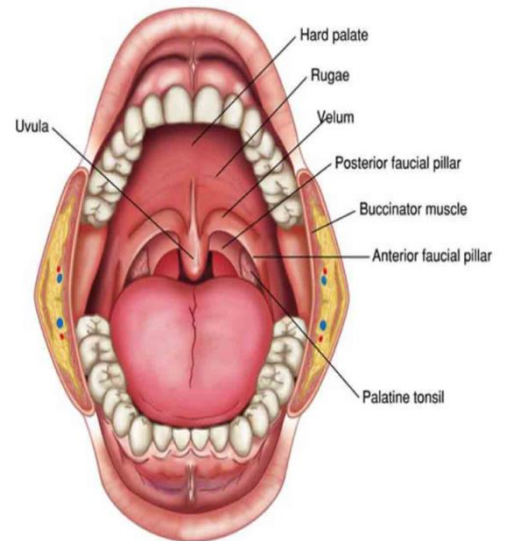
- It lies below the soft palate and communicates anteriorly with the oral cavity.

■ Features

1- **The anterior and posterior pillars:** They are two folds of mucous membrane extending laterally and inferiorly from the soft palate.

The more anterior fold is the palatoglossal arch running down to the lateral aspect of the tongue.

This fold is formed by muscle of the same



name (palatoglossus) covered by mucous membrane.

The posterior fold runs from the soft palate to the lateral wall of the pharynx as the palatopharyngeal arch, which is formed by muscle (Palatopharyngeus muscle) covered by mucous membrane.

- 2- **Palatine tonsils:** They are rounded lymphoid tissues covered by mucous membrane. Each one is located in the triangular fossa (tonsillar sinus) between the anterior & posterior pillars (palatoglossal and palatopharyngeal arches) . Its size is variable but it is generally large during childhood and begins to atrophy after puberty.

The blood supply of the palatine tonsil is from tonsillar branches of the ascending palatine artery of the facial A.

Other tonsillar branches arise from the dorsal lingual artery, lesser palatine artery and ascending pharyngeal artery.

Venous drainage is by way of the tonsillar plexus of veins on the deep aspect of the tonsil, a tributary of the pharyngeal venous plexus, and the facial vein.

Sensory innervation to the palatine tonsil is from the glossopharyngeal nerve and the lesser palatine branches of the maxillary nerve.

The palatine tonsils of a child are much larger than those of an adult. They are prone to infection because they tend to accumulate debris in the tonsillar crypts producing the characteristic sore throat and pyrexia. The deep cervical lymph node situated below and behind the angle of the mandible, which drains lymph from this organ, is usually enlarged and tender. Frequent tonsillitis may indicate the need for tonsillectomy, a relatively minor surgical procedure in children. However, the proximity of the tonsils to the common carotid artery and the rich vascular supply of the tonsils necessitate extreme care in the procedure. Moreover, the glossopharyngeal nerve as well as an unusually tortuous internal carotid artery may also be vulnerable to injury

- 3- **Epiglottis:** it is a leaf-like elastic cartilage structure, which guards the oral opening into the larynx. (completely discussed in the larynx).

- 4- **Glossoepiglottic folds:** They are three folds(glossoepiglottic folds) of mucous membrane that run anteriorly from the epiglottis to the base of the posterior third of the tongue, there is a median fold and two lateral folds on either side.

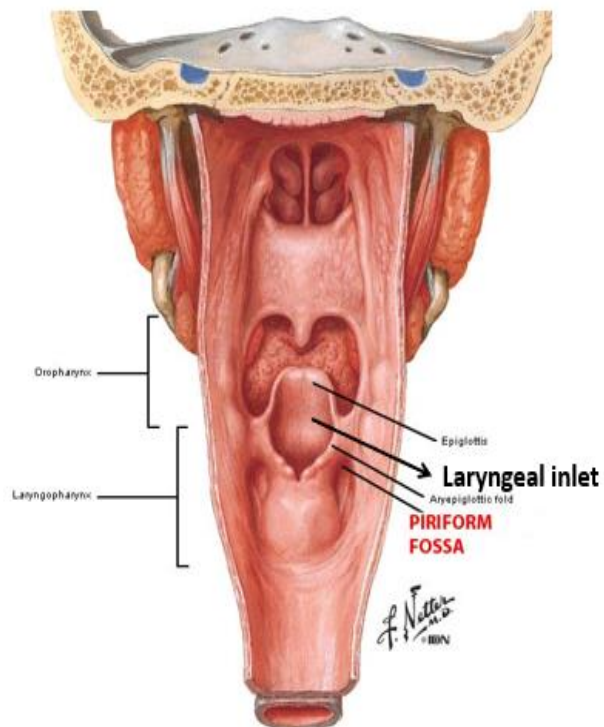
5- **Valleculae (piglottic vallecula)** : They are two small depressions formed by three folds. They lie on either side of the median glossoepiglottic fold.

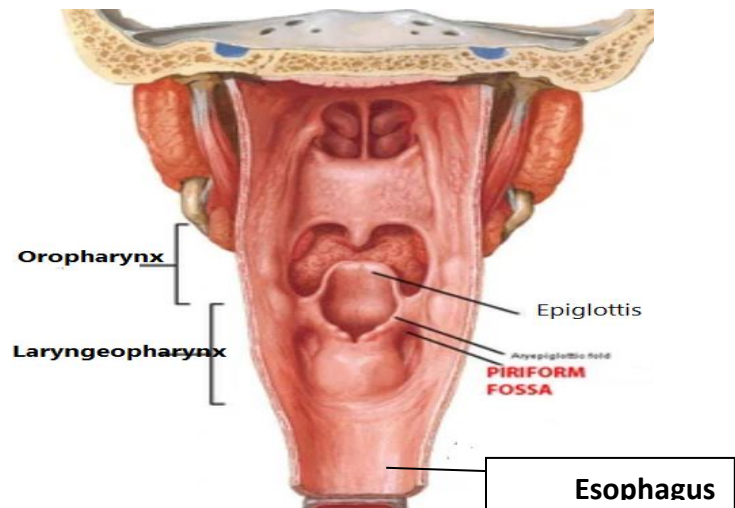
((Waldeyer's ring(tonsillar cycle) is the ring of lymphoid tissue in the naso- and oropharynx formed by the paired palatine tonsils, tubal tonsils the adenoid tonsils and lingual tonsil. It contains lymphocytes (a type of immune cell) that help the body fight infection and disease)).

III- Laryngeal pharynx

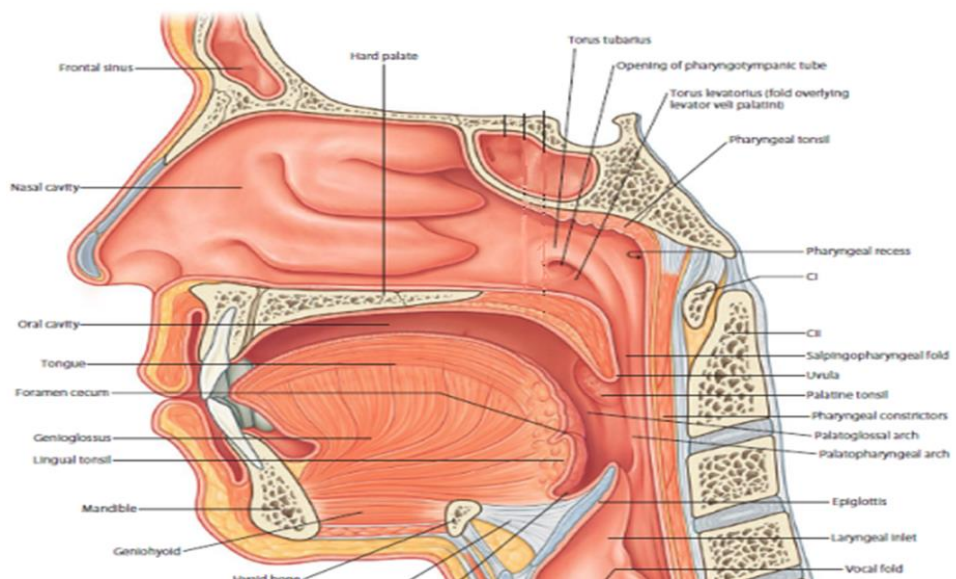
The larynx projects upward into the pharynx, and that part of the pharynx adjacent to the larynx is called the laryngeal pharynx, the laryngeal pharynx ends inferiorly at the level of C6 vertebra into the esophagus. The posterior and lateral walls of the laryngeal pharynx are formed by the middle and inferior constrictor muscles, while the anterior wall is formed by the:

- 1) The inlet of the larynx.
- 2) Mucous membrane of the posterior surface of the larynx.
- 3) Pyriform recess: it is a vertical gutter on the lateral wall of the laryngeal pharynx. It lies between the lateral glossoepiglottic fold and the side wall of the pharynx and continues downward on either side of the larynx as a blind pocket.





The laryngopharynx, specifically the piriform recess, is a common site for lodging of sharp objects, such as chicken and fish bones. The presence of foreign material in this region causes gagging, and the person is unable to remove the irritant. Care must be exercised in working in the piriform recess, for deep to the mucous membrane is the internal laryngeal nerve, which may be damaged during probing procedures.



✿ Arteries

The pharynx receives a very rich anastomosing blood supply from various sources:

- 1- Ascending pharyngeal branch of the external carotid artery.
 - 2- Superior thyroid branch of the ext. carotid artery.
 - 3- inferior thyroid branch from the thyrocervical trunk of subclavian artery.
- In addition, the soft palate and the tonsillar area are supplied by the facial and maxillary arteries.

✿ Veins

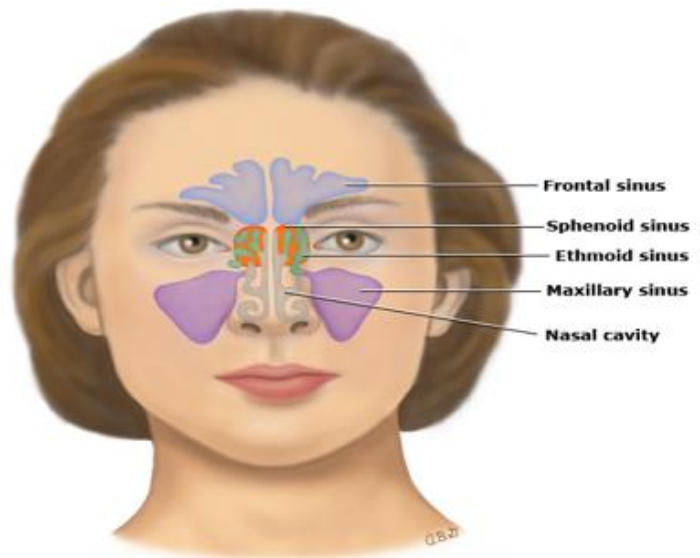
The veins draining the pharyngeal wall and the soft palate form a plexus within the buccopharyngeal fascia. The plexus forms a pharyngeal vein which joins the internal jugular vein deep to the angle of the mandible. The pharyngeal plexus also communicates anteriorly with the pterygoid plexus of veins.

PARANASAL SINUSES

The sinus develops as out-pouching of the embryonic nasal cavity and with increasing age, the cavities expand into the adjacent bones.

They are bilateral structures unequal in size and lined by a continuation of the nasal mucosa (ciliated columnar epithelium).

They cause lightening of the bones, resonance to the voice and cleaning of the nasal passages by secreting fluid.



The functions of the paranasal sinuses are:

- 1- Decreasing the relative weight of the skull.
- 2- Increasing the resonance of the voice.
- 3- Providing a buffer against facial trauma.
- 4- Humidifying and heating inspired air.
- 5- Cleaning the nasal passages by secreting fluid.
- 6- Immunological defense

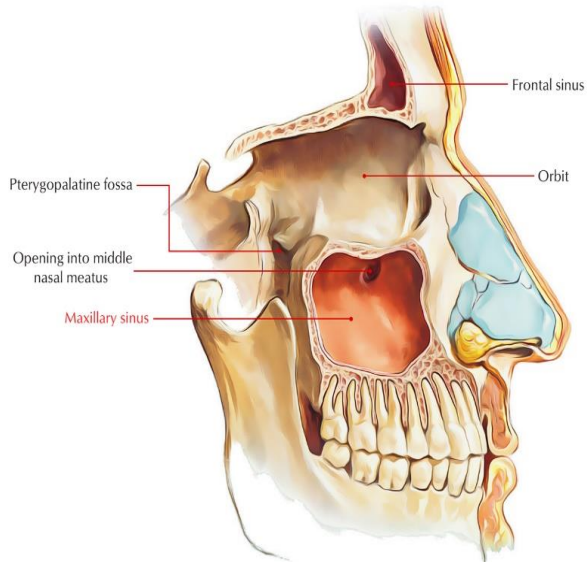
- There are 4 paired sinuses in humans.
- They are all in line with pseudostratified columnar epithelium.
- They are unequal size.

1- The maxillary sinus (Antrum):

(Largest of the paranasal sinuses, located under the eyes in the maxillary bones) Occupies the body of the maxillary bone and it may extend into the zygomatic bone. The roof is separated from the orbital cavity by the plate of maxilla. The floor is closely related to the apices of molar teeth or premolars. The sinus is about 35mm (width), 30mm (length) and 35mm (height). The anterior wall is bounded by the facial surface of maxilla, while the posterior wall is related to the pterygopalatine fossa.

The medial wall is bounded by the nasal surface of the body of maxilla and by parts of the palatine, lacrimal and ethmoid bones.

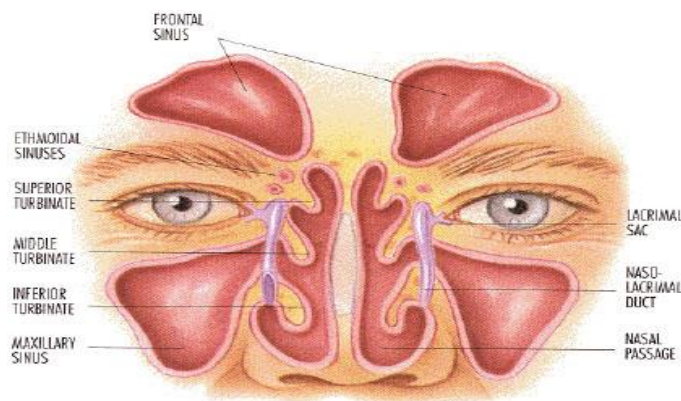
Nerve supply is from superior alveolar nerve.



2- Frontal sinuses:

These occupy the frontal bone above the superior orbital margin. They extend upward in the forehead region and backward in the roof of the orbital cavities to different degree. Each sinus is separated from its neighbor by a septum, which is usually oblique.

Nerve supply is from supraorbital nerve.



3- Ethmoidal sinuses:

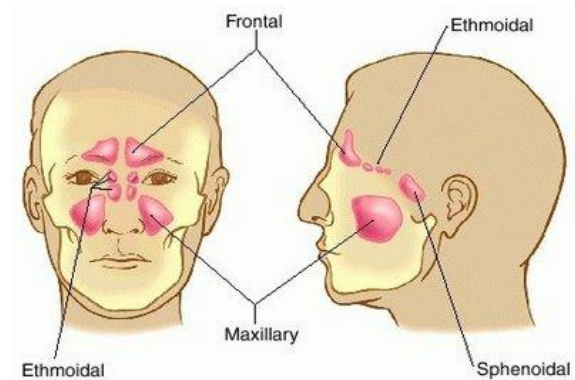
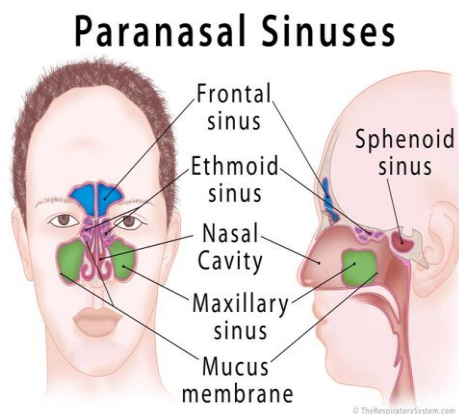
These are a group of small cavities or air cells lying within the facial part of the ethmoid bone and they are closely related to the medial wall of the orbital cavity and the floor of the anterior cranial fossa on either side of the cribriform plate.

They are divided into 3 groups; anterior, middle and posterior groups.

4- Sphenoidal sinuses:

These occupy the body of the sphenoid bone and may extend for some distance into the greater wing. They are bilateral but vary in size and the septum between the sinuses is usually asymmetrical.

Nerve supply: the sphenoidal and ethmoidal sinuses are supplied by the ethmoidal branches of the ophthalmic nerve.



Oroantral Communication (OAC) : •

The roots of the maxillary molars bulge into the floor of the maxillary sinus but normally do not perforate the mucus membrane of the sinus. •

Extreme care must be given when extracting the maxillary molars

because a fractured root may be driven into the maxillary sinus, forming a communication between the oral cavity and the maxillary sinus and thus

increasing the chance of sinus infection.

Sinusitis: •

Sinusitis, or inflammation of the mucosa of the paranasal sinuses, results in swelling of the mucoperiosteum, which blocks the ostia of the sinuses. This irritation causes accumulation of mucus in the sinuses, resulting in increased pressure and displacement of the air normally located therein. This pressure causes “sinus headaches” of varied intensity, and, if untreated, the infection may spread to the inner ear and the middle ear as well as to other areas. Infection of the frontal sinus, if left untreated, may result in frontal bone osteomyelitis because venous drainage of this sinus is intimately related to diploic veins and indirectly related with those of the dura and scalp. The ethmoidal air cells are in close relationship with the orbit, with only a paper-thin lamina of bone separating these structures. Hence, in cases of severe infection, this bony separation may be perforated and the infection may involve the orbit, resulting in orbital cellulitis. The maxillary sinus is prone to infection because it is intimately associated with the first and second maxillary molars. Dental involvement may result from abscess, from carious lesions, or from tooth extractions with part of the floor of the maxillary sinus being removed in the process. •

NASAL CAVITY

The nasal cavity is a chamber consisting of bony walls covered with respiratory pseudostratified ciliated columnar epithelium.

The cavity has a floor, roof, two lateral walls and a midline partition or septum of bone and cartilage that divides the nasal cavity into right and left portions.

Posteriorly, the nasal cavity communicates with the nasopharynx through the posterior nasal apertures or choanae.

The nasal cavity is about 6 -7 cm in length (anteroposterior) and 2 cm wide inferiorly and 0.5 cm superiorly.

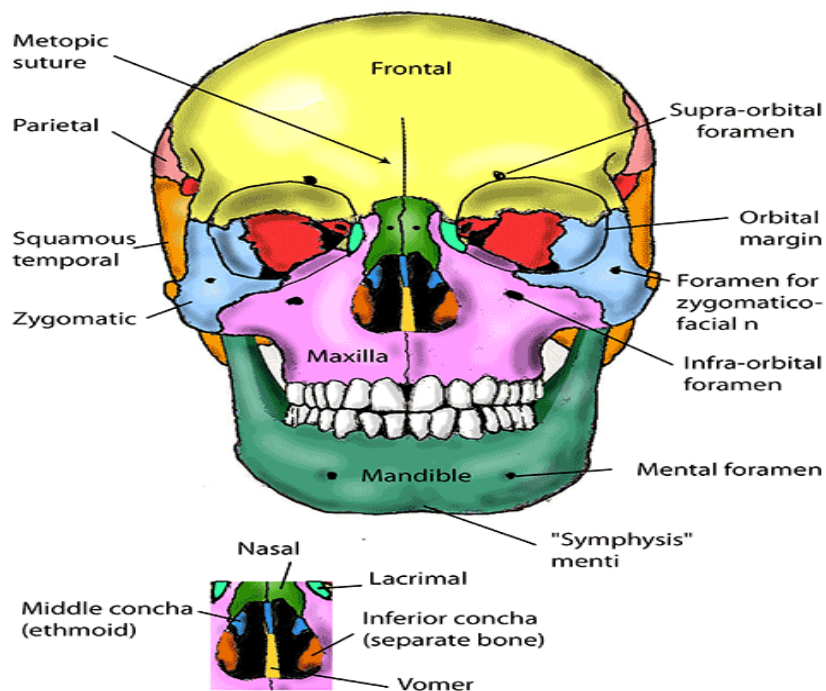
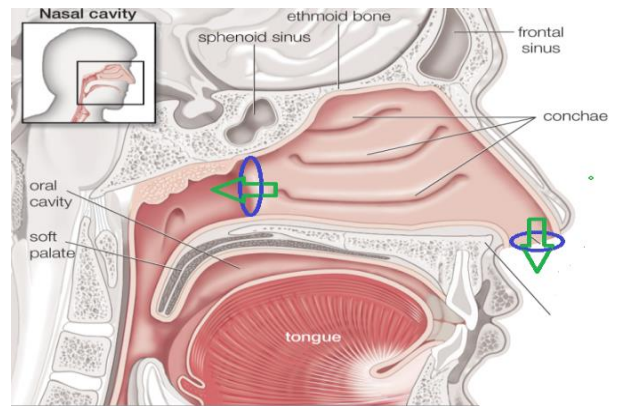
- The functions of the nose and nasal cavity are:

- 1- Respiration.
- 2- Olfaction.
- 3- Filtration.
- 4- Air condition of inspired air.
- 5- Reception of secretions from the paranasal air sinus and nasolacrimal duct of the orbit.

✿ Relationships

- **Superior:** the nasal cavity is separated from the anterior cranial fossa above by the perforated cribriform plate. Lying on the cribriform plates are the olfactory bulbs, which in turn receive filaments of the olfactory nerve from mucosa of the roof of the nasal cavity.
- **Lateral:** lateral to the upper half of the lateral wall of the nasal cavity is the ethmoidal air sinus, and lateral to the ethmoid sinus is the medial wall of the orbit. Lateral to the lower half of the lateral nasal wall is the maxillary air sinus.
- **Inferior:** below the floor of the nasal cavity is the oral cavity. The hard palate forms a common partition separating the oral cavity below from the nasal cavity above.
- **Posterior:** behind the nasal cavity and beyond the choanae is the nasopharynx.

- Anterior: the nostrils lead inward to the dilated area termed “the vestibule” which is lined by skin



✿ Boundaries

- Floor:

The floor of the nasal cavity is the hard palate. The palatal processes of the maxilla contribute to the anterior two thirds, and the palatal processes of the palatine bone contribute to the posterior third. The floor is convex in a mediolateral direction.

Roof

From anterior to posterior, the roof is formed by the nasal bones, the nasal spine of the frontal bone, the cribriform plate of the ethmoid bone and the anterior and inferior aspects of the body of the sphenoid bone.

-
-
-

- **Lateral wall:**

The bony composition of the lateral wall is complicated, with many bones contributing in part. These include the nasal bone, maxilla, ethmoid bone, palatine bone and inferior concha.

- **The conchae (Turbinates) :**

Three elevations arise from the lateral wall as fragile scrolls of bone covered by mucous membrane. The superior and middle conchae are medial extensions of the ethmoid bone. The large inferior concha is a separate bone attached to the lateral wall.

- **The meatuses:**

The space below each concha is termed as a meatus. Below the inferior concha is the inferior meatus, below the middle concha is the middle meatus and below the superior concha is the superior meatus.

The space above and behind the superior concha is the sphenoidal recess in which the sphenoidal sinus opens into its posterior part.

➤ **The superior meatus:** it is a narrow fissure and the posterior ethmoidal cells open into its anterosuperior part by one or more orifices.

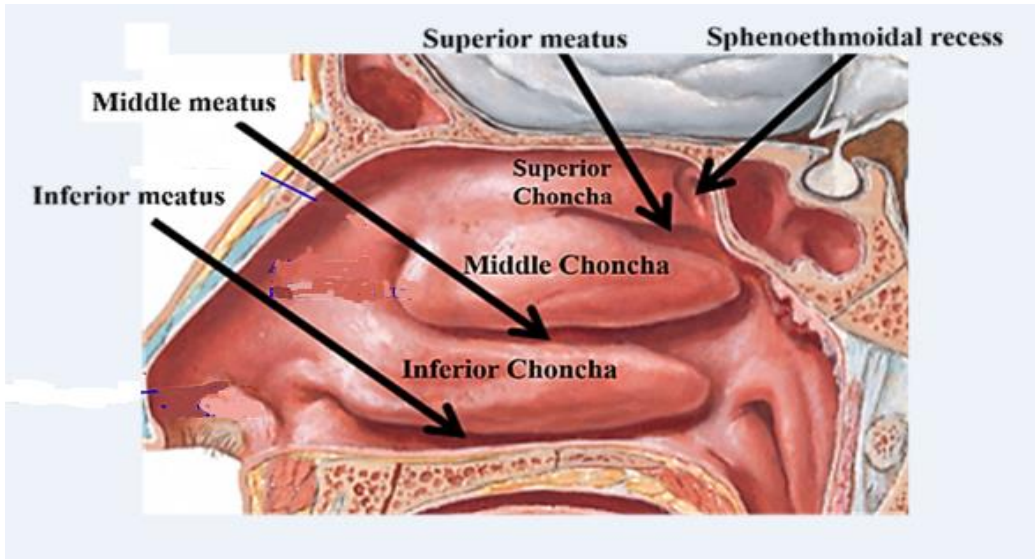
➤ **The middle meatus:** it is much longer and deeper than the superior meatus. The anterosuperior part of this meatus leads into a funnel-shaped opening known as the infundibulum, which leads to the frontal sinus.

On the lateral wall of the middle meatus is a deep curved groove which begins behind the infundibulum and runs posteriorly and inferiorly, this is known as the “hiatus semilunaris”, the anterior ethmoidal and the maxillary sinuses open into it.

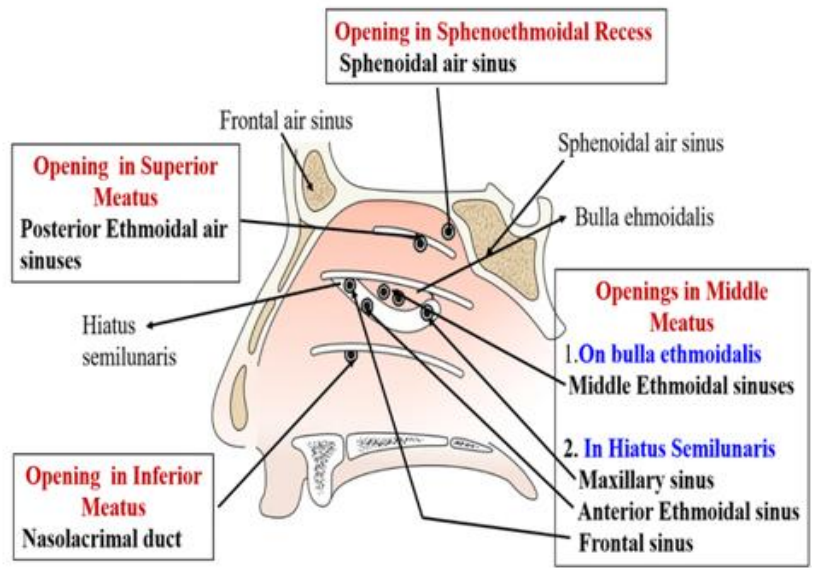
The opening of the maxillary sinus lies in the posterior part of the hiatus semilunaris.

The upper margin of the hiatus semilunaris is formed by a prominent bulge known as “bullae ethmoidalis” on which is the opening of the middle ethmoidal cells.

➤ **The inferior meatus:** The nasolacrimal duct opens into the anterior part of this meatus close to the attached border of the inferior concha.

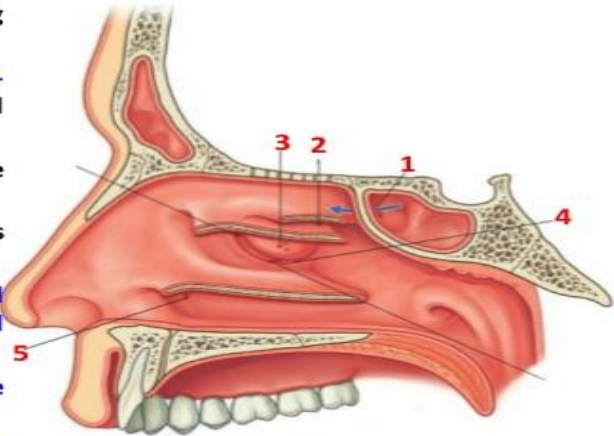


Opening in the lateral wall



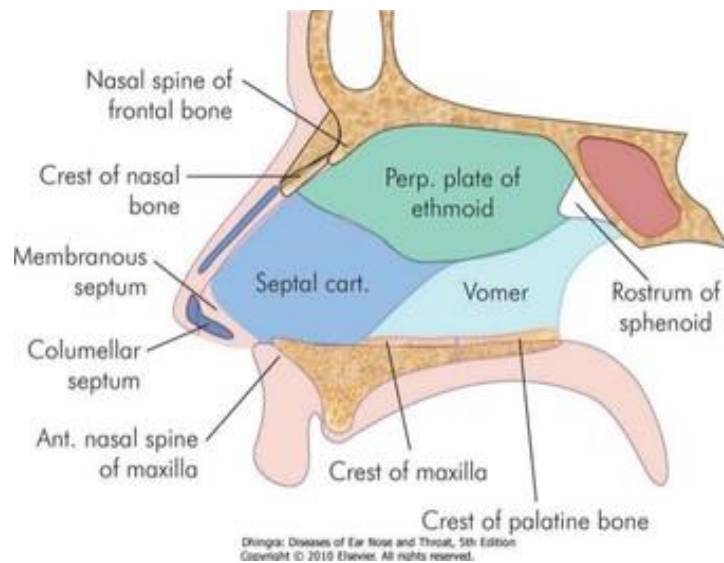
Openings in roof and lateral wall

1. **Spheno-ethmoidal recess** :- opening for the sphenoid sinuses
2. **Lateral wall of superior meatus** :- opening for the posterior ethmoidal cells
3. **Ethmoidal bulla** :- opening for the middle ethmoidal cells
4. **Semilunar hiatus** contains openings for :-
 - **Frontonasal duct** : drain the frontal sinuses and anterior ethmoidal sinuses
 - **In the floor of semilunar hiatus there is opening for maxillary sinuses**
5. **Lateral wall of inferior meatus** :- opening for the nasolacrimal duct



✳ Nasal septum

The septum of the nose divides the nasal cavity into right and left portions. These portions are generally unequal, so the septum deviates to one side or the other. The septum is formed by the following elements which are covered with a nasal mucosa:



- 1- **The septal cartilage:** which represents the movable portion of the septum and it is not seen in the dried skull.
- 2- **The vertical plate of the ethmoid bone:** it forms the anterosuperior portion of the bony septum.
- 3- **The vomer:** it forms the posteroinferior portion of the bony septum.

Deviated Nasal Septum:

The nasal septum can be deviated from birth but, more often, it is from an injury in childhood or during adulthood, especially those associated with contact sports. A slight deviation may be unnoticeable or it may be observed as a lateral bend in the nose when observed from a frontal view. When severe, the nasal septum may be displaced to one side so that it is in contact with the lateral nasal wall, thus reducing respiratory capability, causing infection, inflammation, and sinusitis, indicating the necessity for surgical treatment.

*** Nerve supply**

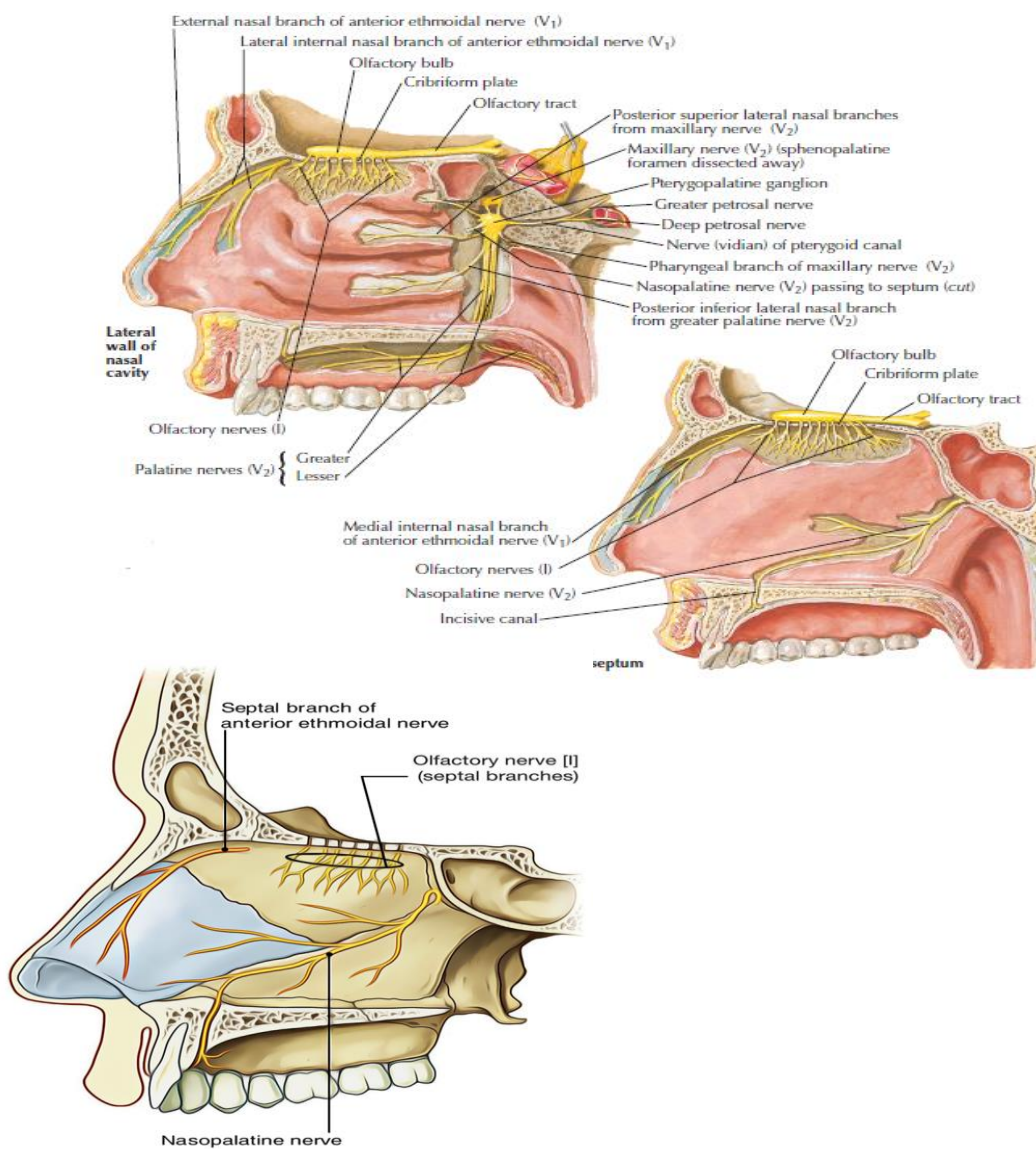
➤ **General sensation:**

- 1- **Anterior ethmoidal nerve:** Arises from the nasociliary branch of the ophthalmic nerve within the orbit. It passes medially through the anterior ethmoidal canal of the orbit wall to supply the anterior ethmoidal air cells, then it continues medially to enter the anterior cranial fossa briefly and then exits through the ethmoidal canal anterior to the cribriform plate. The canal leads to the roof of the nasal cavity, and here the nerve divides into internal branches (pass to the lateral nasal wall and septum), and external nasal branches (continue downward on the internal aspect of the nasal bone to exit into the external nose as the external nasal nerve).
- 2- **Nasal Branch of the infraorbital nerve:** the nasal branch of the infraorbital nerve supplies the skin of the ala of nose.
- 3- **Nasal Branch of Anterior superior Alveolar nerve:** as the Ant. Sup. Alv. nerve descends in its canal wall of the maxillary sinus; it gives off an internal nasal branch which passes to the nasal cavity just below the inferior concha. It supplies the mucosa of the anterior portion of the inferior meatus.
- 4- **Superoposterior Lateral Nasal Nerve (short sphenopalatine nerves):** These arise from the pterygopalatine ganglion and pass medially through the sphenopalatine foramen of the lateral nasal wall to supply the posterior two thirds of the lateral nasal wall. The inferior posterior lateral nasal branches arise from the greater palatine branch of the pterygopalatine ganglion as it descends in its canal. The branches leave the canal to supply the inferior lateral aspect of the nasal wall.

5- **Nasopalatine Nerve (Long sphenopalatine nerve):** this nerve arises from the pterygopalatine ganglia and passes medially through the sphenopalatine foramen to the nasal cavity. It continues medially and then it is directed downward and anteriorly along the nasal septum to supply it. It ends by passing through the incisive canal to the oral cavity below, where it is sensory to the oral mucosa of the anterior aspect of the hard palate.

➤ **Special sensation (Smell):**

The olfactory mucosa contains bipolar olfactory cells. The peripheral processes pass to the mucosa as hair like smell receptor ending. While the central processes pass upward in a form of bundles of filaments which pass through the cribriform plate and end in the olfactory bulbs.



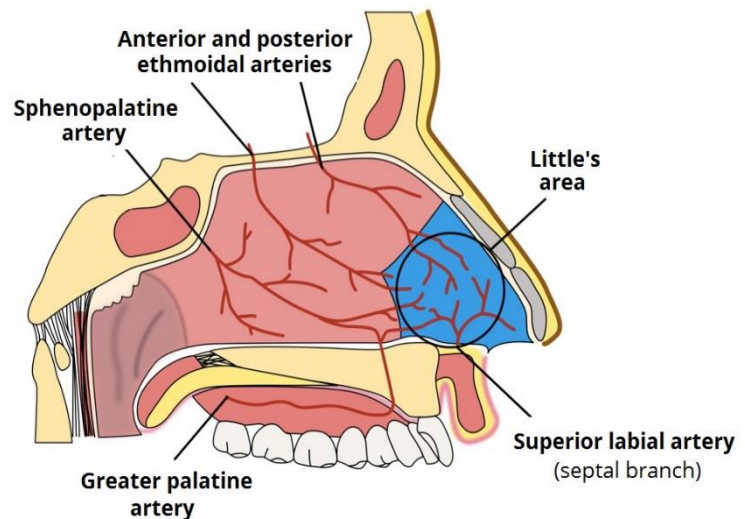
✿ Autonomic nerve supply

Parasympathetic and sympathetic nerve supply to the gland of the nasal mucosa arise from postganglionic fibers of the pterygopalatine ganglion travelling with the posterolateral nasal and nasopalatine nerves.

✿ Arteries

The mucosa of the nasal cavity receives a rich blood supply from several sources that anastomose freely. The important and largest arteries are the anterior ethmoidal branch of the ophthalmic artery and the sphenopalatine branch of the maxillary artery.

In addition, small nasal branches from the facial and infraorbital arteries.



✿ Veins

The venous return collects as a plexus from which veins drain to ophthalmic veins, pterygoid plexus, facial vein and infraorbital veins.

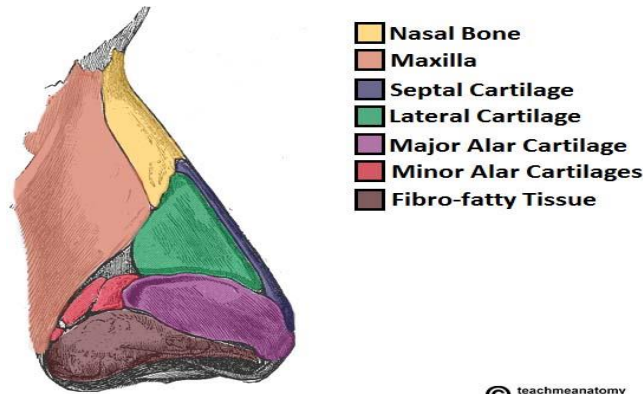
Epistaxis(Nosebleed):

Bleeding from the nose subsequent to injury of the nose is a common occurrence and is usually relatively easy to control. Normally, the source of blood flow is the Kiesselbach area—the anteroinferior region of the nasal septum where the septal branch of the superior labial, anterior ethmoidal, nasopalatine, and greater palatine arteries anastomose. The bleeding is controlled by pressure or by packing the nose with cotton. When the injury is from a direct blow, the cribriform plate of the ethmoid bone may be fractured.

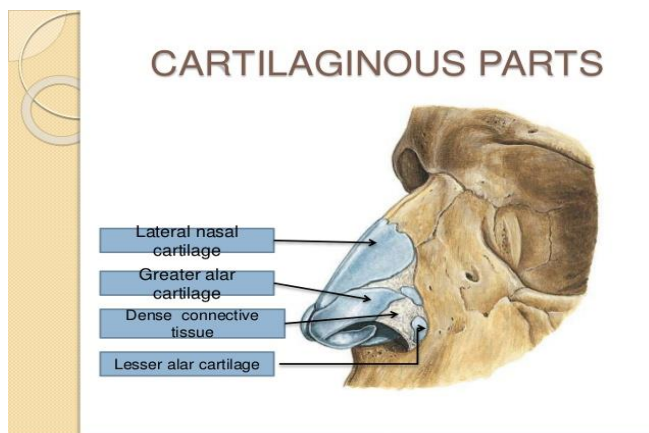
During fracture of the ethmoid bone, cerebrospinal fluid may leak into the nasal fossa and out through the external nares. This condition, cerebrospinal rhinorrhea, may lead to meningitis, with possibly fatal consequences.

✿ External Nose

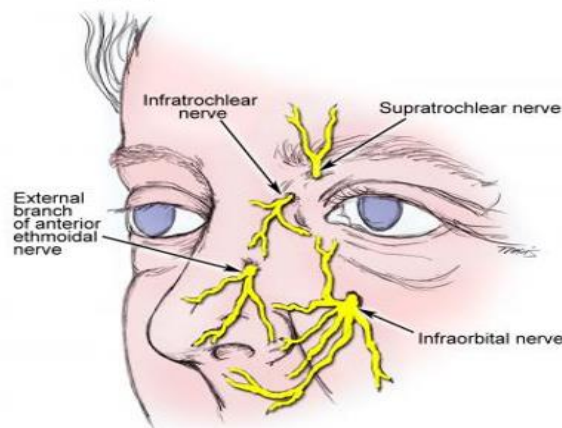
- The external nose is partly formed by the nasal and maxillary bones superiorly.
- The external nose is partly formed by the nasal and maxillary bones superiorly.
- ***The inferior portion of the nose is made up of hyaline cartilages; lateral, major alar, minor alar, and the cartilaginous septum.***



© teachmeanatomy



Nerve supply of External nose



LARYNX

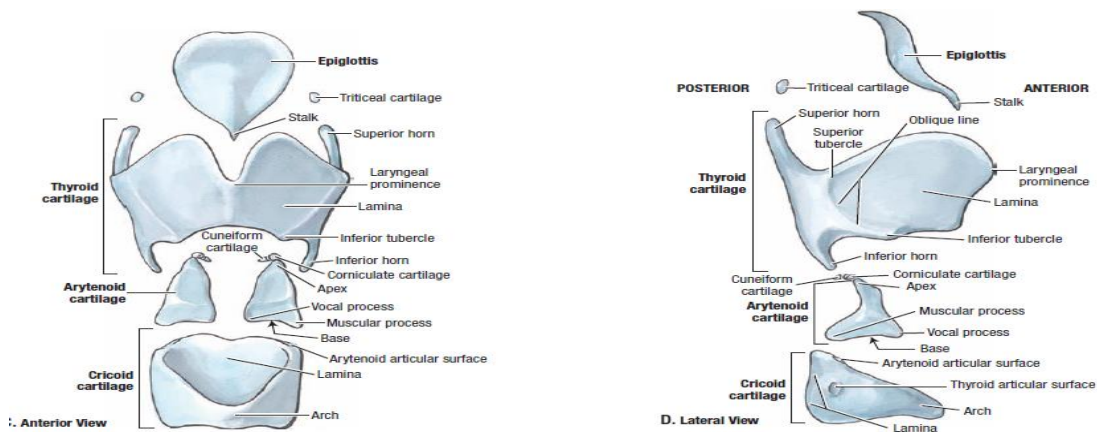
The larynx lies between the lower end of the pharynx (at vertebral level C3) above, and the upper part of the trachea (at vertebral level C6) below.

Its functions are:

- 1- Air passage
- 2- As a sphincter to prevent food from entering the air passage.
- 3- Organ of phonation.

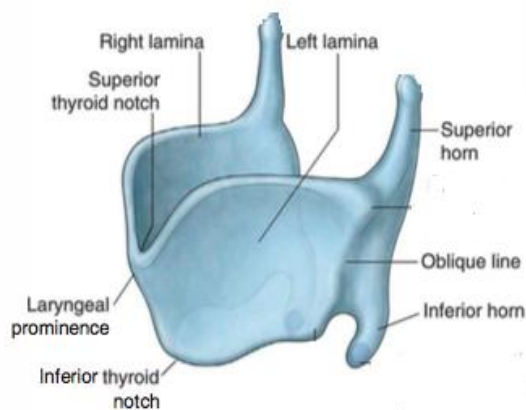
✿ Skeleton

The skeleton of the larynx consists of three large unpaired cartilages, these are thyroid, epiglottis and cricoid cartilages, and three small paired cartilages, these are arytenoid, cuneiform and corniculate cartilages.



✿ Thyroid cartilage

It is the largest cartilage and consists of two laminae or plates united in the middle line in front to form a projecting eminence called (Adam's Apple).

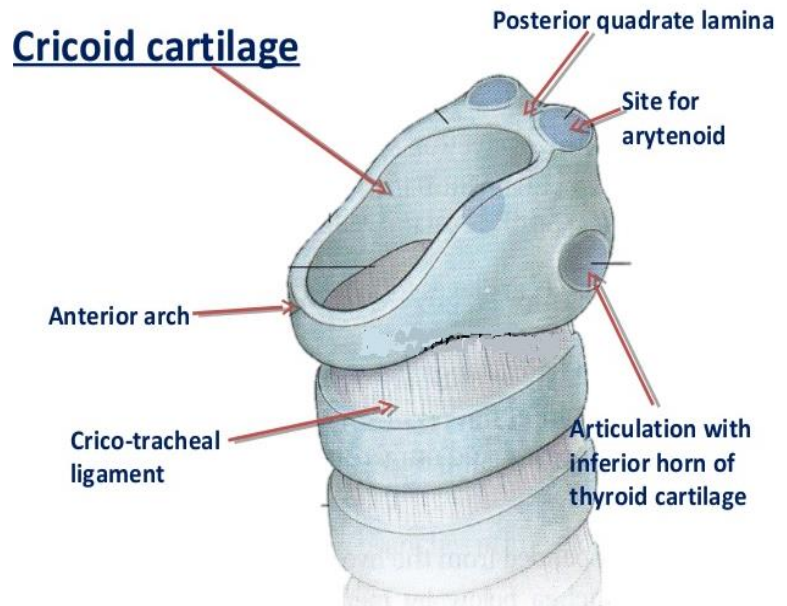


Above this projection, there is a deep V-shaped thyroid notch. The posterior border of each lamina is projected upward as a superior horn attached by a ligament to the greater horn of the hyoid bone. The posterior border also extends inferiorly as an inferior horn, which articulates at the side of cricoid cartilage.

The outer surface of the laminae is marked by oblique line along which are attached the thyrohyoid, sternothyroid and inferior constrictor muscle.

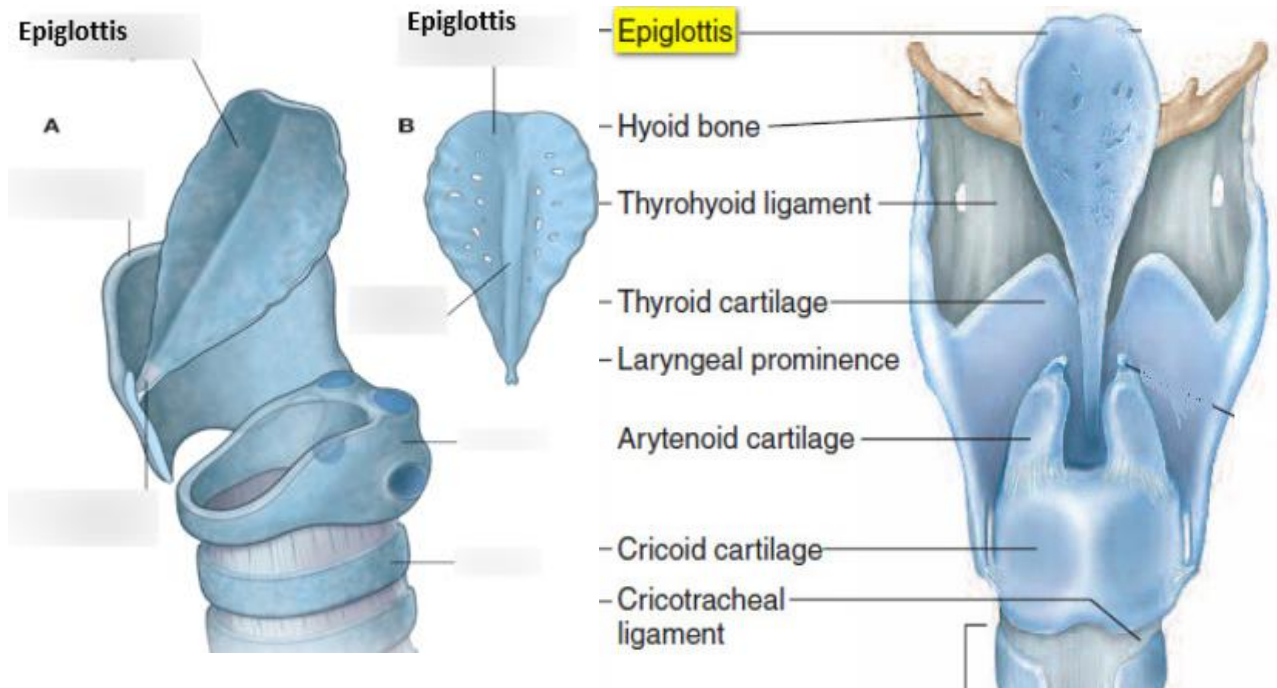
*** Cricoid cartilage**

It has a signet ring and attached below to the upper cartilaginous ring of the trachea. It is narrow at the front and sides but is wide posteriorly where it gives attachment to the arytenoid cartilages. The inferior horn of the thyroid cartilage articulates with its lateral aspect.



*** The Epiglottis**

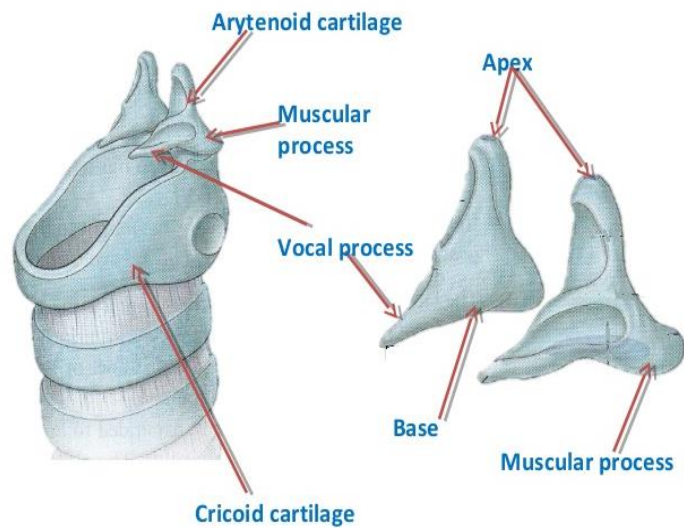
It is a thin leaf-like structure made of elastic cartilage. It's projected upward behind the tongue and the body of the hyoid bone to which it attaches by the hyo-epiglottic ligament. Its lower end is attached to the posterior surface of the thyroid cartilage by the thyro-epiglottic ligament below the thyroid notch.



✿ Arytenoid cartilages

They are pyramidal in shape. Each articulates at its base with the cricoid cartilage. The lateral projection of the base forms a muscular process and the anterior projection forms the vocal process to give attachment to the vocal ligament.

The apex of each arytenoid cartilage projects upward and slightly backward.



✿ Corniculate cartilages

They are small elastic cartilages located at the apices of the arytenoid cartilages.

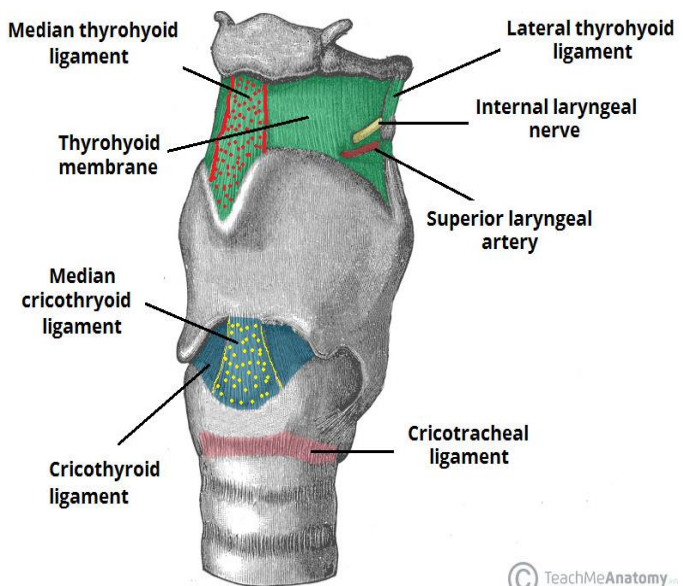
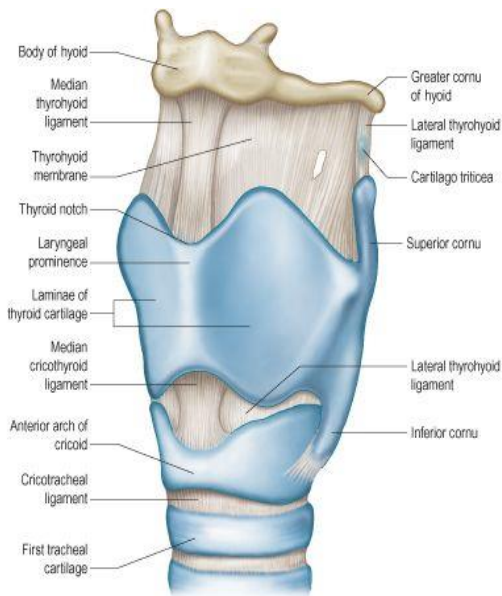
✿ Cuneiform cartilages

They are small elastic cartilages located in the aryepiglottic folds.

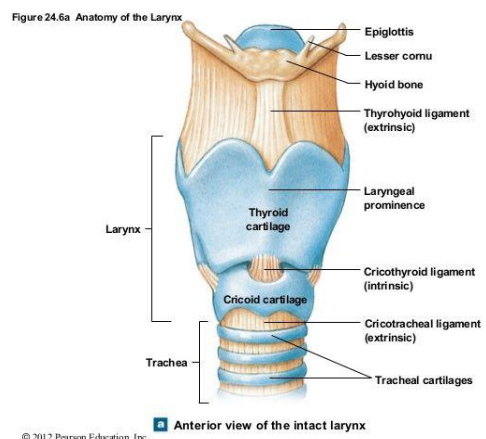
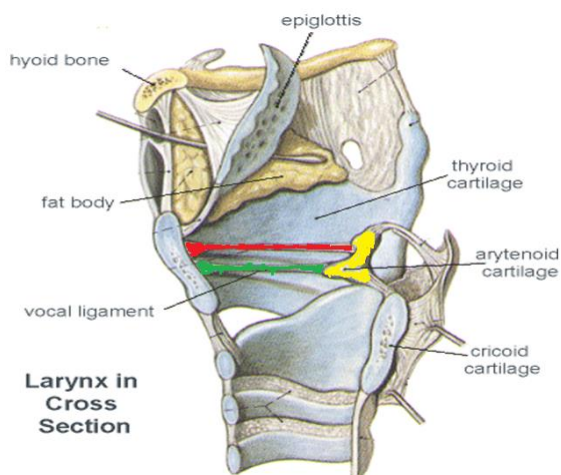
✿ Membranes and ligaments of the larynx

- 1- **Thyrohyoid membrane:** it is a fibroelastic sheet joining the inferior surface of the hyoid bone to the superior aspect of the thyroid cartilage. It is thickened in lateral and in the midline to form the lateral and the median thyroarytenoid ligaments respectively.
- 2- **Cricothyroid ligament:** it joins the superior border of the cricoid cartilage to the inferior border of thyroid cartilage.
- 3- **Vocal ligaments:** these are thick bonds of elastic fibers running from the vocal processes of the arytenoid cartilages forward for converge as a V on the internal angle of the thyroid cartilage. They are covered by mucous membrane to form vocal folds or true vocal folds.
- 4- **Ventricular ligaments:** these are two bonds of fibers that run from the lateral borders of the arytenoid cartilages to the internal angle of the thyroid lamina. These ligaments run above the vocal folds and they are covered by mucous membrane to form the ventricular folds or false vocal folds.

- 5- **Median cricothyroid ligament:** it is a median ligament that runs from the anterosuperior aspect of the cricoid cartilage to the anteroinferior border of the thyroid cartilage.
- 6- **Aryepiglottic ligaments:** these pass upward from the apices of the arytenoid cartilages to the superior lateral borders of the epiglottis.
- 7- **Quadrangular membrane:** the area between the aryepiglottic ligament above and the ventricular ligament below is filled with a thin fibroelastic sheet, which is called the quadrangular ligament because of its shape.
- 8- **Cricothyroid membrane (conus elasticus):** the triangular area between the vocal folds above and the superior border of the cricoid cartilage below is filled with a fibroelastic sheet.



© Elsevier Ltd 2005. Standing: Gray's Anatomy 39e - www.graysanatomyonline.com



© 2012 Pearson Education, Inc.

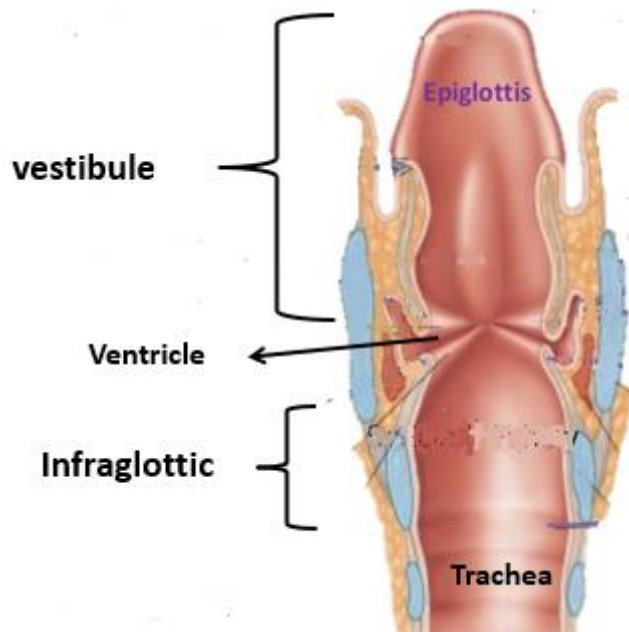
✿ Laryngeal inlet (Aditus)

The laryngeal inlet allows air to pass from the pharynx above to the lumen of the larynx below, it is formed anteriorly by the curved superior border of the epiglottis, laterally by the aryepiglottic folds, and posteriorly by fold of mucous membrane of arytenoid cartilages.

✿ The lumen of the larynx

The lumen extends from the inlet above to the lumen of the trachea below to set off folds, which covered by mucous membrane, that are projected from the lateral walls of the larynx to the lumen, **these are:**

- 1- Ventricular folds (superior set).
- 2- Vocal folds (inferior set).



✿ The two sets of folds divide the lumen into three parts:

- 1- The **vestibule** is the portion of the lumen above the ventricular folds. It is wide above and constricted below.
- 2- The **ventricle** is a small mid-portion between the ventricular folds and the vocal folds. The ventricle extends laterally and from it rises a blind pouch directed upward for about 1 cm known as **laryngeal saccule**.
- 3- The **infraglottic** cavity is a portion of the lumen inferior to the vocal folds.

❖ **Glottis** is a term applied for both vocal folds.

❖ **Rima glottis** is the opening between the vocal folds, it may be opened or closed.

✿ Muscles of the Larynx

Extrinsic muscles: the muscles which depress the larynx are the infrahyoid muscles, and the muscles, which elevate the larynx are the suprahyoid muscles.

Intrinsic muscles: These originate from the larynx and insert into the larynx.

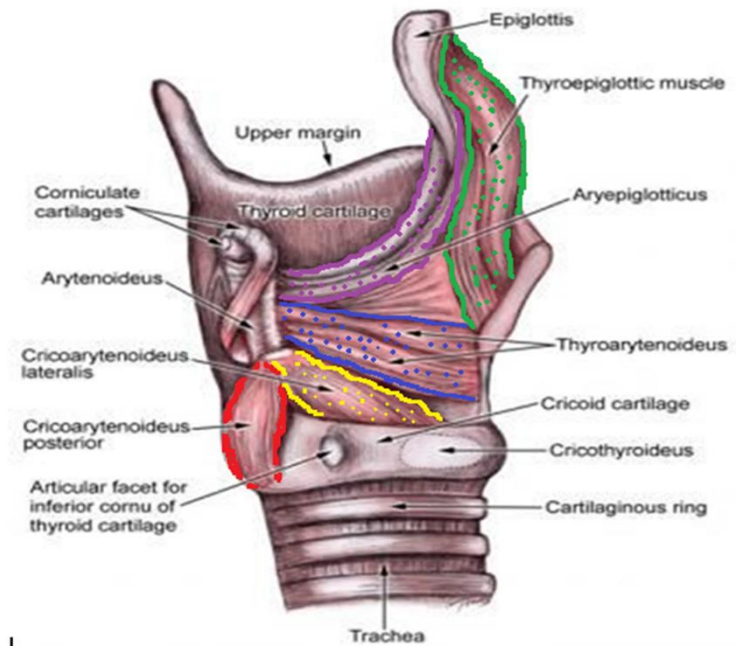
There are 8 pairs of intrinsic muscles:

- 1) **Cricothyroid muscle:** this muscle arises from the anterior aspect of the cricoid cartilage and inserted into the posteroinferior border of the thyroid cartilage. This muscle stretches vocal folds.
- 2) **Transverse arytenoid muscle:** it arises from the muscular process and the lateral aspect of the arytenoid of the opposite arytenoid cartilage. This muscle approximates the right and left cartilages.

3) **Posterior cricoarytenoid muscle:**

it arises from the posterior aspect of cricoid laminae and inserts into the muscular process of arytenoid cartilage. This muscle abducts the vocal folds.

- 4) **Lateral cricoarytenoid muscle:** it arises from the lateral aspect of the cricoid cartilage and inserts into the muscular process of arytenoid cartilage. This muscle adducts the vocal folds.



- 5) **Aryepiglottic muscle:** it arises from the muscular process of the arytenoid cartilage and passes upward and medially to cross the mid-line to insert in the apex of the opposite arytenoid cartilage, this part of the muscle is known as **oblique arytenoid muscle**. Then the muscle fibers continue upward to insert into the lateral aspect of the epiglottis. The muscle closes the Vestibule.
- 6) **Thyroarytenoid muscle:** It lies just above the lateral cricoarytenoid muscle. It arises from the internal aspect of the thyroid lamina and inserts into the lateral border of the arytenoid cartilage. The muscle closes the vestibule.
- 7) **Thyroepiglottic muscle:** the fibers run from the thyroid cartilage to the epiglottis and help to close the vestibule.
- 8) **Vocalis muscle:** the lower medial fibers of the thyroarytenoid muscle passes as a band of muscle fibers to insert on the vocal process of the arytenoid cartilage. The muscle fibers run below and lateral to the vocal ligament.

This muscle shortens the vocal ligaments.

✿ **Motor nerve supply**

All the intrinsic muscles are supplied by laryngeal branches of the vagus nerve through the recurrent laryngeal nerve. (**Except the cricothyroid muscle through the external laryngeal nerve**)

✿ Sensory nerve supply

The vagus nerve is sensory nerve to the larynx through two laryngeal branches. The internal laryngeal branch is sensory from the mucous membrane above the vocal folds. The recurrent laryngeal nerve is sensory from the mucous membrane below the vocal folds.

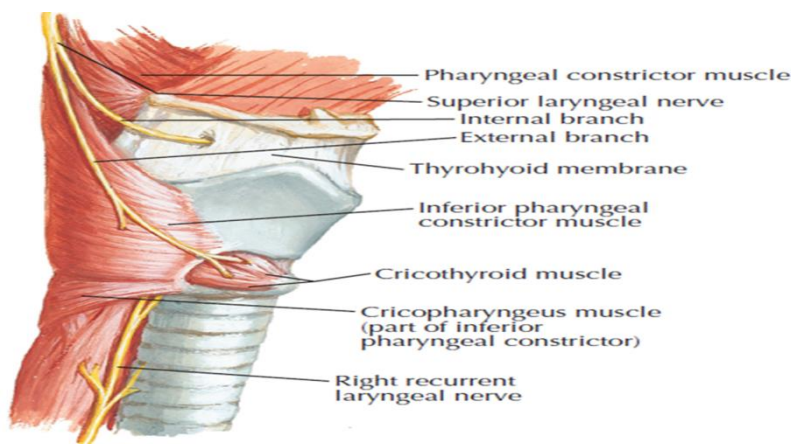
✿ Arteries

It receives blood supply from:

1. **Superior thyroid artery:** gives the superior laryngeal artery which accompanies the internal laryngeal nerve through the thyrohyoid membrane.
2. **Inferior thyroid artery:** gives the inferior laryngeal artery which accompanies the recurrent laryngeal nerve.

Veins:

.Laryngeal veins: drain to the superior thyroid veins



⊙ Clinical notes

- **Vocal fold paresis**
- The recurrent laryngeal nerve is responsible for innervating all muscles of the larynx except the cricothyroid muscle. The clinical term to describe when one or two of the recurrent laryngeal nerves are injured is vocal fold paresis (also known as recurrent laryngeal nerve paralysis or vocal fold paralysis).
- The recurrent laryngeal nerves are involved in breathing, swallowing and vocalization. So, if one of the nerves is injured (unilateral injury), it usually results in hoarseness due to the reduced movement of one of the vocal folds.

Unilateral injury may also cause minor shortages of breath, and aspiration problems especially with liquids.

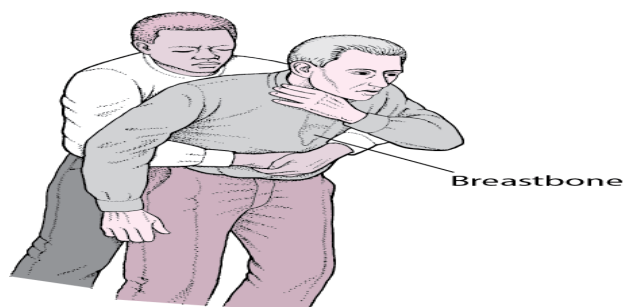
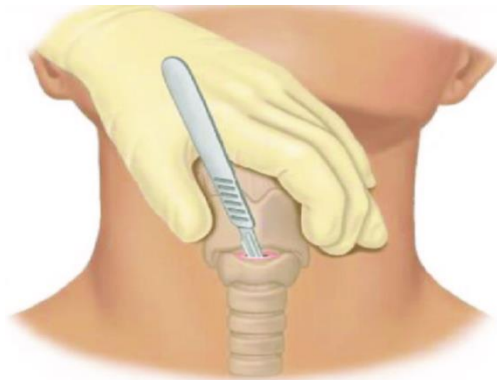
- A bilateral injury, or when the two recurrent laryngeal nerves are injured, causes the vocal folds to weaken the air flow, which results in breathing problems, snoring sounds, stridor and fast physical exhaustion. When the vocal folds are bilaterally paralyzed, hoarseness rarely occurs.

Heimlich maneuver:

Foreign objects, such as a piece of meat, can be aspirated into the inlet of the larynx and become lodged in the laryngeal vestibule above the vestibular folds, causing muscle spasms that tense the vocal folds, thus closing the rima glottidis. At this point, depending upon the degree of constriction, air movement into the trachea is restricted or may be completely obstructed from entering the trachea. The individual may start choking and perhaps will be unable to speak. The obstruction may result in complete asphyxiation and the person may die within approximately five minutes. Depending on the severity and condition of the patient, the Heimlich maneuver is performed to dislodge the obstruction by sudden compression of the abdomen to force a blast of air out of the lungs through the trachea and into the larynx, expelling the foreign object. When this procedure is unsuccessful, an emergency airway must be made into the trachea with a large-bore needle through the cricothyroid ligament.

© Cricothyrotomy

A cricothyrotomy or thyrocricotomy, or (emergency airway puncture): is an incision made through the skin and cricothyroid membrane to allow air to pass into lungs. It is regarded as emergency during certain life-threatening situations, such as airway obstruction by a foreign body, angioedema, or massive facial trauma.



ORBITAL CAVITY

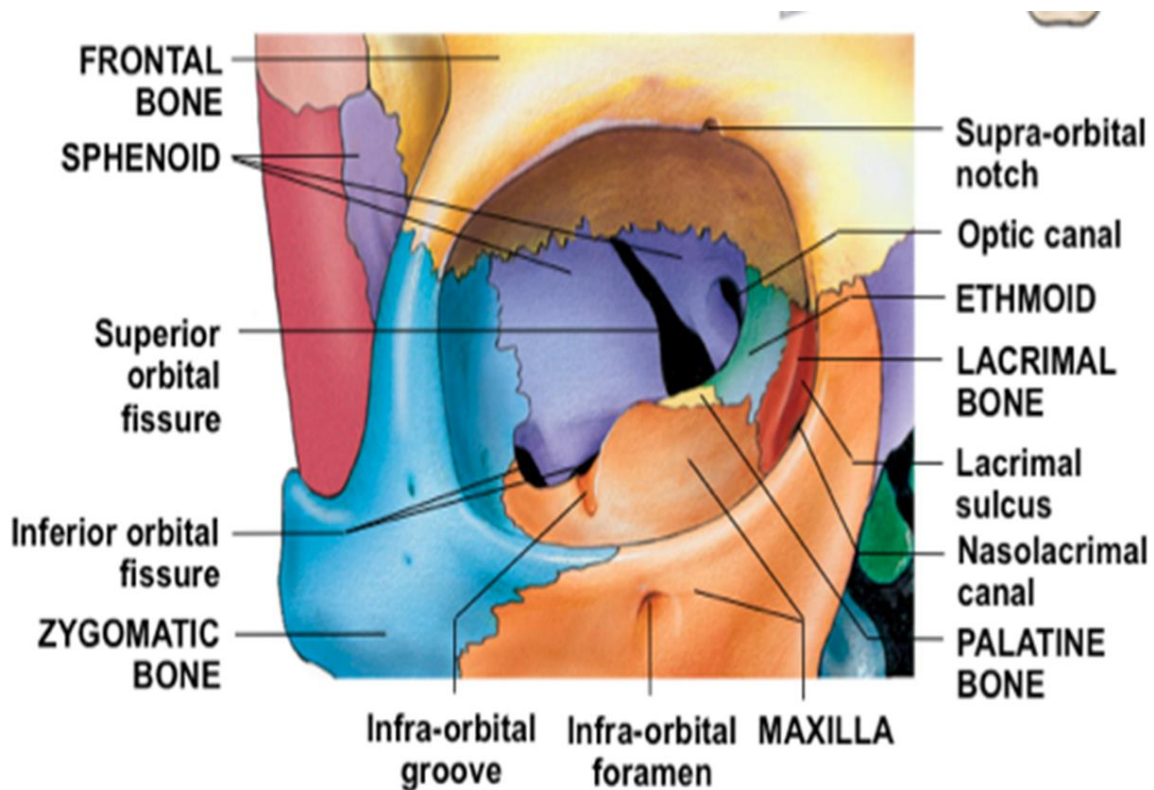
• Orbital Margins

Orbital margin: The frontal, maxillary, and zygomatic bones contribute to the orbital margin (orbital rim), which is generally strong so as to protect the orbital contents.

the superior half of the orbital rim is the supraorbital margin and the inferior half is the infraorbital margin.

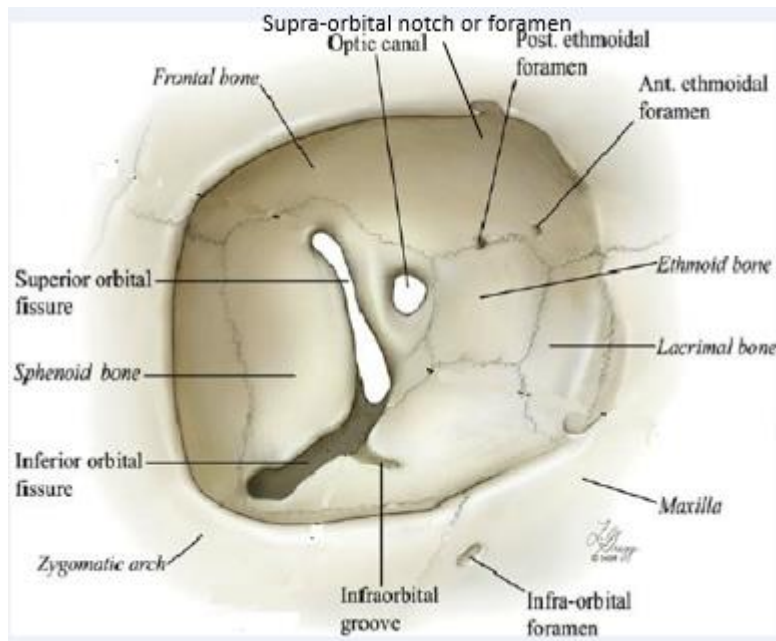
• Orbital walls

- **Roof (superior):** orbital part of the frontal bone, lesser wing of the sphenoid bone.
- **Medial wall:** orbital plate of the ethmoid bone, lacrimal bone, frontal process of the maxilla, lesser wing of the sphenoid bone.
- **Floor (inferior):** orbital surface of the maxilla, zygomatic bone.
- **Lateral wall:** zygomatic bone, greater wing of sphenoid bone.



• Openings

- 1- Supraorbital foramen or notch.
- 2- Infraorbital groove, canal and foramen.
- 3- Superior orbital fissure.
- 4- Inferior orbital fissure.
- 5- Optic canal.
- 6- Anterior and posterior ethmoidal foramen.



• Ocular structures

The eye is made up of three layers:

- 1- the outer layer is called the fibrous coat, which consists of the sclera and the cornea.
- 2- the middle layer is responsible for nourishment, called the vascular coat, which consists of the iris, the choroid, and the ciliary body.
- 3- the inner layer of photoreceptors and neurons is called the nervous coat, which consists of the retina.

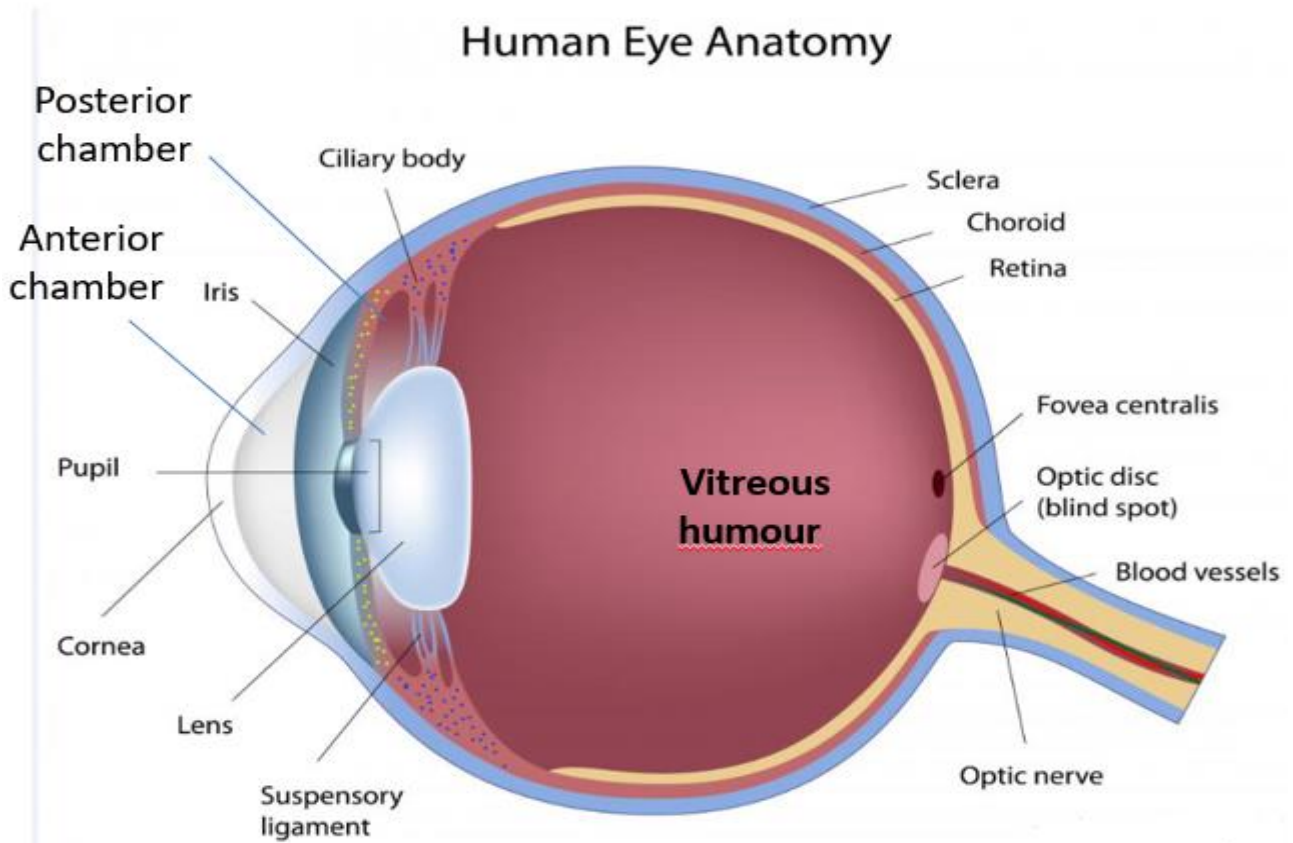
• Chambers of the eye

The eye also contains three fluid-filled chambers.

The chamber between the cornea and the iris is known as the anterior chamber, while the chamber between the iris and the lens is known as the posterior chamber, both chambers contain a fluid called aqueous humor.

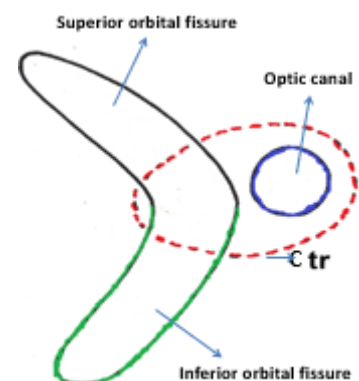
Aqueous humor is watery fluid produced by the ciliary body. It maintains pressure (called intraocular pressure) and provides nutrients to the lens and cornea.

The greatest chamber, forming about four-fifths of the eye, is found between the retina and the lens called the **vitreous chamber**. The vitreous chamber is filled with a thicker gel-like substance called vitreous humor which maintains the shape of the eye.



- **Common tendinous ring**

The common tendinous ring consists of fibrous tissue located at the apex of the orbit. It surrounds the optic canal as well as the medial end of the superior and inferior orbital fissures.



The common tendinous ring provides attachment for all four rectus muscles, superior oblique muscle and the Levator palpebrae superioris muscle.

✿ Relationships of the orbit

Superiority → the anterior cranial fosse and the frontal lobes of the brain.

Inferiority → the maxillary sinus.

Posteriorly → the middle cranial fosse and the temporal lobes of the brain

.Laterally → the temporal fosse.

Medially → the nasal cavity.

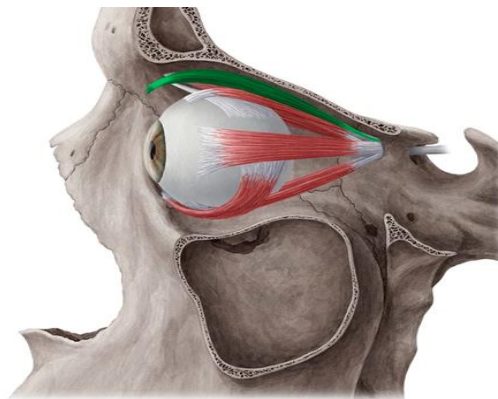
✿ Contents of the orbit

- Eyeball and it's optic nerve.
- Extra ocular muscles.
- Nerves of the eyeball and muscles.
- Vessels of the eyeball and muscles.
- Lachrymal gland.
- Orbital fat which acts as packing to the eyeball.

✿ Muscles of the orbit

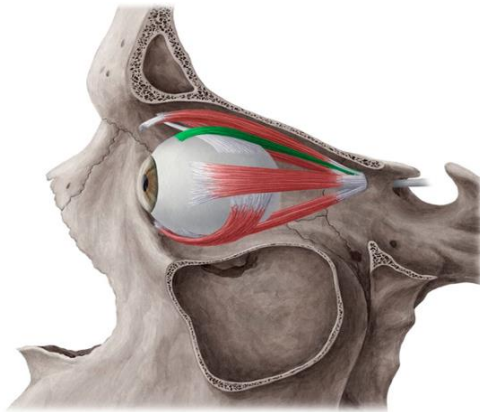
- ✿ All muscles of the orbit -except one- have a common origin from a **tendinous ring**. The ring occupies the posterior pole of the orbit, it is attached to, and surrounds the optic canal and the mid-portion or the superior orbital fissure. From this common origin, the muscles originate and pass anteriorly to attach to the eyeball.

- 1) **Levator palpebrae superioris**: it originates from the superior position of the ring. It runs over the superior aspect or the eyeball and inserts in to the skin of the upper lid. A few involuntary fibers insert into the tarsal palate.
- The muscles act to open the palpebral fissure. **The small involuntary portion innervated by sympathetic nerve fibers, while the oculomotor nerve supplies the remainder of the muscles.**



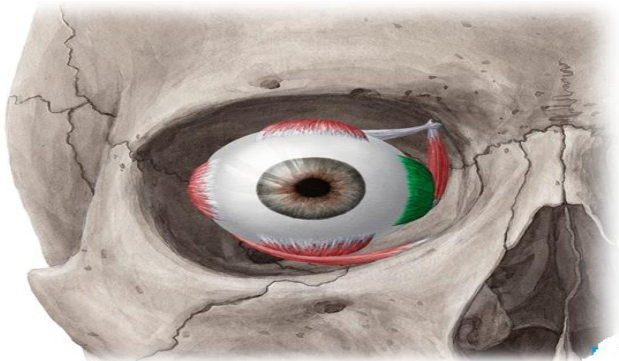2) Superior rectus muscle: it originates from the superior position of the tendinous ring and inserts anteriorly into the superior aspect of the eyeball behind the sclerocorneal junction.

- The superior rectus muscle turns the eyeball upward, it also turns the eyeball slightly medially or inward (adduction). **It is supplied by a branch of the oculomotor nerve.**



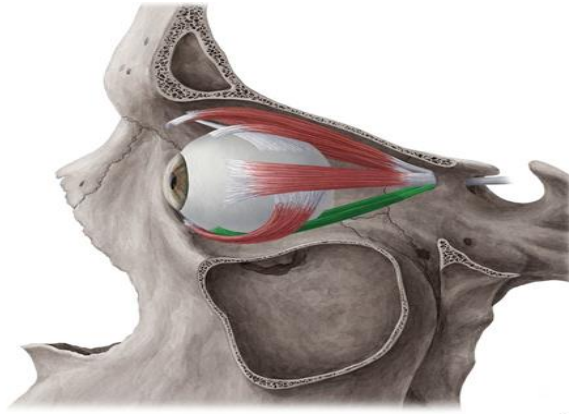
3) Medial rectus muscle: it arises from the medial position of the tendinous ring and inserts into the medial aspect of the eyeball behind the sclerocorneal junction.

- The muscle acts to turn the eyeball inward (adduction). **It is supplied by a branch of the oculomotor nerve.**



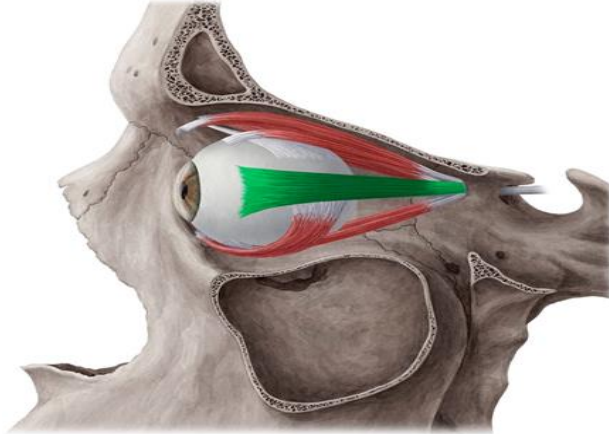
4) Inferior rectus muscle: it arises from the inferior position of the tendinous ring, travels forward under the eyeball, and inserts into the inferior aspect of the eyeball behind the sclerocorneal junction.

- It turns the eye inferiorly and helps to turn the eye inward (adduction). **It is supplied by the oculomotor nerve.**



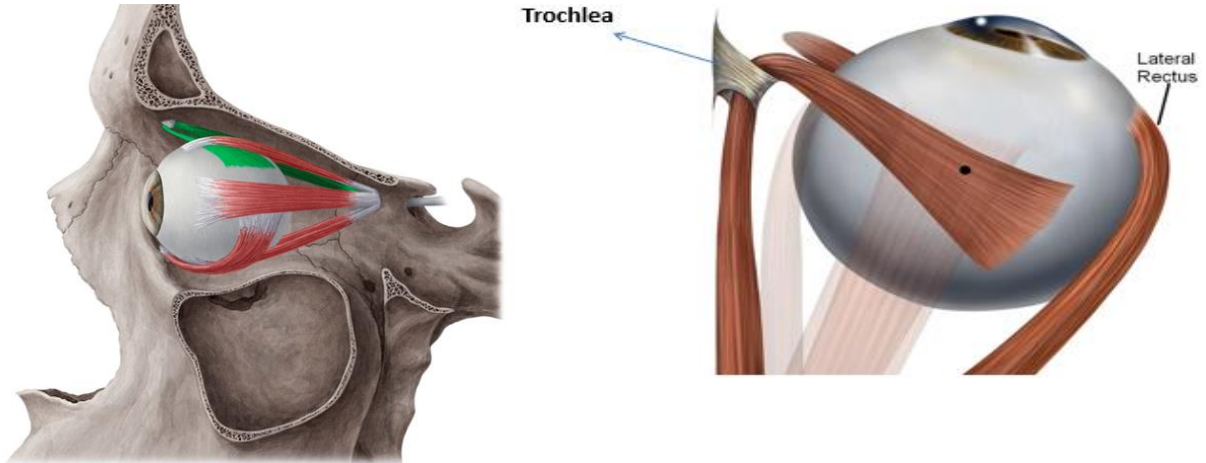
5) Lateral rectus muscle: arises from the lateral position of the tendinous ring, runs anteriorly and inserts into the lateral aspect of the eyeball behind the sclerocorneal junction.

- It turns the eyeball outward (abduction). **Supplied by the abducens nerve.**

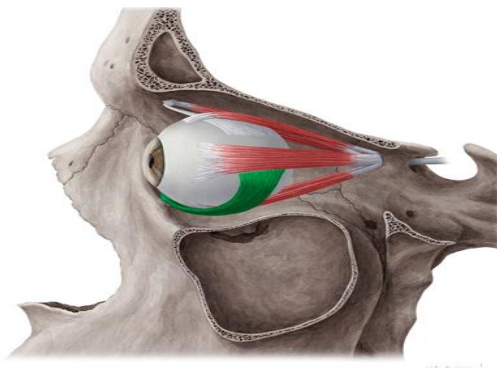


6) Superior oblique muscle: originates from the superomedial position of the tendinous ring and passes forward and medially toward the superomedial margin of the orbit. Here it narrows as an intermediate tendon and passes through dense fibrous pulley or trochlea. The tendon loops through the trochlea and changes its direction posteriorly and laterally to insert into the superior lateral aspect of the eyeball.

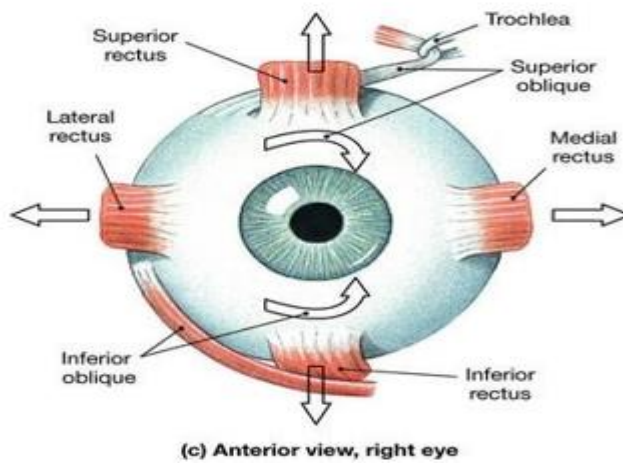
It acts to turn the eye downward and medially. **Supplied by the trochlear nerve.**



7) Inferior oblique muscle: originates from the floor of the orbit near the posterior lacrimal crest. it passes obliquely backward and laterally to insert into the sclera of the inferolateral aspect of the eyeball. It turns the eyeball superiorly and medially. **A branch of oculomotor nerve supplies it.**



Action of Extra-ocular muscles

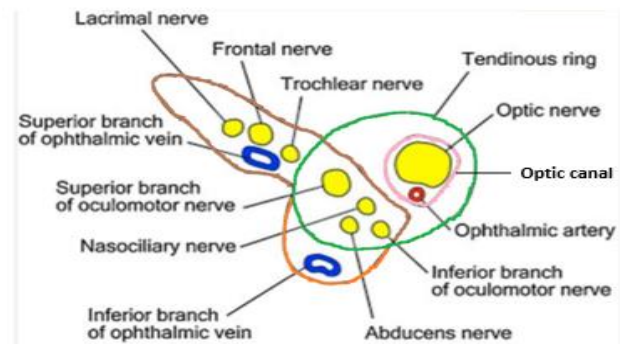


Nerves of the orbit:

1) Optic nerve: (special sensory nerve)

It passes through the optic foramen from the middle cranial fosse and travels forward and slightly laterally towards the posterior aspect of the eyeball.

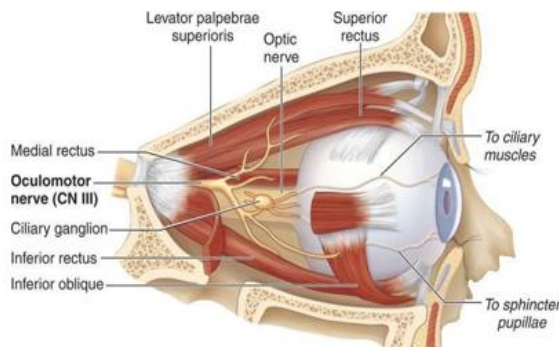
Structures pass through the orbital fissures and optic canal



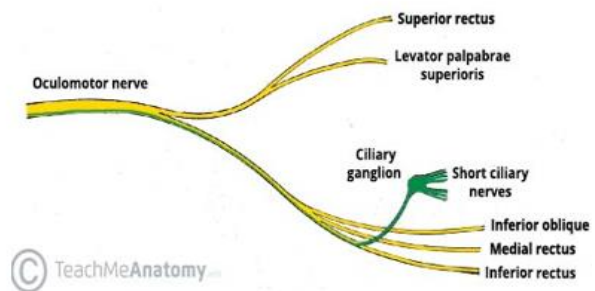
2) Oculomotor nerve: (CN III)

It enters the orbit through the superior orbital fissure and divides into Superior and Inferior divisions, these supply all of the extraocular muscles except the superior oblique and the lateral rectus muscles.

Oculomotor nerve (CNIII)



Oculomotor nerve



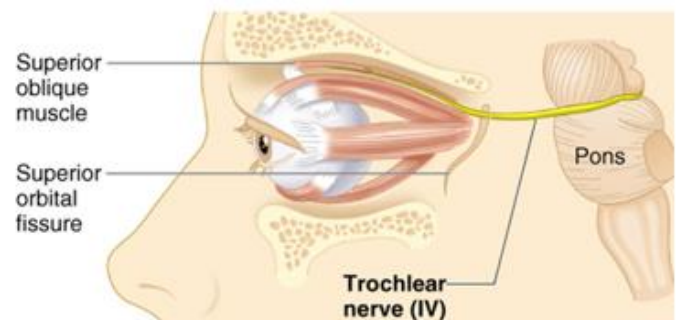
In addition, it carries pre- parasympathetic component and these fibers leave the nerve within the orbit to synapse within the ciliary ganglia.

3) Trochlear nerve: (CN IV)

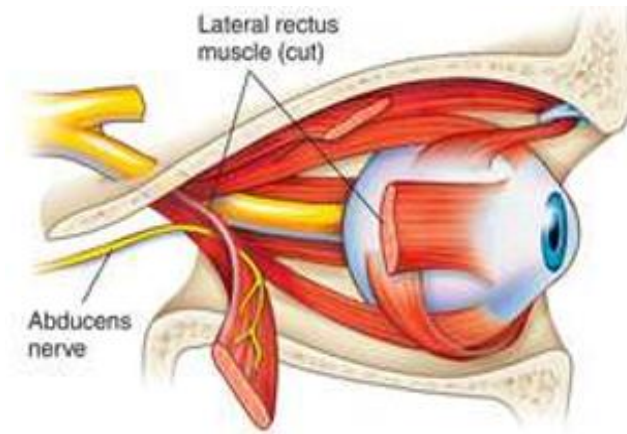
It enters the orbit through the superior orbital fissure, it passes to supply only the superior oblique muscle.

4) Abducens nerve: (CN VI)

It enters the orbit through the superior orbital fissure, it passes to supply only the lateral rectus muscle.



Trochlear Nerve (IV) – means “pulley” it innervates an extrinsic eye muscle that loops through a pulley-shaped ligament



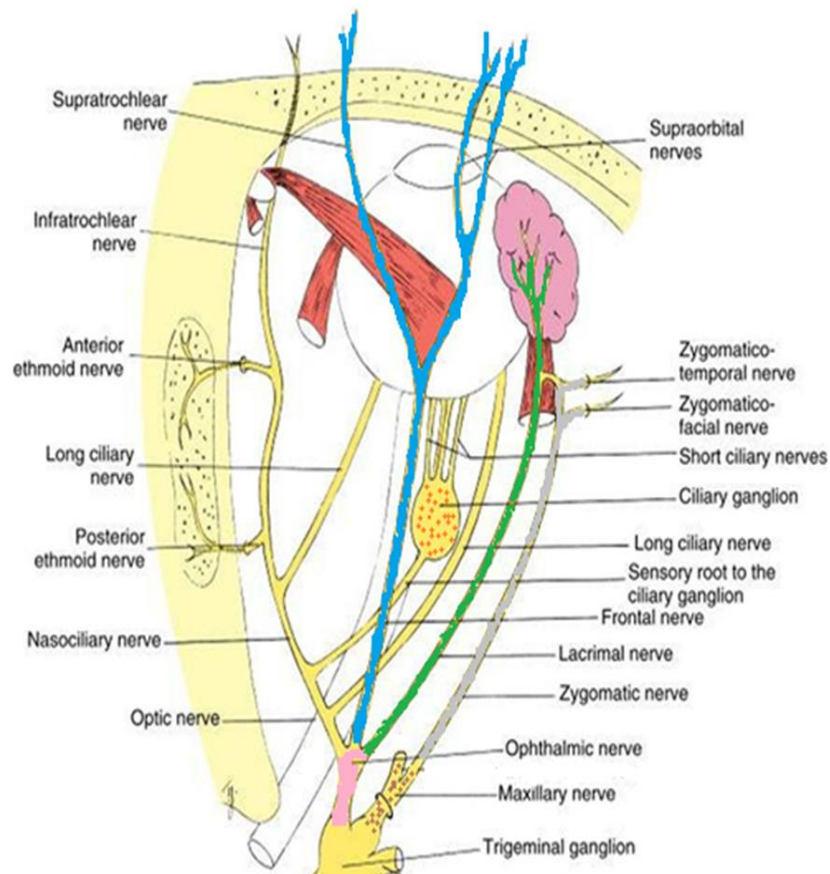
5) Ophthalmic nerve: (General sensory nerve)

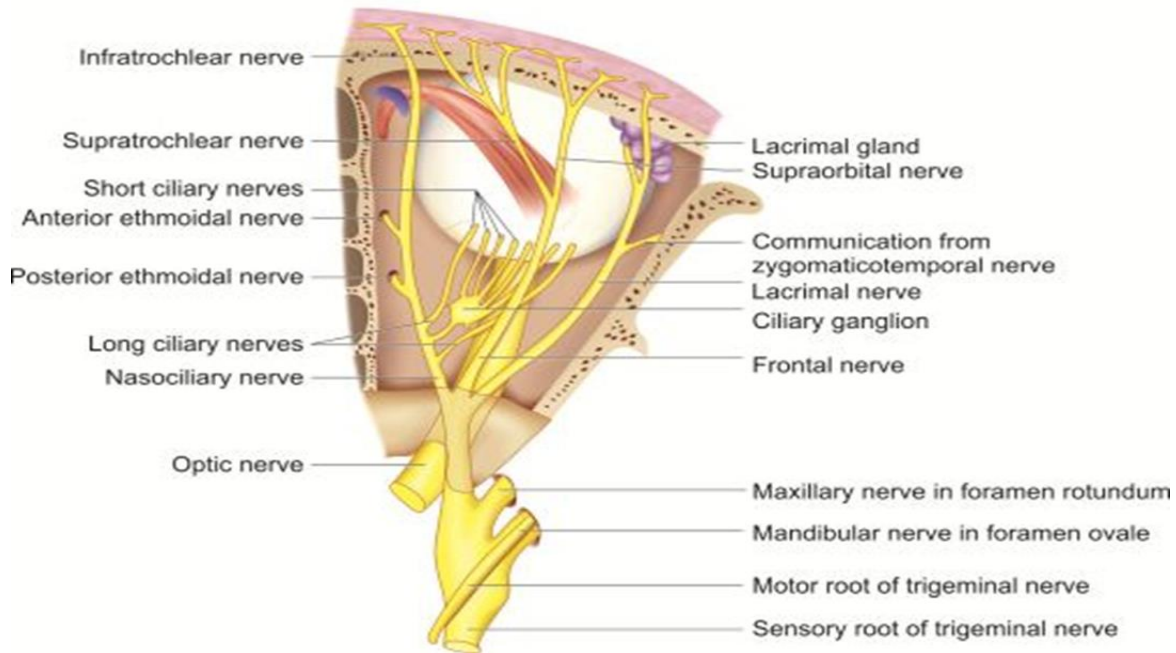
The ophthalmic nerve leaves the middle cranial fossa through the superior orbital fissure and breaks up immediately into three terminal branches:

- a- Frontal nerve.
- b- Nasociliary nerve.
- c- Lacrimal nerve.

- **Frontal nerve:** passes forward below the orbital roof, as it approaches the orbital margin, it divides into the **supraorbital** and **supratrochlear** nerves. These two nerves pass out of the orbit to the face to supply the skin and conjunctiva of the upper lid and the skin of the forehead and scalp.
- **Lacrimal nerve:** passes to the lateral wall of the orbit toward the lacrimal gland. It picks up post ganglionic secretory fibers from the pterygopalatine ganglion through the branch from zygomatic nerve, and carries them to the lacrimal gland. It ends by passing to the face(palpebral branch) to supply sensation from the lateral aspect of the upper lid.
- **Nasociliary nerve:** passes anteriorly and then medially parallel to the medial orbital wall. **The nasociliary nerve has three collateral and two terminal branches:**
 1. **Ganglionic branches:** pass entirely to the ciliary ganglion.
 2. **Long ciliary branches:** travel entirely to enter the posterior aspect of the eyeball, these are sensory to the eye and cornea.
 3. **Posterior ethmoidal nerve:** passes medially through its foramen in the medial orbital wall to supply posterior ethmoidal air cells.

4. **Anterior ethmoidal nerve:** it is a terminal branch that passes medially through its foramen in the medial orbital wall to supply the anterior ethmoidal cells. It continues medially into the anterior cranial fossa and then leaves through the small opening at the side of crista galli to the roof of the nasal cavity to give the internal nasal branches to the mucosa of the lateral and septal wall of the nose. Then it continues downward and forward along the internal aspect of the nasal bone. At the junction of the nasal bone and the lateral nasal cartilage, the nerve emerges into the nose as the external nasal nerve to supply the skin of the external nose.
5. **Infratrochlear nerve:** it is the second terminal branch which passes deep to the trochlea and exits from the orbit to supply the skin and conjunctiva of the medial angle of the upper lid.





✿ Ciliary ganglion

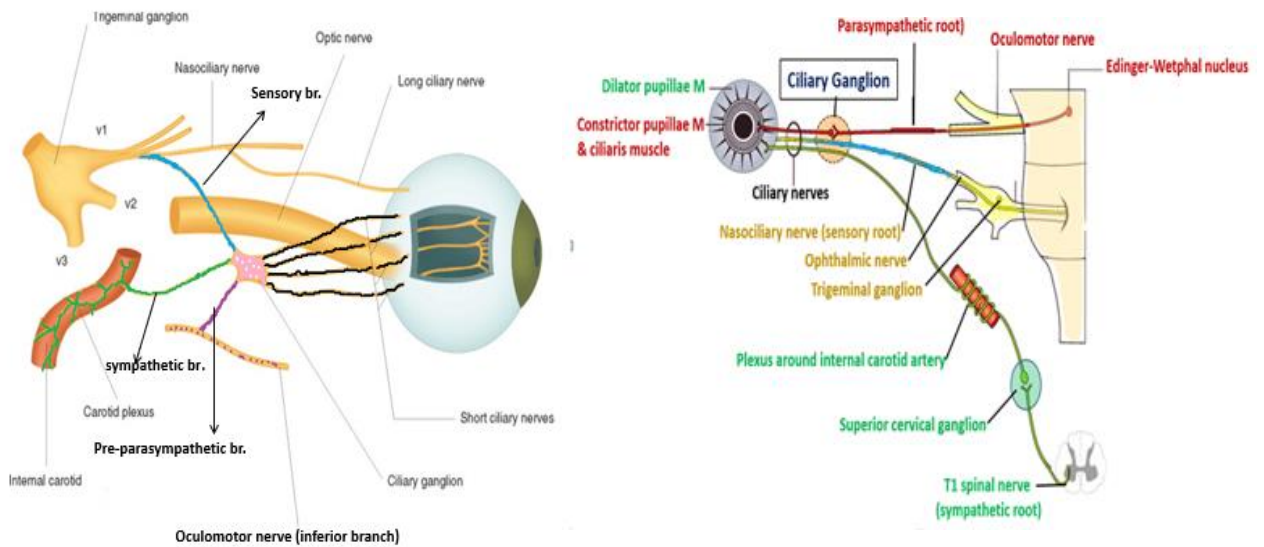
It is a small swelling located between the optic nerve and the lateral rectus muscle, associated with nasociliary nerve in the orbit. **it receives three types of nerve fibers:**

- 1- Sensory fibers come directly from the nasociliary nerve.
- 2- Sympathetic fibers arise from the plexus of the internal carotid and ophthalmic arteries.
- 3- Pre-parasympathetic fibers arise from the inferior division of the oculomotor nerve and synapse within the ganglion.
- 4- **The outflow from the ciliary ganglion is known as the short ciliary nerves and these are:**
 - a) Sensory branches for general sensory from the eyeball.
 - b) Sympathetic branches that supply the dilator pupil muscle of the eye.
 - c) Parasympathetic fibers that supply the constrictor pupil and ciliary muscle of the eye.

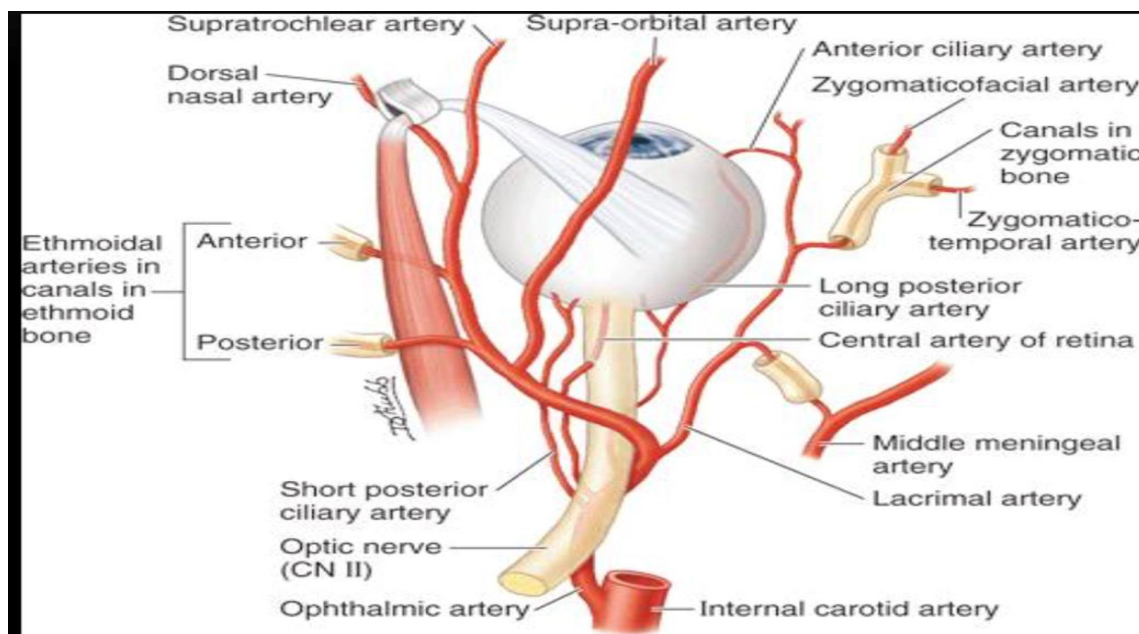
Blood vessels of the orbit

Ophthalmic artery: it arises from the internal carotid artery within the middle cranial fossa, it leaves the fossa through the optic foramen along with the optic nerve to enter the orbit. Within the orbit, it gives off a number of branches which are parallel to the branches of the ophthalmic nerve:

Ciliary ganglion



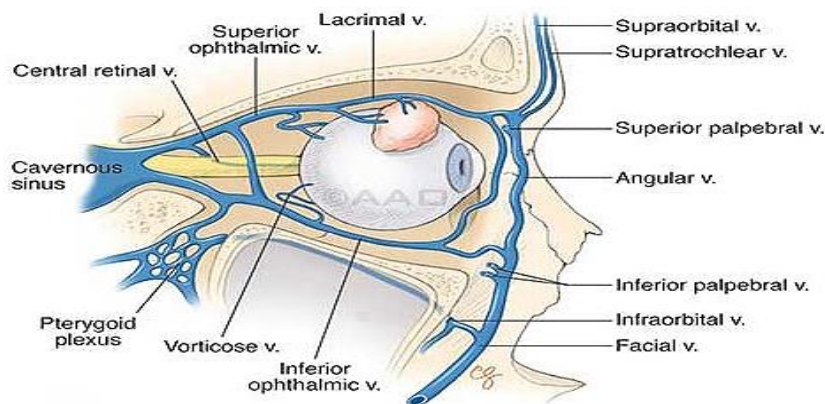
1. **Muscular branches:** to supply muscles of the orbit.
2. **Posterior ciliary arteries:** pass to the posterior aspect of the eyeball.
 - One special ciliary branch pierces the optic nerve posterior to the eyeball, it enters the eye to supply the retina as the central of the retina. **(it has no anastomosis with other arteries, so blockage of this artery results in blindness)**



Ophthalmic Veins

The superior ophthalmic vein communicates in front with the facial vein. The inferior ophthalmic vein communicates through the inferior orbital fissure with the pterygoid venous plexus. Both veins pass backward through

the superior orbital fissure and drain into the cavernous sinus.



Lymph Vessels

No lymph vessels or nodes are present in the orbital cavity.

✿ The lacrimal apparatus

- Lacrimal gland

The lacrimal gland is a serous gland that secretes tears which moisten, lubricate and protect the eyeball, the excess tears are removed by the nasolacrimal system.

The gland is located just behind the superolateral margin of the orbit, deep to the superior conjunctival sac.

The gland is looped around the free lateral border of the Levator palpebrae superioris muscle leading into deep (orbital) lobe and superficial (palpebral) lobe. There are about 10 – 20 small ducts open directly into the superior conjunctival sac.

- Nerve supply

Parasympathetic and sympathetic secretory fibers arise from the sphenopalatine ganglion, which enters the orbit through the inferior orbital fissure within the lacrimal nerve to the lacrimal gland.

- Nasolacrimal system

1- Puncta and papillae

At the junction of the ciliated and non-ciliated margin of the lids, there are upper and lower papillae. In the top of the papilla, there is a small opening or punctum which sucks up the excess tears.

lacrimal lake (lacus lacrimalis):

The lacrimal lake is the pool of tears, in the medial angle of eye around the lacrimal caruncle, which drains into the opening of the tear drainage system (the puncta lacrimalia). The lacrimal papilla is an elevation located on the medial canthus where the punctum is found.

2- Superior and inferior lacrimal canals

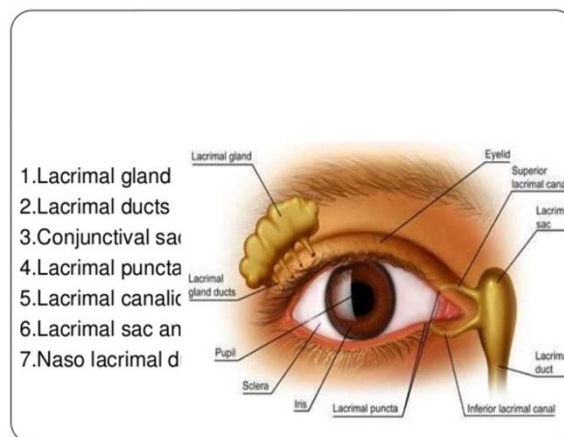
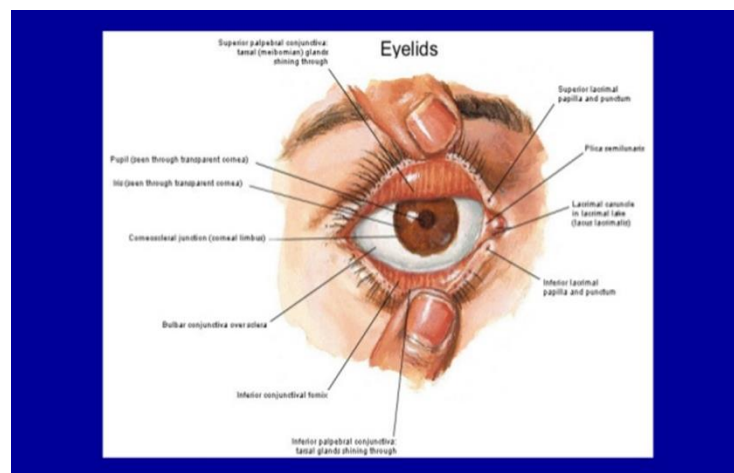
They are fine tubes the (lacrimal canaliculus. The canaliculi are tubes in the upper and lower lids convey the tears medially to the lacrimal sac.

3- Lacrimal sac

It is the upper portion of the nasolacrimal duct.

4- Nasolacrimal duct

It is a membranous tube, which drains the lacrimal sac and opens below in the inferior meatus of the nasal cavity.

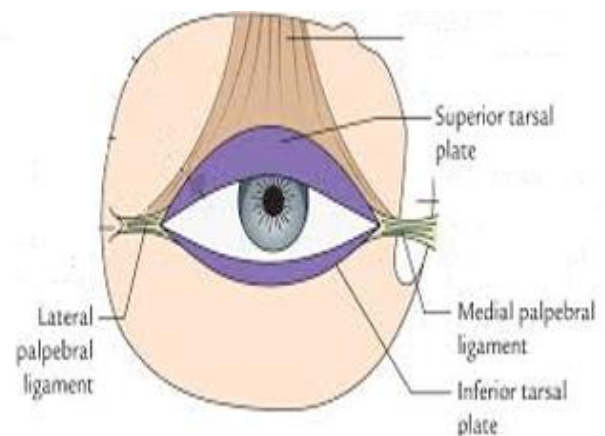
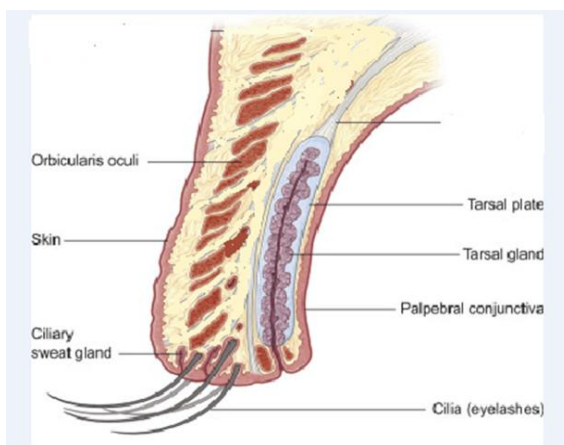


- Layers of the eyelid

From the external to deep, the layers are:

- 1) **Skin:** thin skin covers the lids of the eye. At the margins of the eye, there are hairs, cilia, from 1 – 3 rows along the margin.
- 2) **Subcutaneous tissue:** it contains large sebaceous glands (glands of Zeis) and sweat glands (glands of moll).
- 3) **Muscular layer:** the palpebral portion of the orbicularis oculi muscle occupies this layer.
- 4) **Orbital septum and Tars:** this layer forms the skeleton of the lid. It is a membranous C.T. sheet, which attaches to the periphery of the orbital margin. At the margins of the eyelid the septum becomes thick and forms the tarsal plate or tarsi which is a half-moon in outline. The tars contains layer of tarsal glands which are seen as yellowish nodules through the conjunctiva . The ducts open to the margins of the lids and secrete oily substance.
- 5) **Conjunctiva:** it is the mucous membrane of the lids that lines the inner aspect of the lid as palpebral conjunctiva, and then, it reflects at the base of the conjunctival sac into the eyeball as bulbar conjunctiva.

The line of reflection between palpebral and bulber conjunctiva form superior and inferior conjunctival sacs(fornix).



✿ The fascia of the orbit

1) Periorbita (Orbital periosteum):

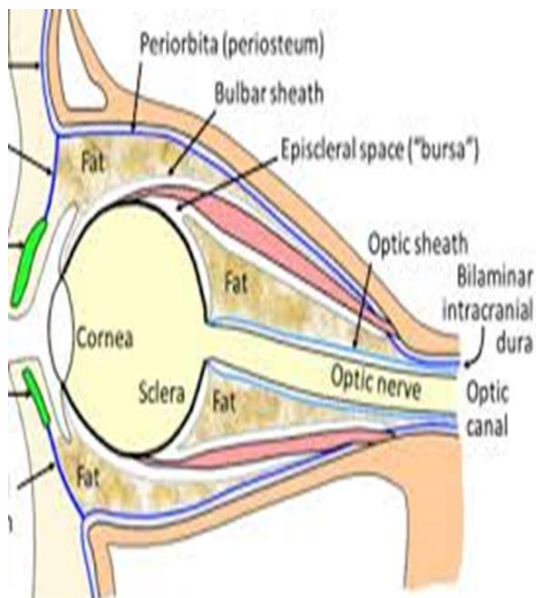
It forms a funnel-shaped sheath which is loosely attached to the bony walls and enclose the contents of the orbit and it is continuous with the endocranium through the optic canal and the superior orbital fissure.

2) Bulbar sheath:

It is a thin membrane, which covers all the eyeball except the cornea, it separates the eyeball from the surrounding fat, muscles and other tissues.

3) Muscular fascia:

It surrounds each ocular muscle and continues anteriorly with bulbar fascia. It reflects at the insertion of the muscle to form check ligaments to restrict the action of the ocular muscle.



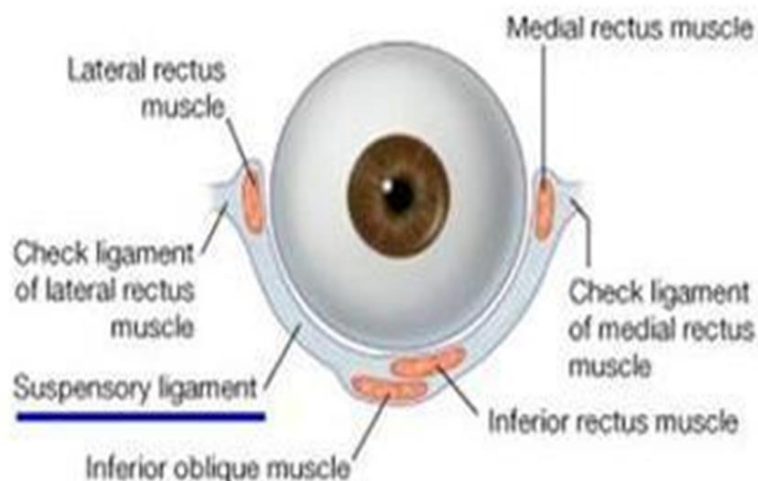
a. The medial check ligament:

which radiates from the medial rectus M. to attach to the post crest of the lacrimal bone.

b. The lateral check ligament:

which extends from the lateral rectus muscle to the zygomatic bone.

c. **Suspensory ligament:** which extends from the inferior rectus M. and the inferior oblique muscle to the floor of the orbit..



Myopia and Hyperopia

Changes in the longitudinal dimension of the optical axis will cause images to be focused either anterior (myopia) or posterior (hyperopia) to the retina. This is usually the result of changes in the refractive elements of the eye, notably the cornea, which assumes a slight change in shape or a change in the dimension of the orbit. Both processes often occur as a function of aging. These conditions can be diagnosed and treated with prescription-ground glasses that can optically correct the longitudinal dimension of the optical axis to the retina.

Cornea:

The cornea, the transparent, avascular portion of the fibrous tunic of the eye, is highly sensitive and is mostly exposed to the environment. Slight scratches and abrasions of the cornea usually heal without much scarring. However, more severe scarring impedes vision to such a point that a corneal transplant is prescribed. Presently, most transplanted corneas are received from human donors, whereas some transplants are plastic.

Conjunctivitis:

Conjunctivitis is a mild inflammation of the conjunctiva, which can be either bacterial or an allergic reaction. The sclera and undersides of the eyelids are involved. It is especially prevalent in newborns as they pass through the birth canal. Thus, newborns are immediately given prophylactic antibiotic eye drops to prevent neonatal conjunctivitis. In adults, conjunctivitis is caused mostly by seasonal allergy.

Cataract:

Cataract is an age-related condition where the lens loses its transparency and becomes clouded, causing blurred vision. It is the major cause of poor vision and blindness throughout the world. Modern techniques now permit surgical placement of plastic lenses, resulting in restored vision.

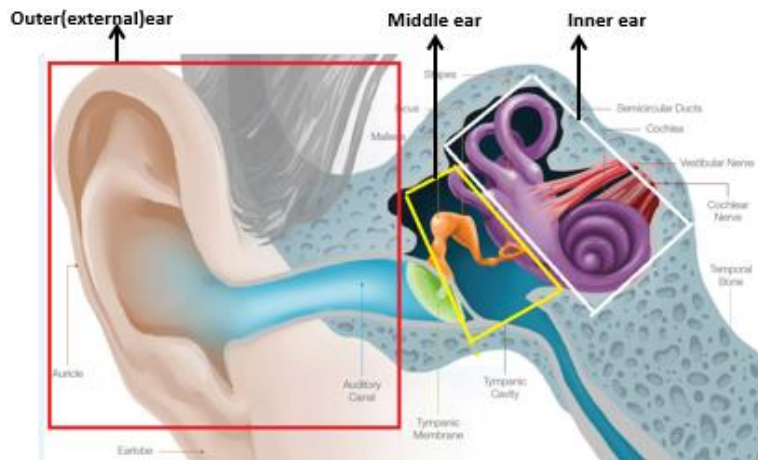
Glaucoma:

Is a common cause of blindness brought about by increased intraocular pressure that progressively and permanently destroy the optic nerve. The increase pressure is due to an obstructed outflow of aqueous humor .

EAR

The ear is made up of three parts:

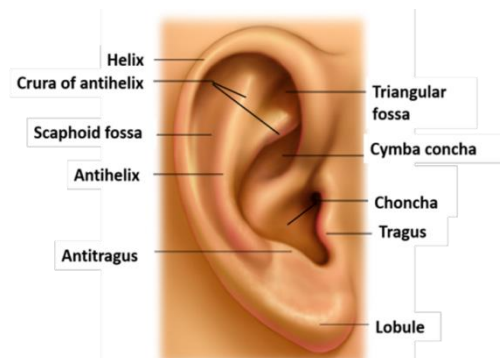
- 1- The external (outer).
 - 2- Middle.
 - 3- inner ear.
- All three parts of the ear are important for hearing. Ears also help to maintain balance.



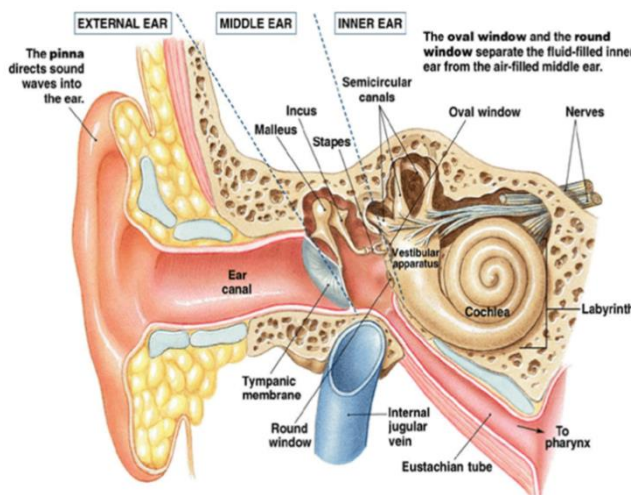
1) The external ear:

It includes:

- a. Auricle (cartilage covered by skin)
 - b. Auditory canal (also called the ear canal)
 - c. Eardrum outer layer (also called the tympanic membrane) The outer part of the ear collects sound.
- Sound travels through the auricle and the auditory canal, a short tube that ends at the eardrum.



The external Auditory meatus or canal is



about 2,5 cm in length, it carries the wave sound to the tympanic membrane. The lateral third of the tube is cartilage and lined by skin which contains hair follicles, submucous glands and modified sweat glands which produce a waxy exudate called **cerumen** or **ear wax**. (help to discourage insects from entering the ear).

The medial two thirds of the meatus are bone and lined by thin layer of stratified squamous epithelium.

Blood Supply:

- Auricular branch from the superficial temporal artery.
- Deep auricular branch from the first part of the maxillary artery.

Nerve supply:

- Auricular branch from the auriculotemporal nerve.
- Auricular branch from the vagus.

Tympanic membrane:

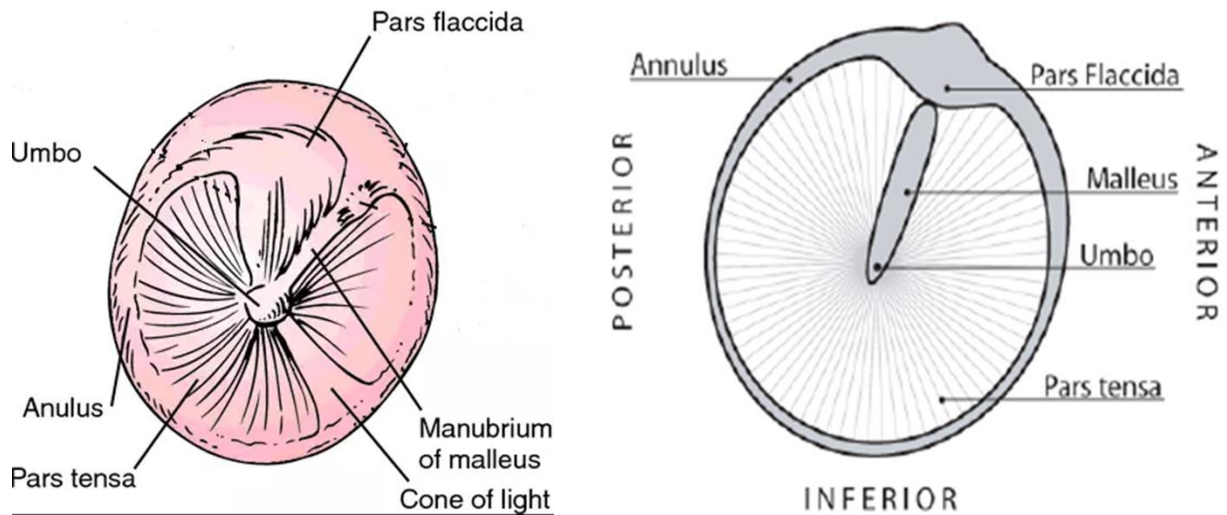
The external auditory meatus ends medially at a circular membrane (about 1 cm. in diameter). It is located obliquely at the end of the canal. It consists of circular and radial fibers. The lateral surface is lined with stratified squamous epithelium which continues with the skin lining the external auditory meatus. The medial surface is covered by mucous membrane which continues with the lining of the middle ear.

The handle of the malleus (one of the ear ossicles) is attached to the medial surface of the membrane which produces a small medial plug called **umbo**.

The radial fibers radiate from the umbo, except at a small superior portion which lacks fibers and called **pars flaccida**, while the remainder part is called **pars tensa**.

Nerve and blood supply:

- The outer (lateral) surface has the same nerve and blood supply as the external auditory meatus.
- The inner (medial) surface has the same nerve and blood supply of the middle ear.



2) The middle ear (Tympanic cavity):

Deep to the tympanic membrane is the cavity of the middle ear which contains three ossicles (3 tiny bones that are attached) and two small muscles. **the cavity has six surfaces:**

1. Lateral wall:

This wall is formed by the medial surface of the tympanic membrane. The chorda tympani nerve crosses the upper part of the medial surface of the tympanic membrane.

Roof:

It is formed by thin plate of bone called **tegmen tympani** which separates the middle ear below from the middle cranial fossa above.

Floor :

It is also formed by this plate of bone separates the middle ear above from the jugular foramen below.

Posterior wall:

It contains an opening on its upper part called **Aditus**, which is a short canal leads posteriorly to the mastoid antrum (which is an ear cell within the mastoid process).

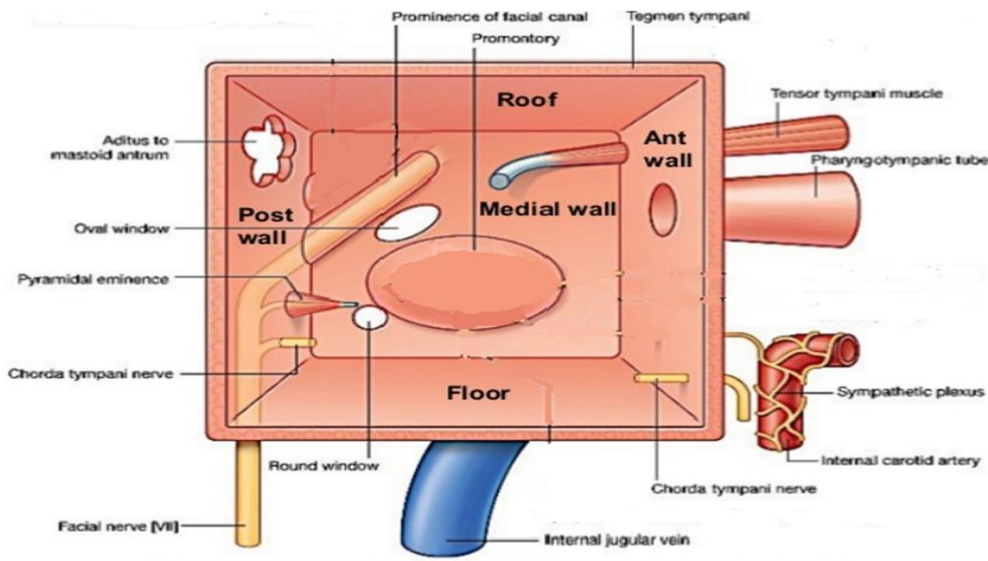
In the lower part of the posterior wall is a short conical projection called **pyramid**. From the tip of the pyramid, the stapedius muscle is originated.

Anterior wall:

This wall consists of two openings separated by a thin shell of bone. The small upper opening transmits the tendon of the tensor tympani muscle. The large lower opening is the medial opening of the auditory tube.

2. Medial wall:

The medial wall separates the middle ear from the inner ear. In the upper part of the medial wall, there is a round projection called **promontory** which is formed



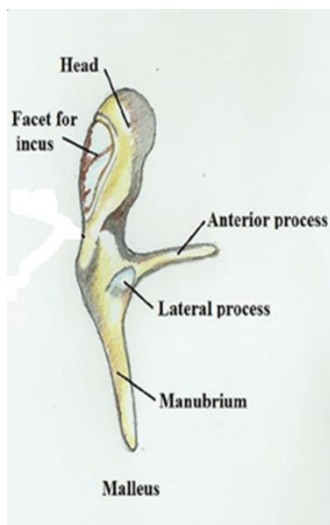
by the underlying cochlea.

There is an oval opening above the promontory called **vestibular window** (oval window) and the foot plate of the stapes covers this opening. There is a rounded opening below the promontory called **cochlea window** (round window) covered by a thin membrane.

These two windows communicate with the inner ear. Above the promontory and the oval window, a prominence formed by the facial canal which bulges out into the medial wall.

Ossicles of the middle ear:

The tympanic cavity contains a chain of three movable ossicles, the malleus, incus, and stapes. The first is attached to the tympanic membrane, the last to the circumference of the fenestra vestibuli. The three small bones connected to each other by delicate articulations.

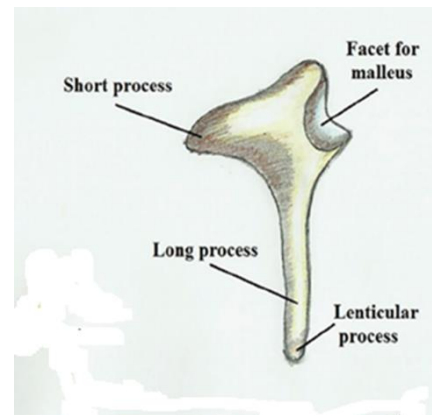


Three small articulating bones form a chain from the tympanic membrane (lateral wall) to the vestibular window on the medial wall:

Malleus: It consists of round head with two short processes and a long process called the handle, which is attached to the medial surface of the tympanic membrane. The tendon of the tensor tympani muscle is attached to the handle of the malleus.

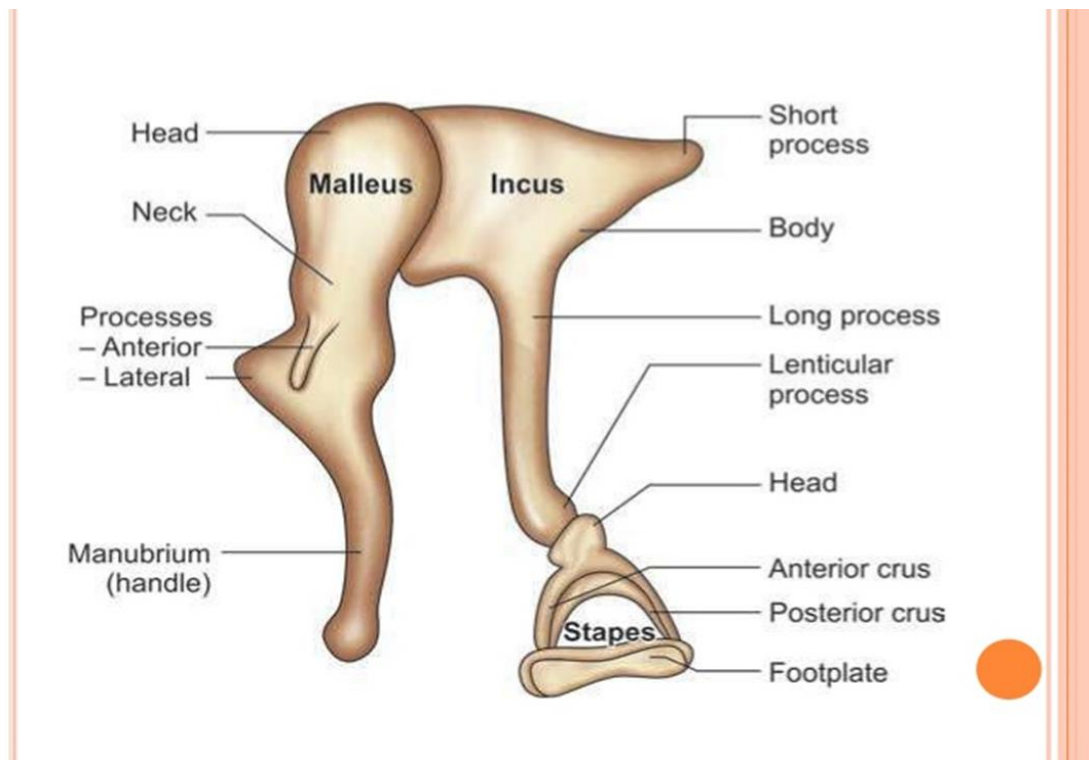
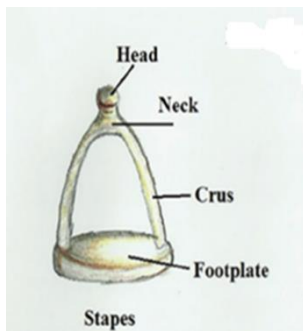
1. Incus (anvil):

It consists of body and two processes (like the molar tooth), one long and other short processes. The head of the malleus articulates with the body of the incus.



2. Stapes (stirrup):

It consists of small head which articulates with the incus, a short neck which leads to an arch and a flat oval foot plate forming the base of the arch that covers the vestibular window. The tendon of the stapedius muscle inserts into the neck of the stapes.



Muscles of the middle ear:

1. Tensor tympani muscle:

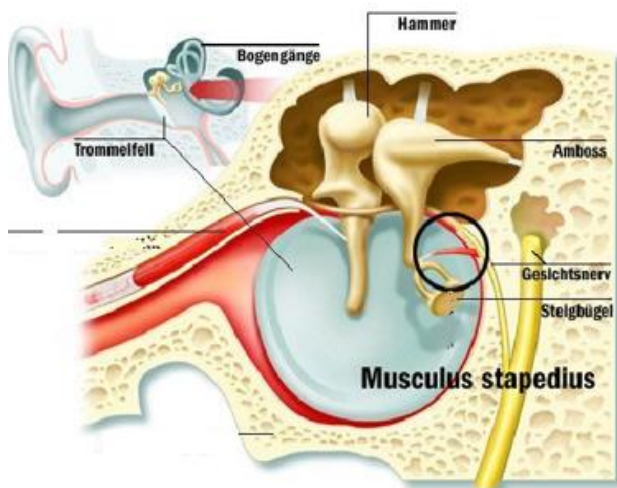
It originates from the cartilaginous and bony parts of the auditory tube. It passes posteriorly and laterally in the small canal and then inserts into the handle of the malleus.

It pulls the tympanic membrane inward, so it reducing(dampens) the transmission of sound to the inner ear so It is supplied by a branch from the mandibular nerve.

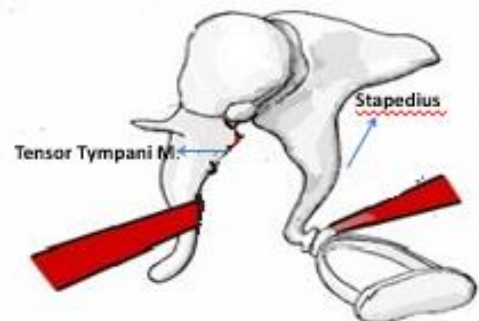
2. stapedius muscle:

It arises from the apex pyramid on the posterior wall of the middle ear. It is inserted into the neck of the stapes. It pulls the foot of the stapes laterally so it dampens the vibrations of the stapes by pulling on the neck of that bone. supplied by a branch of the facial nerve.

Muscles of middle ear



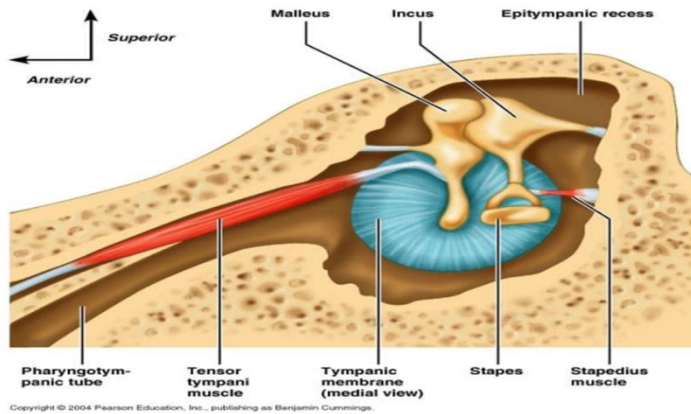
Insertion of the Muscles of Middle ear



Nerve and blood supply of the middle ear:

The sensory nerve supply to the mucosa of the tympanic cavity (including the medial surface of the tympanic membrane) arises from the tympanic branch of the glossopharyngeal nerve.

The blood supply is from tympanic branch from the posterior auricular artery and the first part of the maxillary artery.



The auditory tube:

It passes from the lateral aspect of the nasopharynx to the anterior wall of the tympanic cavity. The tube passes backward and laterally.

The lateral one — third (1.5 cm.) is a bony part lined with mucosa, while the medial two — thirds (2.5 cm.) is cartilaginous.

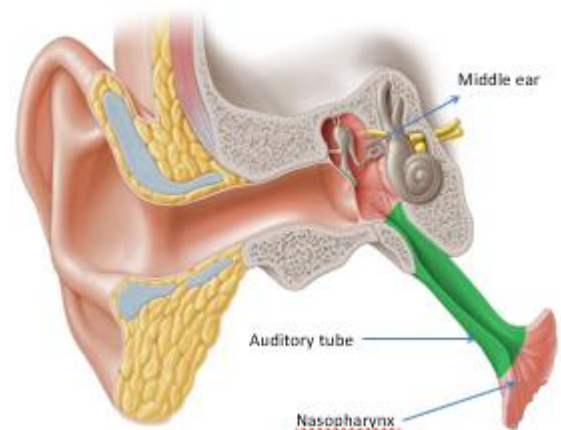
- It serves (help) to equalize air pressure on the tympanic membrane.
- It is usually closed, but opens during swallowing or yawning.
- Infections from the upper respiratory tract can be spread through the Eustachian tube and cause otitis media (middle ear infection).

3) The internal ear:

The internal ear is concerned with the reception of sound and balance. It is found medial to the middle ear within the petrous temporal bone. It consists of two parts:

1. **bony labyrinth:** system of canals filled with plasma like fluid called *perilymph*.

2. **membranous labyrinth:** it is located within the bony labyrinth and filled with fluid called *endolymph*.



Bony labyrinth:

It is divided into three parts:

Vestibule: a central part which communicates with the middle ear through the vestibular and cochlear windows.

1)Cochlea: it is the hearing organ; it has the shape of the shell of snail.

2)Semicircular canals: they are the receptor organs of balance, there are three canals (superior, lateral and posterior canals), each canal communicates with the vestibule.

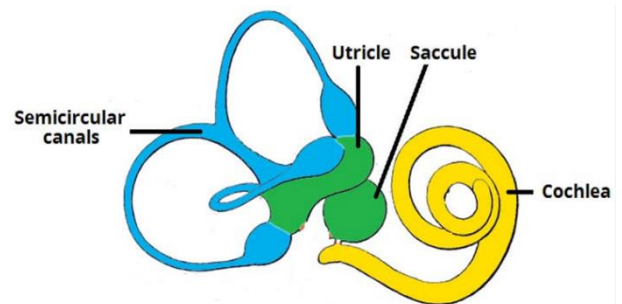

Membranous labyrinth:It is occupied and suspended within the bony labyrinth.

Innervation of the internal ear:The nerve of the inner ear is the vestibulocochlear nerve(VIII)

When it comes to innervation, the cochlear part) nerve carries sensory hearing information after arising from the spiral ganglion.

The vestibular(part) nerve arises from the sensory tissues of the semicircular ducts, utricle, and saccule carries sensory balance in

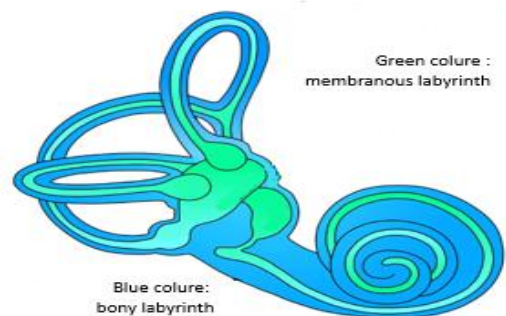
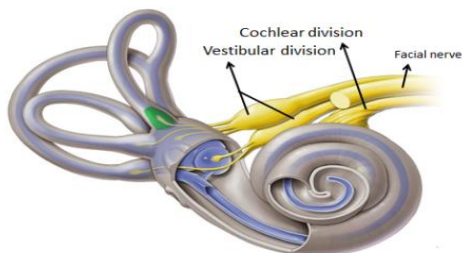
The inner ear (bony labyrinth)



formation

The inner ear (membranous labyrinth)

The innervation is via the vestibulocochlear nerve.



Infections and Otitis Media

Pathogenic organisms can gain entrance to the middle ear by ascending through the auditory tube from the nasal part of the pharynx. Acute infection of the middle ear (otitis media) produces bulging and redness of the tympanic membrane.

Complications of Otitis Media

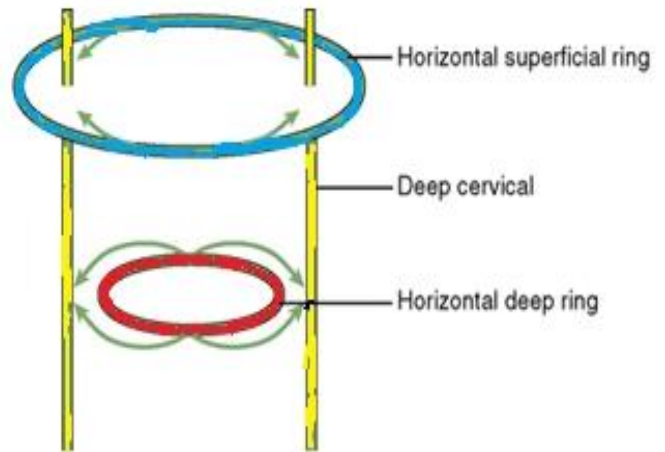
Inadequate treatment of otitis media can result in the spread of the infection into the mastoid antrum and the mastoid air cells (acute mastoiditis). Acute mastoiditis may be followed by the further spread of the organisms beyond the confines of the middle ear. The meninges and the temporal lobe of the brain lie superiorly. A spread of the infection in this direction could produce a meningitis and a cerebral abscess in the temporal lobe. Beyond the medial wall of the middle ear lie the facial nerve and the internal ear. A spread of the infection in this direction can cause a facial nerve palsy and labyrinthitis with vertigo.

LYMPH NODES OF THE HEAD AND NECK

A Knowledge of the routes by which the lymph flows from the head and neck back to the venous system is essential in the understanding how the infection and cancerous cells spread through the lymphatic system. So knowledge of the lymph drainage of an organ or region is of great clinical importance.

The lymph nodes of the head and neck grouped into:

1. Horizontal ring of superficial lymph nodes.
2. Horizontal ring of deep lymph nodes.
3. Two vertical chains of deep cervical lymph nodes.



1) The Superficial Ring of Nodes:

- They surround the neck and head and they arranged into five main groups:

A) Submental Nodes:

They located under chin within the submental triangle and on the surface of myeloid muscle.

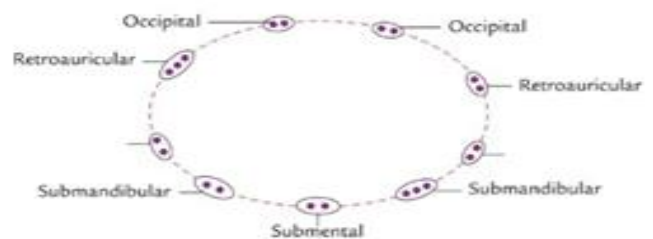
They receive lymph from:

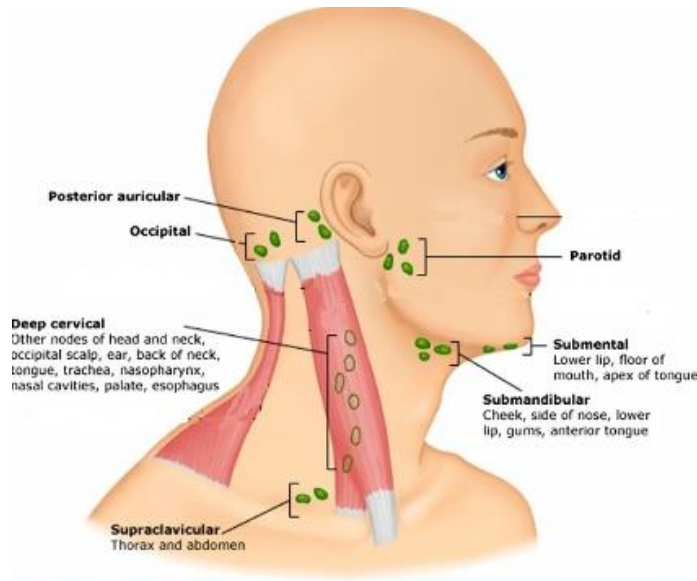
1. Lower lip.
2. Chin.
3. Tip of tongue.
4. The anterior part of the floor of the mouth
5. The lower incisors .

They empty into:

1. Submandible lymph nodes.
2. Or directly to jugulo-omohyoid nodes.

Superficial Ring





B) Submandibular Nodes:

They lie within the submandibular triangle on the submandibular gland. Extension of these nodes on the face called **buccal or facial nodes**.

They receive lymph from:

1. Submental nodes.
2. Cheek.
3. Nose.
4. Upper lip.
5. Maxillary and mandibular teeth(except the lower incisors)teeth.
6. Hard Palate.
7. Posterior part of the floor of the mouth.
8. Tongue (except the tip).

They empty into Deep cervical chain.

The submandibular lymph nodes are commonly enlarged as a result of a pathologic condition of the scalp, face, maxillary sinus, or mouth cavity. One of the most common causes of painful enlargement of these nodes is acute infection of the teeth. Enlargement of these nodes should not be confused with pathologic swelling of the submandibular salivary gland.

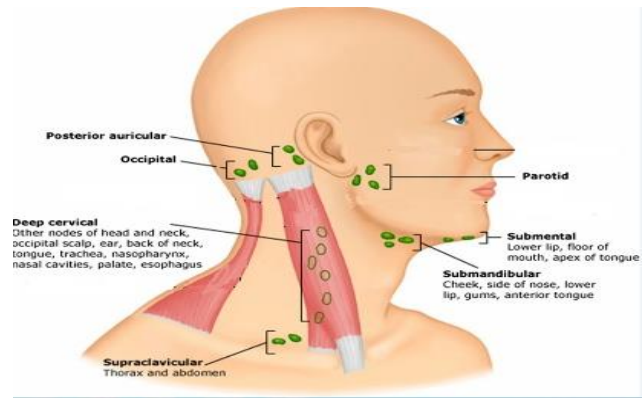
C) Parotid Nodes:

They are located on the capsule of the parotid gland (superficial group) and within the substance of the parotid gland (deep group).

They receive lymph from:

1. Eyelids.
2. Soft Palate.
3. Temple.
4. Posterior part of the Nasal cavity.
5. Auricle.
6. Middle Ear.
7. Zygoma.

They empty into Deep cervical lymph nodes.



D) Retro auricular (Mastoid) nodes:

They lie over the mastoid process and

They receive lymph from the:

1. Scalp.
 2. Auricle.
- **They empty into deep cervical lymph nodes.**

E) Occipital Nodes:

- They lie below the superior nuchal line and they receive lymph for the scalp.
- **They empty into the deep cervical lymph nodes.**

2) Deep Ring of Lymph Nodes:

- They surround and drain the visceral structure of the neck.

They grouped into:

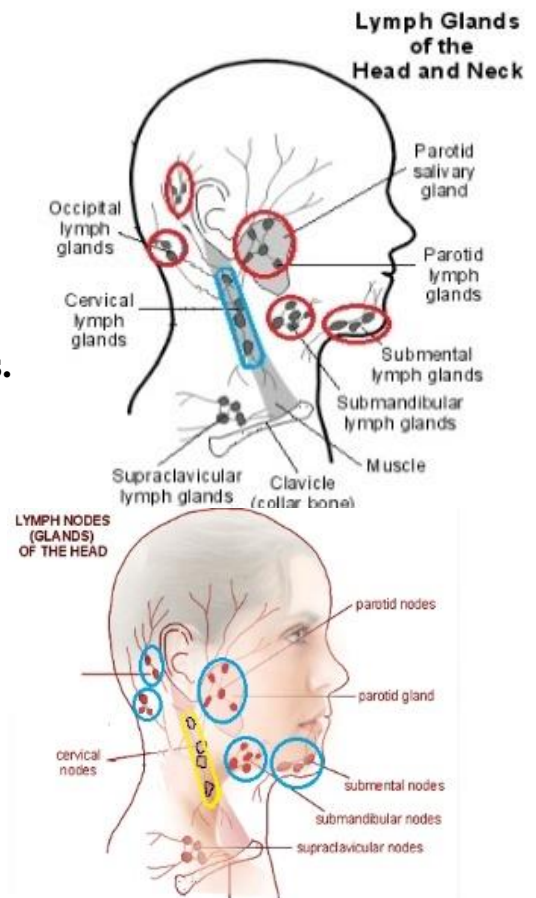
1- Retro Pharyngeal Nodes:

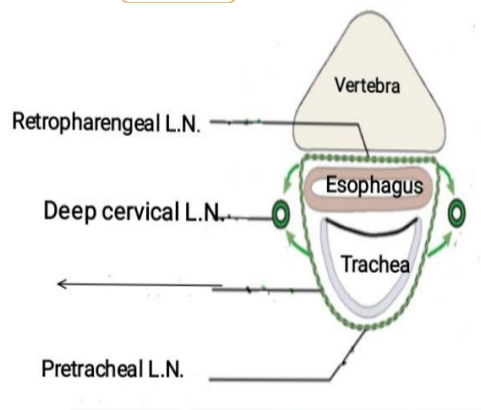
They lie within the retropharyngeal space (located between the posterior wall of the pharynx and the pre vertebral fascia of the vertebral unit).

They receive lymph from the:

- a. Nasal cavity.
- b. Nasopharynx.
- c. Soft palate.
- d. Middle ear.

They empty into Deep cervical lymph nodes.





2- Para tracheal and pre tracheal lymph:

They are located anterior (pre) and lateral (Para) to the trachea.

They receive lymph from:

- Larynx
- trachea.
- Pharynx.
- Esophagus.

They empty into Deep cervical lymph nodes.

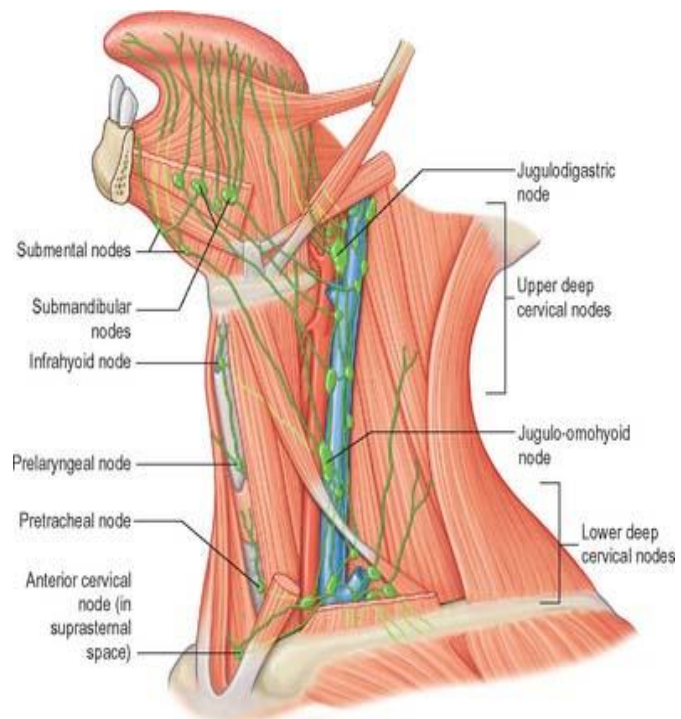
3- Deep Cervical Vertical Chain:

They extend from the base of the skull to the root of the neck and they are parallel to the course of right and left internal jugular veins.

They receive lymph from all the superficial and deep rings of lymph nodes.

They form right and left jugular lymph trunks.

The left jugular trunk joins the thoracic duct or enter the junction of the subclavian and internal jugular veins.



The right jugular trunk joins the subclavian and broncho mediastinal lymph trunk to form a common right lymph duct which empties at the junction between right subclavian vein and right internal jugular vein.

There are two groups of lymph nodes which extend from the deep cervical lymph nodes, **these are:**

A- Jugulo-digastric lymph nodes:

They lie along the posterior belly of digastric muscle

(below and behind the angle of the jaw), is mainly concerned with drainage of the tonsil and the tongue.

This lymph node is sometimes called the “principal node of the tongue” because it receives lymph from the lateral portions of the anterior two thirds of the tongue. Sometimes it is called the “tonsillar node” because it receives lymph from the pharyngeal and palatine tonsils. It is also called the “sentinel node” because it receives lymph from other nodes serving the submandibular and submental regions.

B. Jugulo-omohyoid lymph node

They lie below the inferior belly of omohyoid muscle is mainly associated with drainage of the tongue.

Also there are group of superficial lymph nodes :

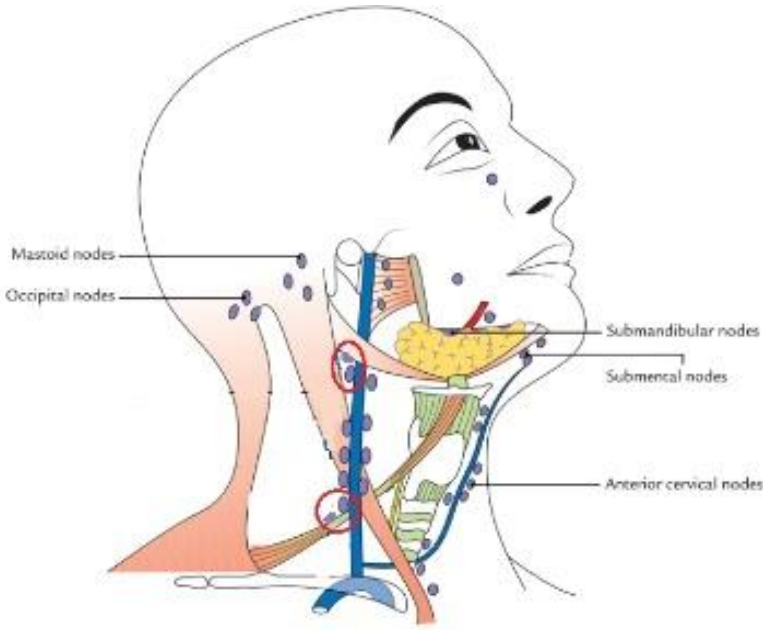
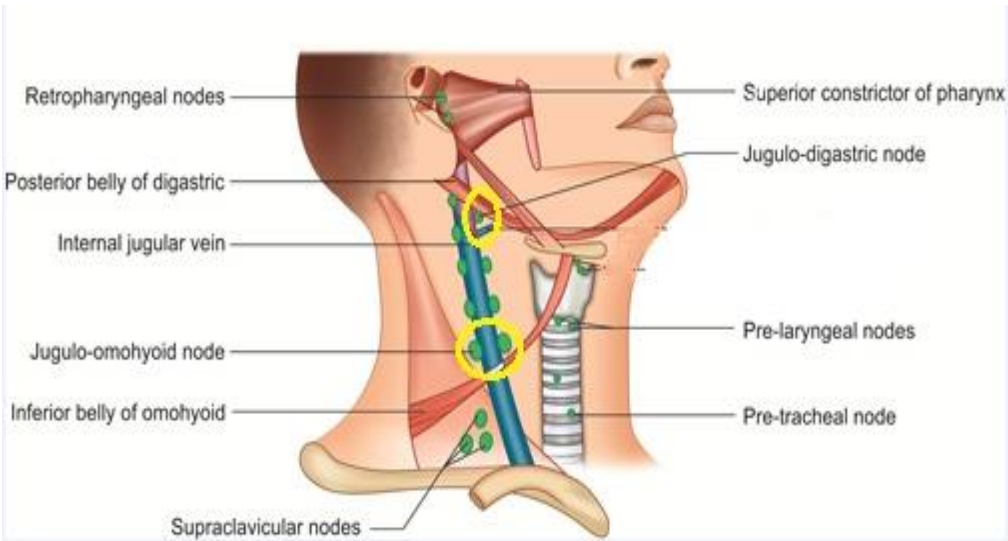
Anterior cervical nodes: These lie along the course of the anterior jugular veins in the front of the neck. They receive lymph from the skin and superficial tissues of the front of the neck.

Superficial cervical nodes: These lie along the course of the external jugular vein on the side of the neck. They drain lymph from the skin over side of neck.

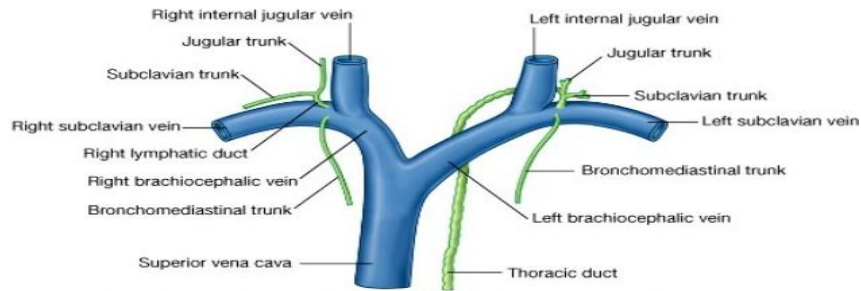
Termination of lymphatic vessel

The efferent vessels from the deep cervical lymph nodes converge to form the right and left jugular lymphatic trunks.

The left jugular trunk joins the thoracic duct which enters the junction of left subclavian vein and left internal jugular vein



Termination

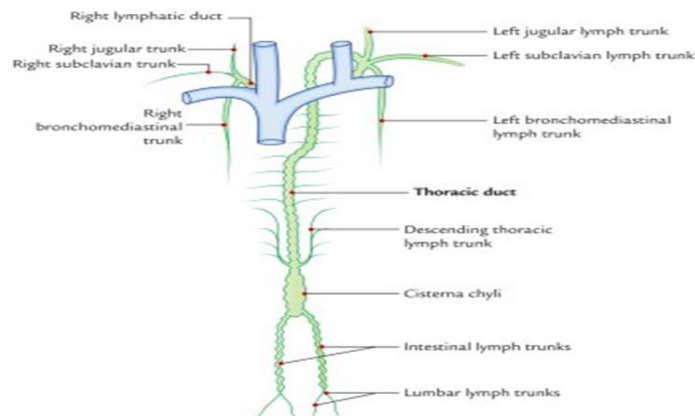


12

The right jugular trunk joins right subclavian trunk and right bronchomediastinal lymph trunk to form the right lymphatic duct which empty at the junction between the right subclavian vein and right internal jugular vein.

Thoracic duct

The thoracic duct collects lymph from the left side of the body and regions of the right side of the body below the thorax or (diaphragm). It begins at the cisterna chyli, an enlarged region of the lymphatic vessel that forms following the union of the intestinal trunk and right and left lumbar trunks. It empty at the junction between the left subclavian vein and left internal jugular vein.



The left jugular , left subclavian and left bronchomediastinal lymph trunks all empty into the thoracic duct.

Right lymphatic duct

The right jugular trunk joins right subclavian trunk and right bronchomediastinal lymph trunk to form the right lymphatic duct which empty at the junction between the right subclavian vein and right internal jugular vein

Lymphatic trunks

A lymphatic trunk is any large lymph vessel that forms from the convergence of many efferent lymph vessels each of which occurs in pairs left and right, for each side of the body.

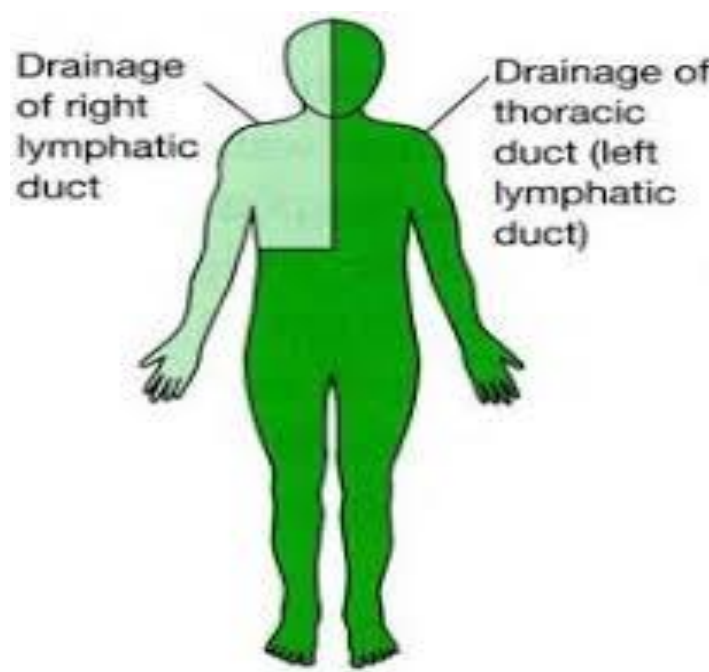
Jugular lymph trunks, located in the neck, drain lymph fluid from the head and neck.

Subclavian lymph trunks, located beneath the clavicle, drain lymph fluid from the upper limbs.

Bronchomediastinal lymph trunks, located in the chest, drain lymph fluid from the lungs, heart, trachea, mediastinal, and mammary glands.

Lumber lymph trunks, drain lymph from the lower limb.

Lymph nodes of a healthy individual are soft, non palpable structures. However, infection, inflammation, and carcinomatous involvement of areas drained by lymph nodes cause these structures to become palpable, swollen, hard, and maybe even painful. Diseased states of the oral cavity will most probably be reflected in the submental and submandibular lymph nodes.



FASCIAL SPACES OF THE FACE AND NECK

Fascial spaces in the cervical fascia are important to the clinician because they can provide passageways for the spread of infections. They are potential spaces are filled with tissue fluid or loose connective tissue that can readily break down when invaded by infection. The fascial spaces are important because organisms originating in the mouth, teeth, pharynx, and esophagus can spread among the fascial spaces downward into the superior mediastinum of the thorax.

Submental space:

The submental space is located under the chin in the midline between the mylohyoid muscle superiorly, the platysma muscle, deep cervical fascia, superficial fascia and skin inferiorly, laterally it is bounded by anterior bellies of digastric muscles.

It contains submental lymph nodes and the anterior jugular vein.

Infection can started in the space from the mandibular anterior teeth or from the spread of infection from submandibular and sublingual spaces.

Sublingual Space:

The boundaries are:

The mylohyoid muscle inferiorly.

The mucosa of the floor of mouth and the tongue superiorly.

The medial surface of the mandible anterolaterally.

The sublingual space communicates posteriorly around the posterior free border of the mylohyoid muscle with the submandibular space.

It contains: Sublingual gland, deep part of submandibular gland, submandibular duct, lingual nerve, hypoglossal nerves and sublingual artery and vein.

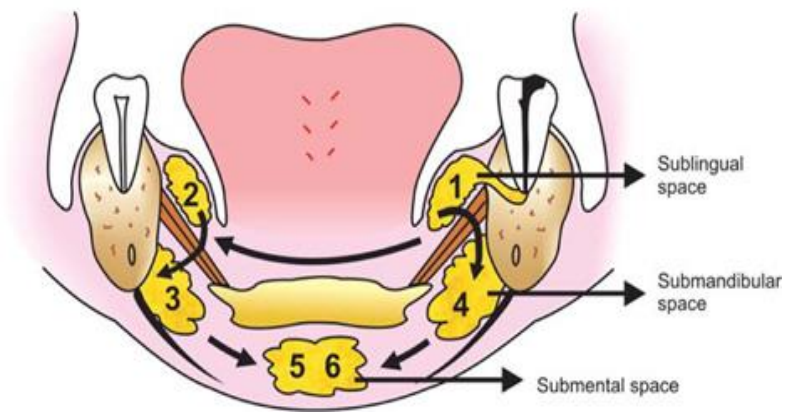
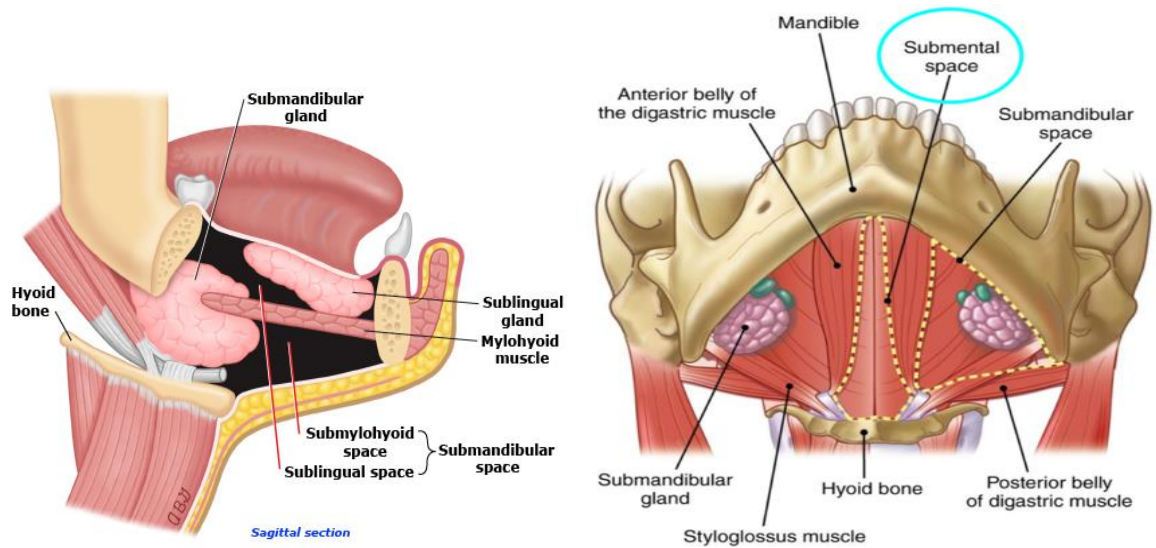
Submandibular Space:

It is located below the lower border of the mandible.

The anatomic boundaries of each submandibular space are:

The mylohyoid muscle superiorly and medially; the skin, superficial fascia, platysma muscle and superficial layer of the deep cervical fascia inferiorly and laterally. The anterior and posterior bellies of digastric muscle form the anterior and posterior boundaries respectively.

It communicates to the submental and sublingual spaces. It contains: the submandibular gland, which largely fills the space, branches of the facial and lingual artery, lymph nodes, cranial nerve XII, and nerve to mylohyoid muscle.



Masticator Space

The masticator space contains the muscles of mastication, the maxillary artery and its branches, the mandibular nerve and its branches, connective tissue, and much of the buccal fat pad. The space is the result of the splitting of the investing fascia at the inferior border of the mandible to enclose the medial and lateral pterygoid and masseter muscles as well as the inferior border of the temporalis muscle.

Salivary gland tumors, abscesses, hemangiomas, and metastatic extensions of squamous cell carcinoma, especially from the floor of the mouth, tonsillar fossa, and nasopharynx, can extend into the masticator space. Persons suspected of having masticator space infections are very ill and need immediate medical attention. This space divided into three spaces:

A- Pterygomandibular Space:

The pterygomandibular space is bounded by the mandible laterally and medially and inferiorly by the medial pterygoid muscle. The posterior border is formed by the parotid gland and anteriorly by the pterygomandibular raphe. The inferior alveolar and lingual nerves, with the sphenomandibular ligament and inferior alveolar vessels are of particular importance in the administration of local anesthesia.

B- Submasseteric space (masseteric space):

It is a potential space in the face over the angle of the jaw, and is paired on each side. The boundaries of each submasseteric space are:

Anteriorly: the anterior margin of the masseter muscle

Posteriorly: the parotid gland

Superiorly: the zygomatic arch

Inferiorly: the inferior border of the mandible

Medially: the lateral surface of the mandibular ramus.

Laterally: the masseter muscle

C- Temporal space:

The temporal space is a potential space in the side of the head, and is paired on either side. It is divided into two parts:

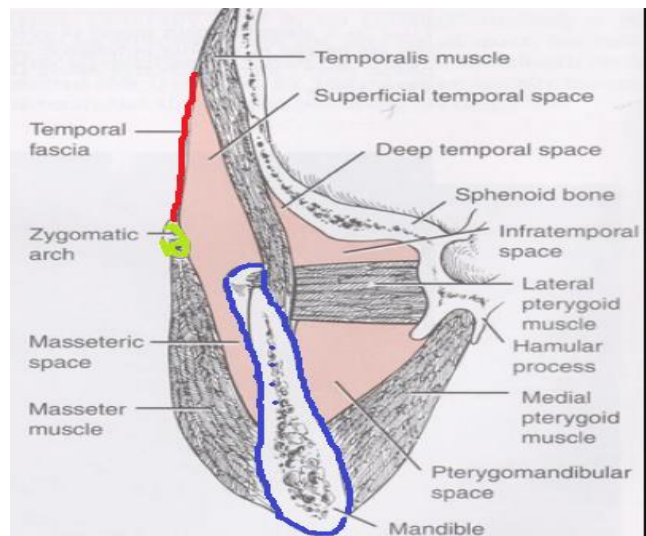
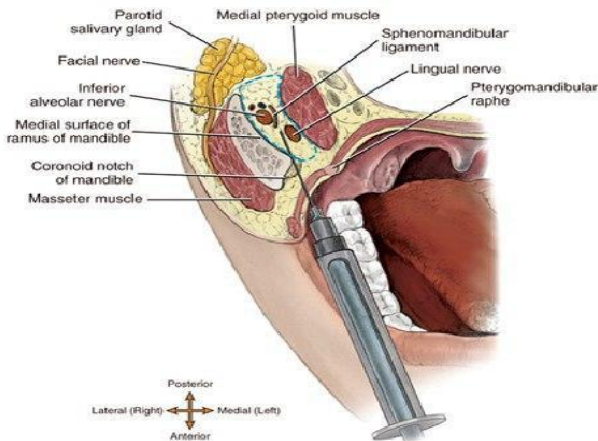
1- Deep temporal space located between the temporalis muscle and the temporal bone.

2- Superficial temporal space located between the temporalis muscle and the temporalis fascia.

The boundaries of the temporal space are:

Superior: Temporal lines.

Inferior: Zygomatic arch.



Retropharyngeal Space (Retrovisceral Space):

The retropharyngeal space lies in the posterior portion of the visceral compartment between the buccopharyngeal fascia covering the pharynx/esophagus anteriorly and the alar fascia (*The alar fascia is an fascial layer extends between the carotid sheaths*) posteriorly. It extends from the base of the skulls superiorly to the mediastinum inferiorly. Infections of and about the oral cavity may dissect into this space and if left untreated, may breach the thin alar fascia and enter the *danger space*

Danger Space:

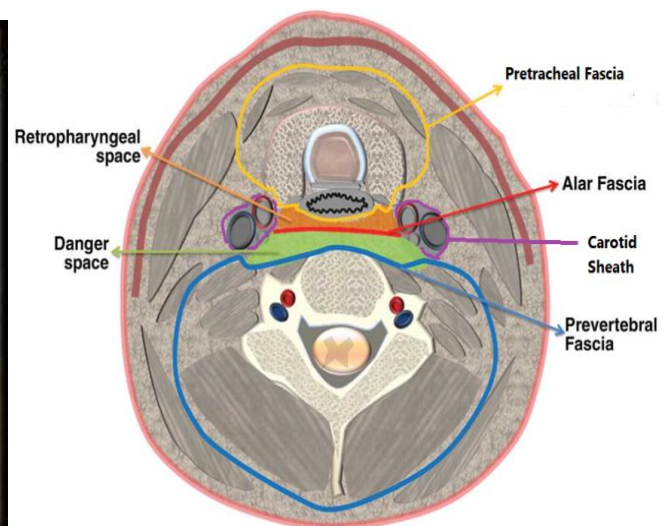
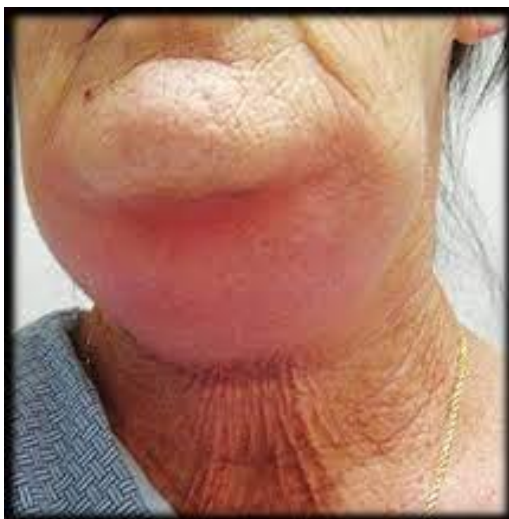The danger space lies behind the alar fascia in the pocket formed between the alar fascia and the prevertebral fascia passing just anterior to the vertebral

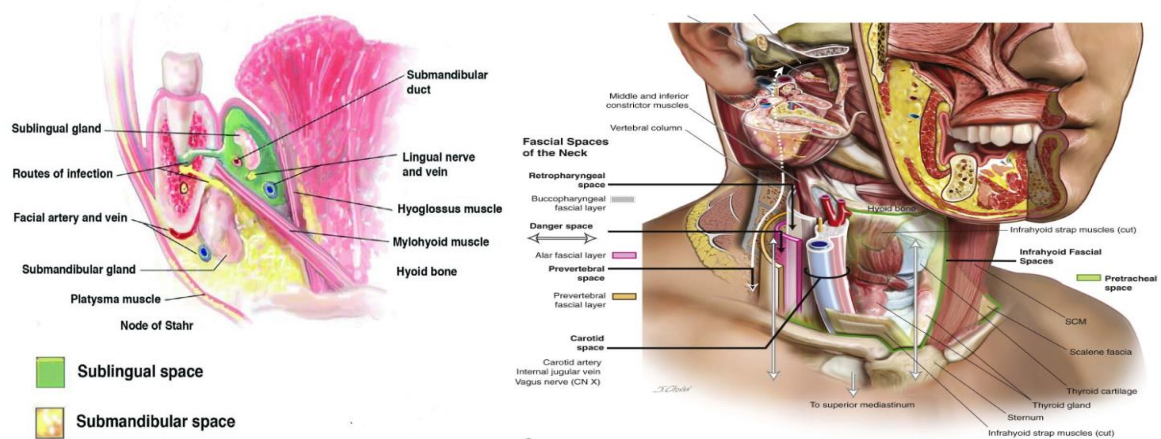
bodies. The “danger space,” extends from the base of the skull to the diaphragm and is a closed space. It appears therefore, that infections located in the danger space result from infectious dissections through the alar fascia from the retropharyngeal (retrovisceral) space. Therefore, this space is of particular importance to the clinician because it is the pathway for the transmission of infections from the head and neck into the mediastinum. Spread of infection via this route can be life-threatening.

Pretracheal Space:

The pretracheal space located in the visceral compartment of the neck surrounds the trachea as it lies against the esophagus. It is limited superiorly by the infrahyoid attachments to the thyroid cartilage and hyoid bone, and inferiorly it continues into the mediastinum.

Ludwig’s angina is an acute infection of the submandibular fascial space and is commonly secondary to dental infection, most commonly involve the lower molar teeth. The infection spreads medially from the mandible into the submandibular and masticatory spaces and pushes the tongue forward and upward. Further spread downward may involve the visceral space (pretracheal space) and lead to edema of the vocal cords and airway obstruction.





BUCCAL FAT PAD:

The buccal fat pad is a simple lobulated mass consisting of a central body and 4 extensions: buccal, pterygoid, pterygopalatine, and temporal. The body is situated along the posterior maxilla and superior fibers of the buccinator. The buccal extension lies superficially and is responsible for contour of the cheek.

Buccal fat pad has many possible functions: filling and allowing slippage of fascial spaces between muscles; enhancement of intermuscular motion, separating muscles of mastication from one another; to counteract negative pressure during suction in the newborn; protection and cushion of neurovascular bundles from injuries; it also contains a rich venous network involved in exoendocranial blood flow through the pterygoid plexus.

The following clinical uses of the buccal fat pad are: closure of oroantral communication/orantral fistula, closure of postexcision defects, closure of mucosal defects, closure of primary clefts, midline secondary clefts, in TMJ reconstruction, in oral submucous fibrosis.

Blood supply:

The Buccal and deep temporal branches of the maxillary artery, transverse facial branches of the superficial temporal artery and branches of the facial artery supplies the buccal fat pad.

BRAIN

- 1- one of largest organs in body: 1300-1400 gm.
- 2- one of most metabolically active organs in body.
- 3- comprises only 2% of total body weight it yet.
- 4- gets 15% of blood.
- 5- consumes 20% of our oxygen need at rest (more when mentally active).
- 6- (1-2) min interruption of blood flow may impair brain cells.
- 7- (>4 min w/o) oxygen permanent damage.
- 8- besides O₂ must get continuous supply of glucose decrease in glucose: dizziness , convulsions , unconsciousness.

Topography of the brain:

The brain divided into three major divisions these are:

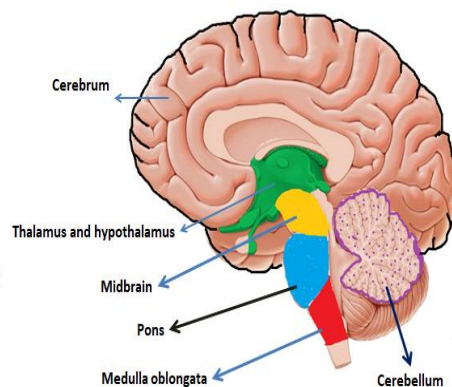
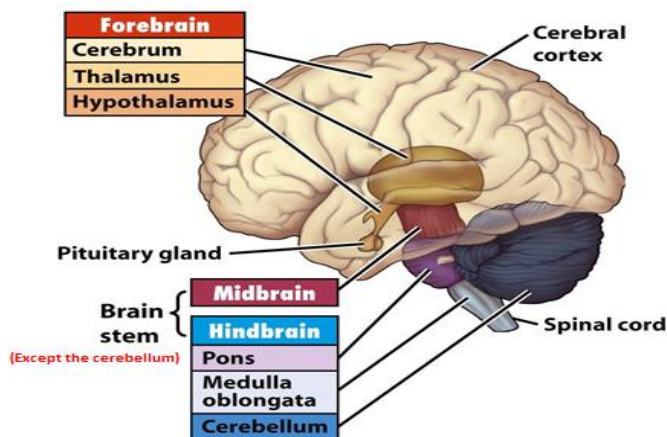
Forebrain (Prosencephalon) which include:

Diencephalon(thalamus + hypothalamus) and telencephalon or cerebrum

Midbrain (Mesencephalon)

Hindbrain (Rhombencephalon) which include medulla oblongata, pons and cerebellum

Brain stem: means the medulla oblongata, pons and midbrain it is the parts of the brain which remains after the cerebral hemispheres and cerebellum are removed.



Structurally the nervous system divided into two main parts:

Central nervous system (CNS) consist of the brain and spinal cord.

The peripheral nervous system (PNS) which consist of 12 pairs of cranial nerves and 31 pairs of spinal nerves and their associated ganglia.

Functionally the nervous system divided into:

- 1-Autonomic nervous system (sympathetic and parasympathetic).
- 2- Somatic nervous system.

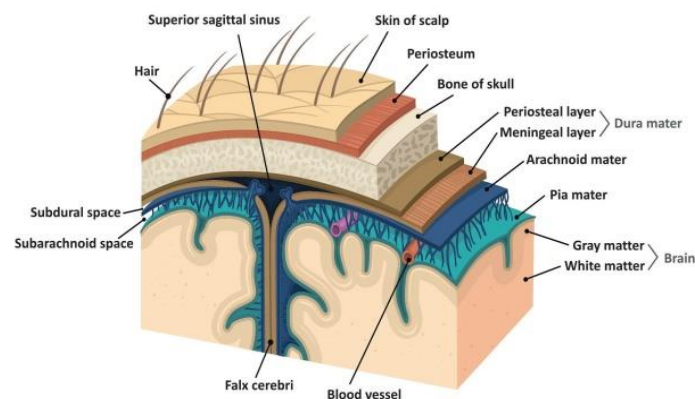
The interior of the CNS is organized into gray and white mater. Gray mater consists of nerve cells and their proximal processes embedded in neuroglia.

White mater consist of nerve fibers embedded in neuroglia. The PNS consist of bundles of nerve fibers or axons conduct information to and from CNS.

CNS is well protected by the bones of skull and vertebral column and they suspended in fluid called cerebrospinal fluid (CSF), while the PNS although surrounded by fibrous sheath they are unprotected and are commonly damaged by trauma.

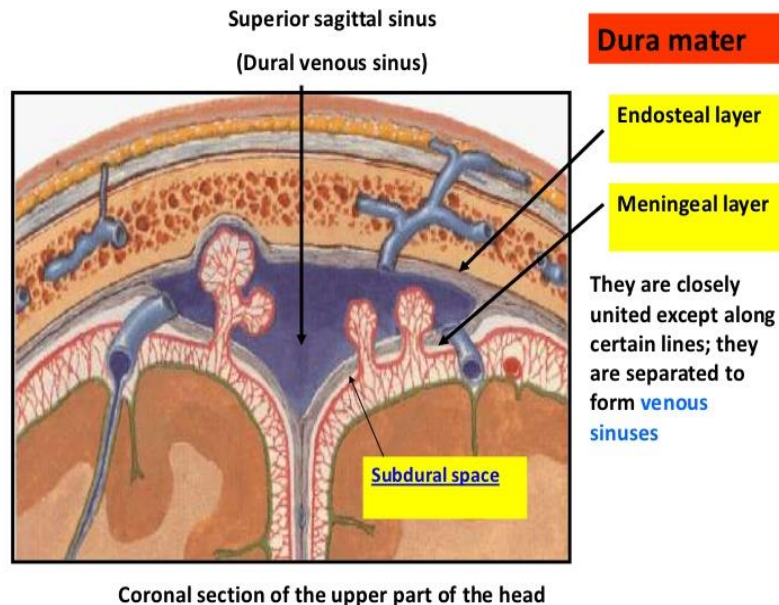
MENINGES

The brain and spinal cord are surrounded by three membranes or meninges: the dura mater, the arachnoid mater and the pia mater.



Dura Mater:

The dura mater of the brain is formed by two layers Endosteal and Meningeal layers. These are closely united except along certain lines where they separate to form venous sinuses.



The meningeal layer sends inward four septa, which divide the cranial cavity into freely communicating spaces that lodge the subdivisions of the brain .

These septa are:

Falx cerebri

Tentorium cerebelli

Diaphragma sella

Falx cerebelli

The function of these septa is to restrict the displacement of the brain when the head is moved.

Falx cerebri:

The falx cerebri is a sickle-shaped fold of dura mater that lies in the midline between the two cerebral hemispheres. Its narrow anterior end is attached to the crista galli. Its broad posterior part blends in the midline with the upper surface of the tentorium cerebelli.

Its superior margin is attached at midline to the internal surface of skull, as far back as the internal occipital protuberance. While its inferior margin is free.

The superior sagittal sinus runs in its upper fixed margin, the inferior sagittal sinus runs in its lower concave free margin, and the straight sinus runs along its attachment to the tentorium cerebelli.



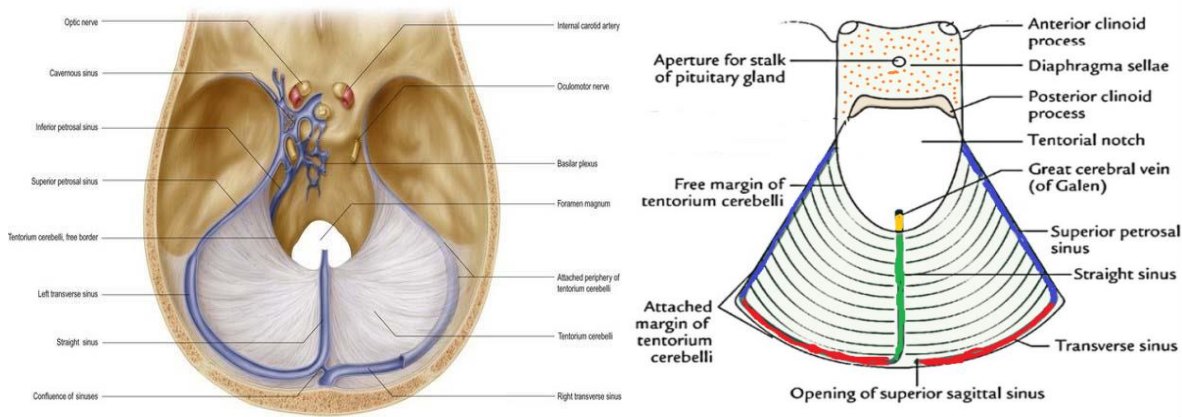
Tentorium cerebelli

The tentorium cerebelli is a crescent-shaped fold of dura mater that roofs over the posterior cranial fossa. It covers the upper surface of the cerebellum and supports the occipital lobes of the cerebral hemispheres.

In the anterior edge there is a gap, the tentoria notch, for the passage of the midbrain, which produces an inner free border and an outer attached or fixed border.

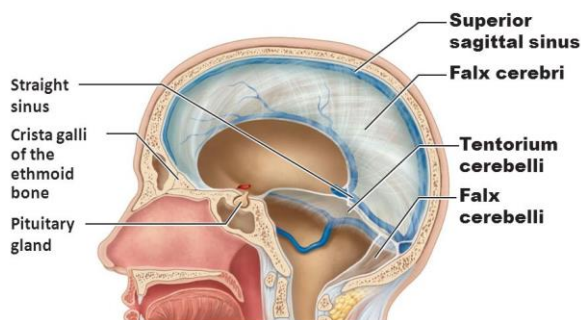
The fixed border is attached to the posterior clinoid processes, the superior borders of the petrous bones, and the margins of the grooves for the transverse sinuses on the occipital bone. The free border runs forward at its two ends attached to the anterior clinoid process.

The falx cerebri and the falx cerebelli are attached to the upper and lower surfaces of the tentorium, respectively. The straight sinus runs along its attachment to the falx cerebri, the superior petrosal sinus runs along its attachment to the petrous bone, and the transverse sinus runs along its attachment to the occipital bone.



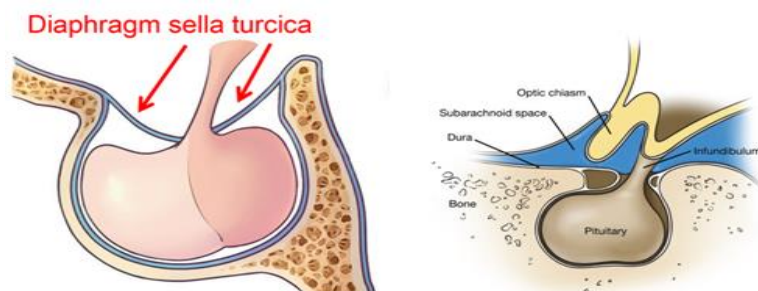
Falx cerebelli:

The falx cerebelli, a small, sickle-shaped fold of dura mater attached to the internal occipital crest projects forward between the two cerebellar hemispheres. Its posterior fixed margin contains the occipital sinus.



Diaphragma sellae:

The diaphragma sellae is a small, circular fold of dura mater that forms the roof for the sella turcica. A small opening in its center allows passage of the stalk of the hypophysis cerebri.



Dural Nerve Supply

Branches of the trigeminal, vagus, and the first three cervical spinal nerves and branches from the sympathetic trunk pass to the dura. The dura possesses numerous sensory endings that are sensitive to stretching, which produce the sensation of headache.

Dural Arterial Supply

Numerous arteries supply the dura mater from the internal carotid, maxillary, ascending pharyngeal, occipital and vertebral arteries.

From the clinical standpoint, the most important is the middle meningeal artery, which can be damaged in head injuries.

The middle meningeal vein follows the branches of the middle meningeal artery and drains into the pterygoid venous plexus.

VENOUS SINUSES OF THE BRAIN

They are venous channels situated between the endosteal and meningeal layers of the dura mater. They drain into the internal jugular veins in the neck.

Emissary veins which are also valveless veins connect the venous sinuses with the diploic veins of skull and with the veins of the scalp.

The main function of the venous sinuses are to:

- 1- Receive the venous blood from the brain through the cerebral veins.
- 2- Receive the CSF from the subarachnoid space through the arachnoid villi

Venous sinuses classified into two groups:

Unpaired sinuses include superior and inferior sagittal, straight, occipital, and confluence sinuses.

Paired sinuses which include sphenoparietal cavernous, superior and inferior petrosal transverse and sigmoid sinuses superior sagittal sinus.

The superior sagittal sinus:

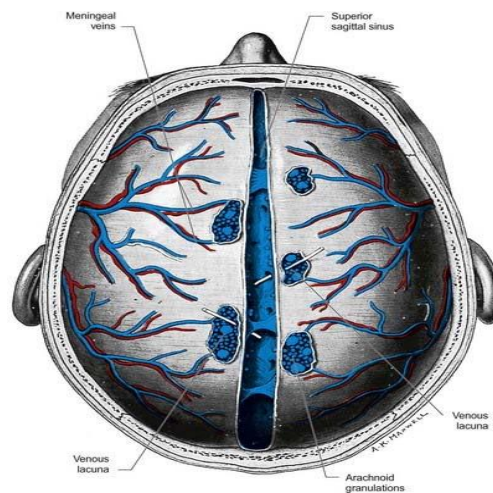
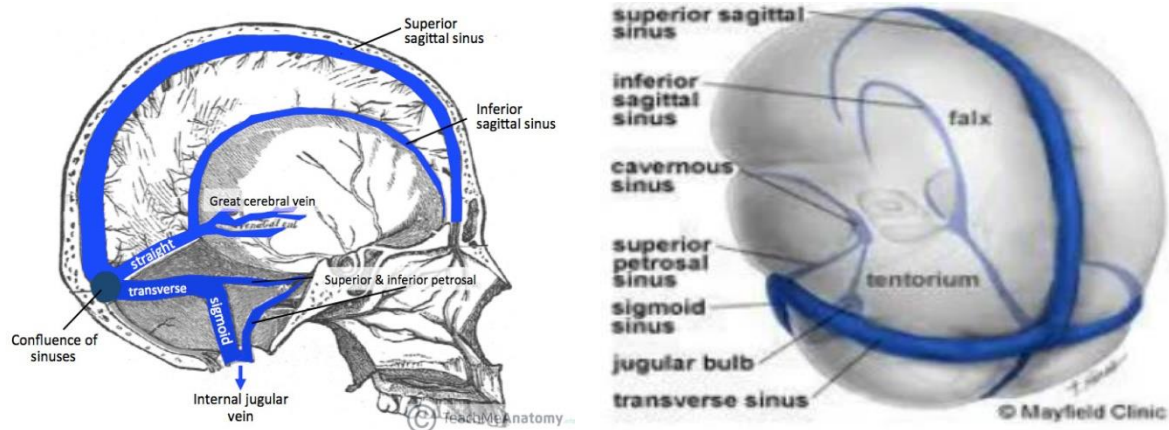
The superior sagittal sinus occupies the upper fixed border of the falx cerebri. It begins anteriorly at the foramen cecum, where it occasionally receives a vein from the nasal cavity.

It runs posteriorly, grooving the vault of the skull; at the internal occipital protuberance, it deviates to one or the other side (usually the right) and becomes continuous with the corresponding transverse sinus.

The sinus communicates through small openings with two or three irregularly shaped venous lacunae on each side.

Numerous arachnoid villi and granulations project into the lacunae, which also receive the diploic and meningeal veins venous lacunae, arachnoid villi and granulations.

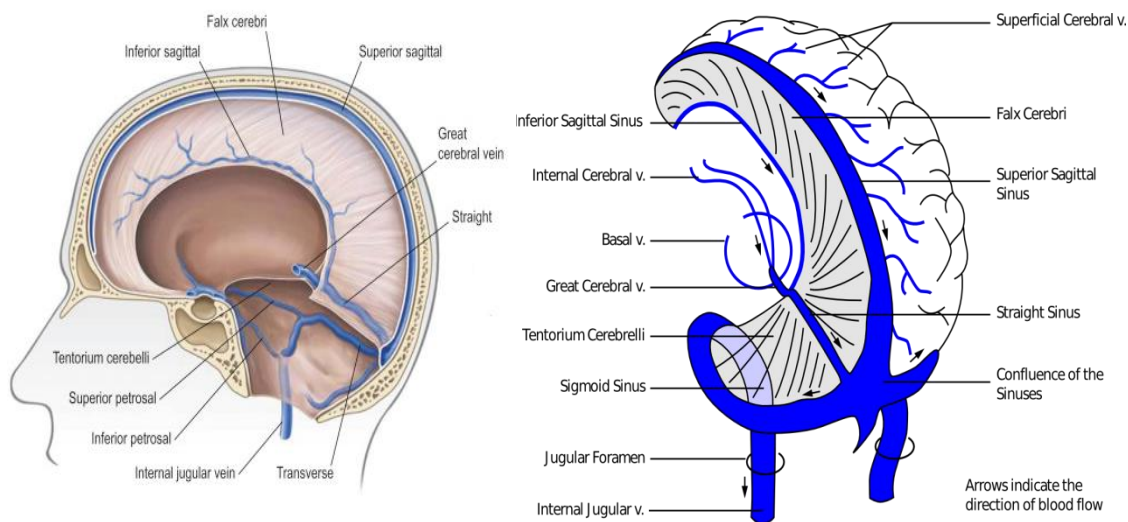
The superior sagittal sinus in its course receives the superior cerebral veins. At the internal occipital protuberance, it is dilated to form the confluence of the sinuses. Here, the superior sagittal sinus usually becomes continuous with the right transverse sinus; it is connected to the opposite transverse sinus and receives the occipital sinus.



The inferior sagittal sinus:

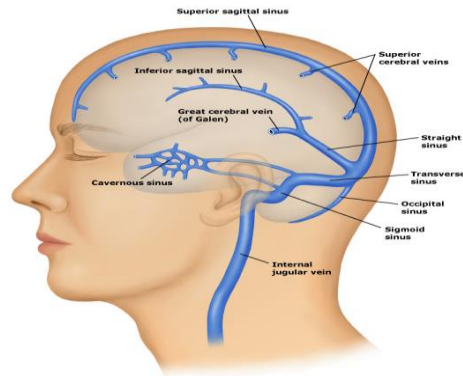
The inferior sagittal sinus occupies the free lower margin of the falx cerebri. It runs backward and joins the great cerebral vein at the free margin of the tentorium cerebelli to form the straight sinus. It receives a few cerebral veins from the medial surface of the cerebral hemispheres.

The straight sinus occupies the line of junction of the falx cerebri with the tentorium cerebelli. It is formed by the union of the inferior sagittal sinus with the great cerebral vein. It ends by turning to the left (sometimes to the right) to form the transverse sinus.



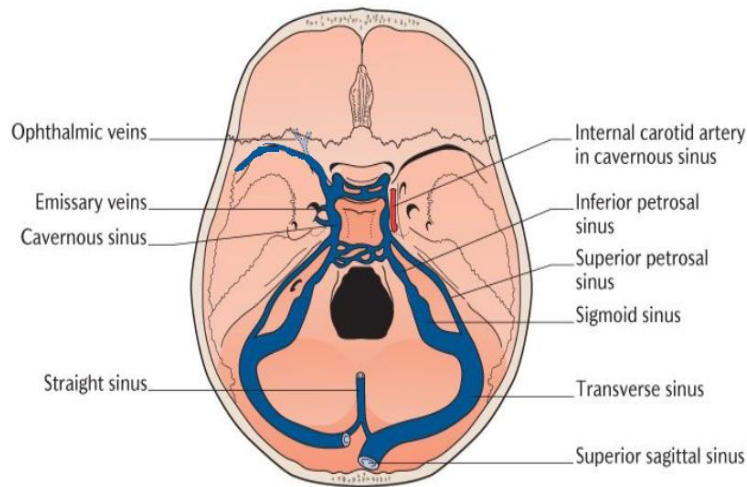
Occipital sinus:

It is a small sinus occupying the attached margin of the falx cerebelli along the internal occipital crest communicates with the vertebral veins and drains into the superior sagittal sinus or confluence of sinuses.



Paired sinuses:

1- The transverse sinuses are paired structures that begin at the internal occipital protuberance. The right sinus is usually continuous with the superior sagittal sinus and the left is continuous with the straight sinus. Each sinus occupies the attached margin of the tentorium cerebelli. The transverse sinuses receive the superior petrosal sinuses. They end by turning downward as the sigmoid sinuses.



2- Sigmoid sinuses:

The sigmoid sinuses are a direct continuation of the transverse sinuses. Each sinus turns downward and medially toward the jugular foramen to become continuous with the superior bulb of the internal jugular vein.

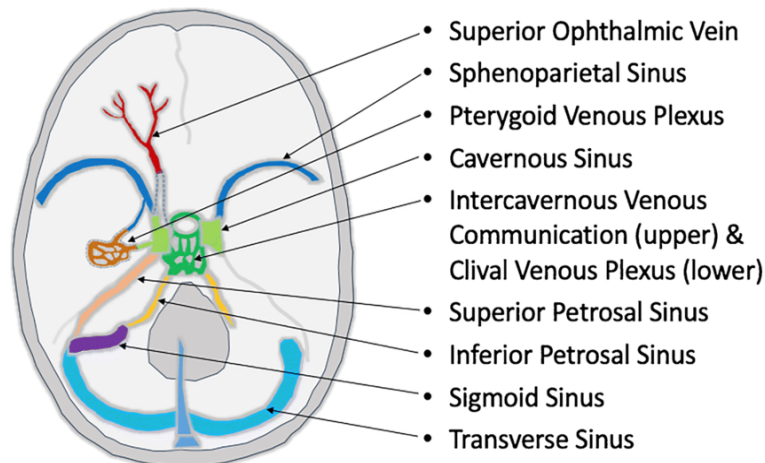
3- The superior and inferior petrosal sinuses:

The superior and inferior petrosal sinuses are small sinuses situated on the superior and inferior borders of the petrous part of the temporal bone on each side of the skull.

Each superior sinus drains the cavernous sinus into the transverse sinus, and each inferior sinus drains the cavernous sinus into the internal jugular vein.

4- Sphenoparietal sinuses:

Small sinus passes along the lesser wing of sphenoid bone.



Basilar sinus:

Consists of plexus of venous channels overlying the dorsum sellae and basilar part of occipital bone.

The cavernous sinuses:

The cavernous sinuses are situated in the middle cranial fossa on each side of the body of the sphenoid bone. Each sinus extends from the superior orbital fissure in front to the apex of the petrous part of the temporal bone behind.

Relations:

Medially: hypophysis (pituitary gland).

Inferiorly : sphenoid air sinus.

Within it:

- 1- Internal carotid artery
- 2- Carotid sympathetic plexuses
- 3- Abducent nerve (6th cranial nerve)

Laterally:

- 1- maxillary nerve
- 2- ophthalmic nerve
- 3- oculomotor nerve
- 4- trochlear nerves

Tributaries and communications:

Anteriorly: Sphenoparietal sinuses, superior and inferior ophthalmic veins

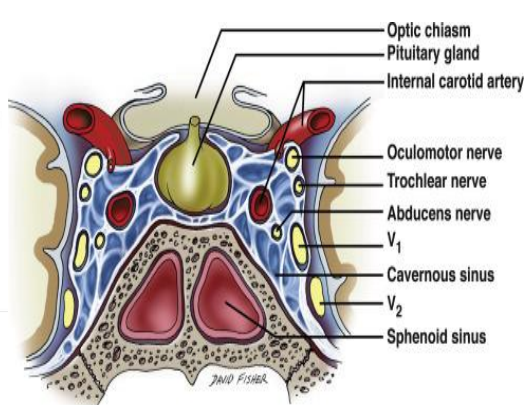
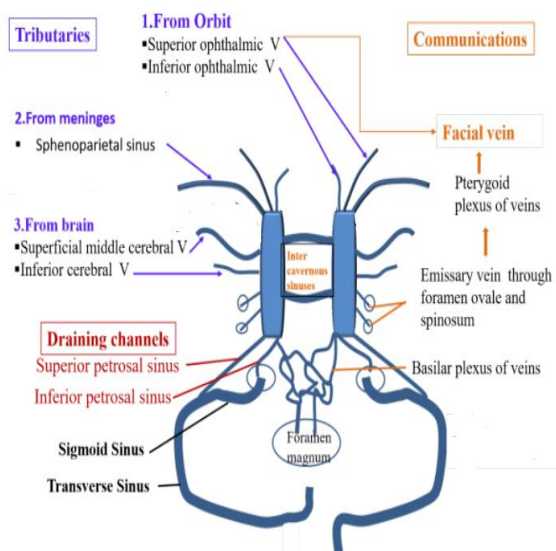
Posteriorly: Superior and inferior petrosal venous sinuses.

Medially: It is connected to its fellow by intercavernous sinuses.

Superiorly: The superficial middle cerebral vein.

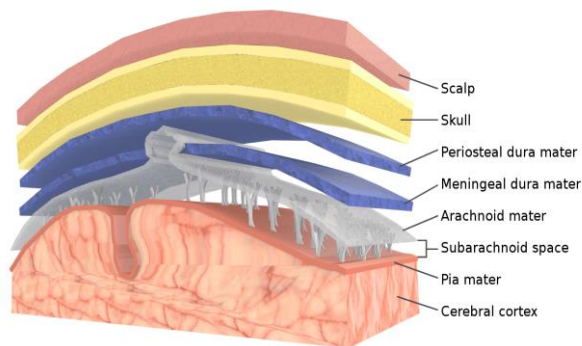
Inferiorly: It communicates through emissary veins with pharyngeal and pterygoid plexus of veins.

Each sinus has an important communication with the facial vein through the superior ophthalmic vein. (This is a route by which infection can travel from the facial skin to the cavernous sinus).



Arachnoid Mater:

The arachnoid mater is a delicate, impermeable membrane covering the brain and lying between the pia mater internally and the dura mater externally. It is separated from the dura by a potential space, the subdural space, filled by a film of fluid. It is separated from the pia by the subarachnoid space, which is filled with cerebrospinal fluid.

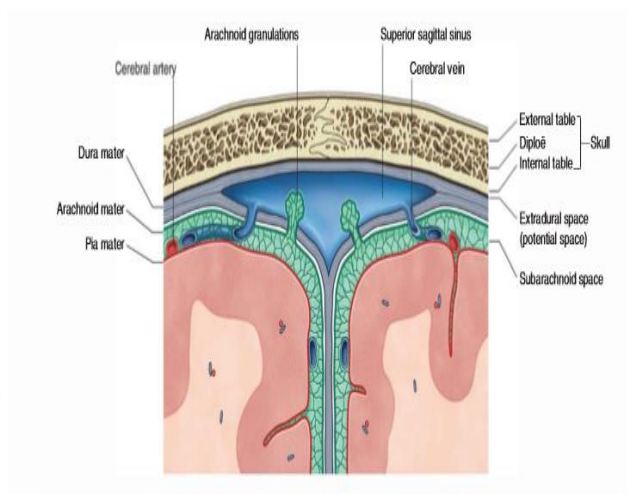
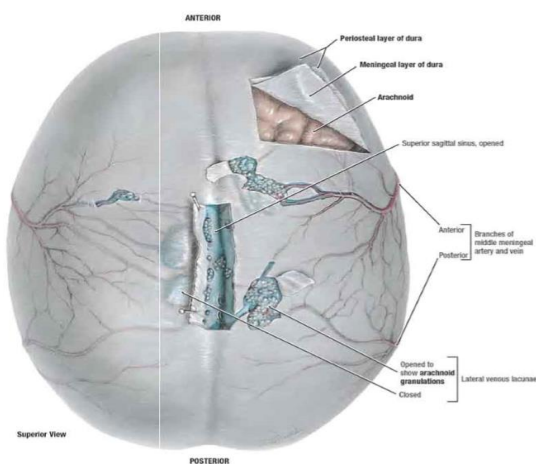


Arachnoid granulation

They are small finger-like processes projected from the arachnoid through apertures (Lateral Lacunae) to the superior sagittal sinus.

The similar but microscopic processes of arachnoid called arachnoid Villi).

There are vulvar structures which permit CSF to pass into the venous system but prevent the reflex of blood.

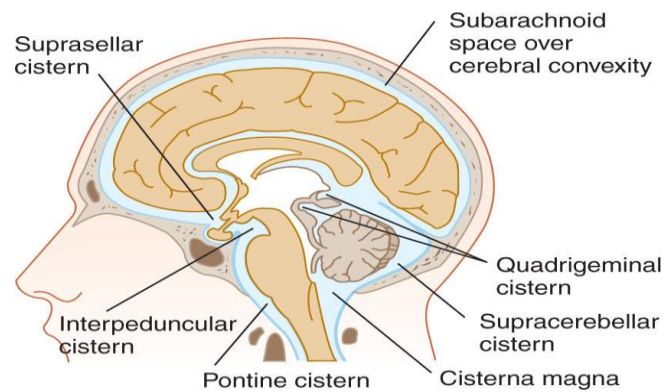


Subarachnoid cisterns

Subarachnoid cisterns are pools of CSF found where the arachnoid and pia mater are widely separated. They are mainly found around the brain stem and cerebellum.

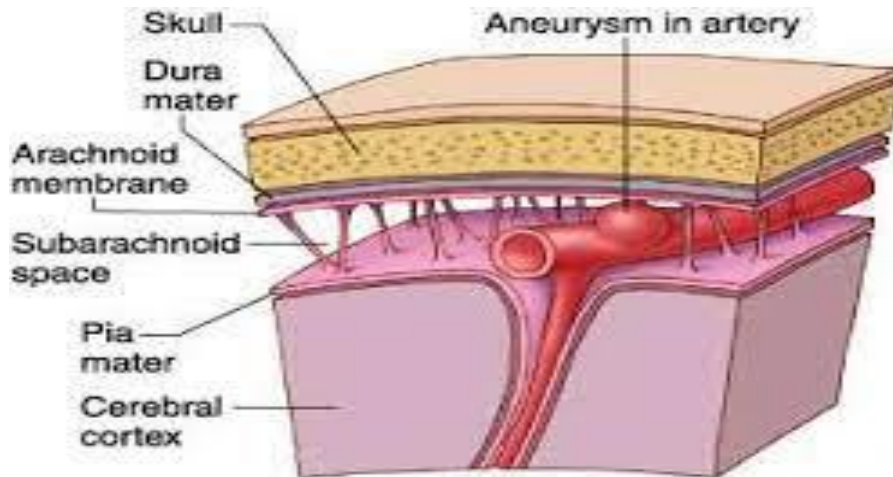
The main cisterns are:

- 1- Cerebellomedullary cistern.
- 2- Pontine cistern.
- 3- Interpeduncular cistern



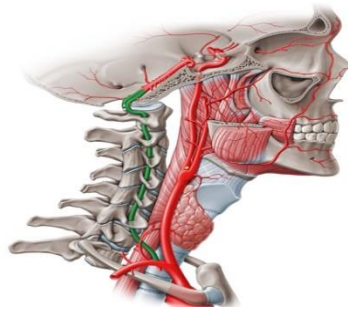
Pia mater:

It is thin membrane covered by flattened mesothelial cells. It closely invests the brain, covering the gyri and descending into deepest sulci. It extends out over the cranial nerves and fuses with their epineurium. The cerebral arteries entering the substance of the brain carry a sheath of pia mater.



BLOOD SUPPLY OF THE BRAIN

The brain is supplied by the two internal carotid and the two vertebral arteries. The four arteries lie within the subarachnoid space, and their branches anastomose on the inferior surface of the brain to form the circle of Willis.



Internal Carotid Artery:

The internal carotid artery begins at the bifurcation of the common carotid artery, where it usually possesses a localized dilatation, called the carotid sinus. It ascends the neck and enters the cranial cavity by passing through the carotid canal. The artery then runs horizontally forward through the cavernous sinus and perforates the dura mater. Then it enters the subarachnoid space by piercing the arachnoid mater and divided into the anterior and middle cerebral arteries.

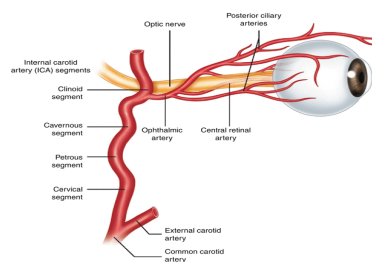
Branches of Internal carotid artery:

- 1• Ophthalmic artery
- 2• The posterior communicating artery

- 3• The choroidal artery
- 4• The anterior cerebral artery
- 5• The middle cerebral artery

1- Ophthalmic artery:

Arises as the artery emerges from the cavernous sinus enters the orbit through the optic canal below and lateral to the optic nerve. It supplies the eye and other orbital structures and its terminal branches supply the frontal area of the scalp, the ethmoid and frontal sinuses and the dorsum of the nose.



2- The posterior communicating artery:

Is a small artery that originates from the internal carotid artery close to its bifurcation. It runs posteriorly to join the posterior cerebral artery.

3- The choroidal artery

small branch originates close to the bifurcation of the internal carotid artery passes posteriorly to end in the choroid plexus.

4- The anterior cerebral artery

It is the smaller terminal branch of the internal carotid artery, runs forward and enters the longitudinal fissure of the cerebrum. Here it joins the anterior cerebral artery of the opposite side by the anterior communicating artery. It curves backward over the corpus callosum and anastomoses with the posterior cerebral artery.

The anterior cerebral artery gives:

- a- Cortical branches. supply all the medial surface of the cerebral cortex as far as the parieto-occipital sulcus.

One of these branches called callosomarginal branch supplies the paracentral lobule also supply a strip of cortex about 1 inch wide on the lateral surface of the hemisphere thus it supply the ‘leg area’ of the precentral gyrus.

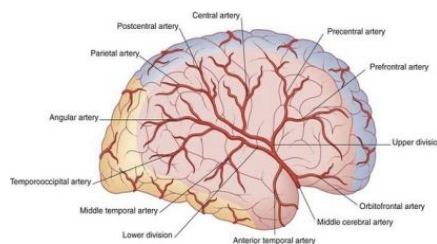
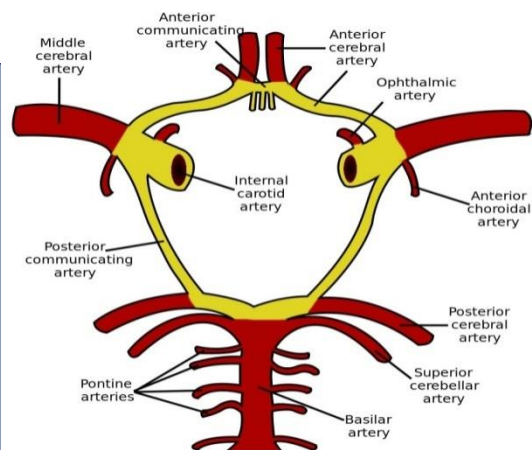
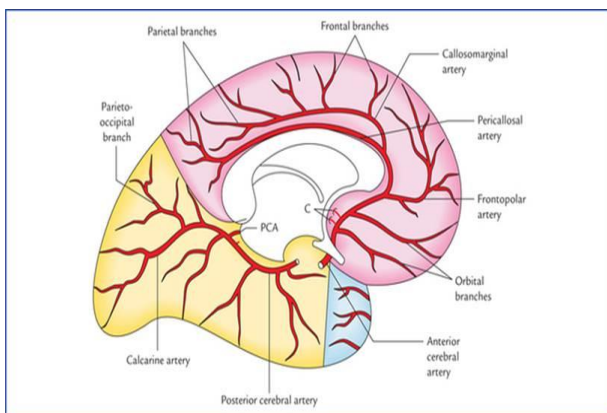
b- Central branches pierce the anterior perforated substance and supply parts of lentiform and caudate nuclei .the internal capsule

5- The middle cerebral artery

The largest branch of the internal carotid artery runs laterally in the lateral sulcus. It gives:

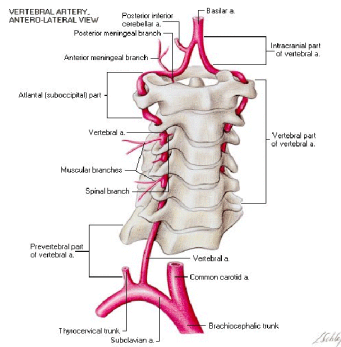
a- Cortical branches supply the entire lateral surface of the hemisphere except a narrow strip superiorly supplied by anterior cerebral artery, the occipital pole and the inferolateral surface of the hemisphere which are supplied by the posterior cerebral artery. This artery thus supplies all the motor area except the leg area.

b- Central branches enter the anterior perforated substance supply the lentiform and caudate nuclei and the internal capsule.



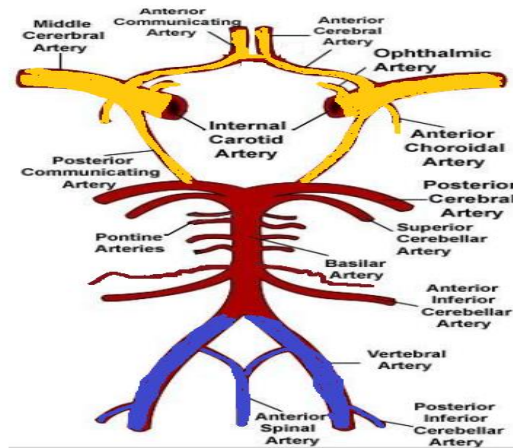
The vertebral artery

A branch of the first part subclavian artery. Ascends upward in the neck by passing through the foramina in the transverse processes of the upper 6 cervical vertebrae. Enters the skull through the foramen magnum and pierces the dura and arachnoid to enter the subarachnoid space.



Branches of the cranial portion:

- 1- The meningeal branches: are small and supply the bone and dura in the posterior cranial fossa.
- 2- The posterior spinal arteries: they are two may arise from the vertebral artery or from the posterior inferior cerebellar artery.
- 3- The anterior spinal artery: it is a single branch formed from the two vertebral arteries descends on the anterior surface of the medulla oblongata and spinal cord along the anterior median fissure.
- 4- The posterior inferior cerebellar artery: the largest branch of the vertebral artery passes on an irregular course between the medulla oblongata and the cerebellum.
- 5- The medullary arteries are very small branches that are distributed to the medulla oblongata.

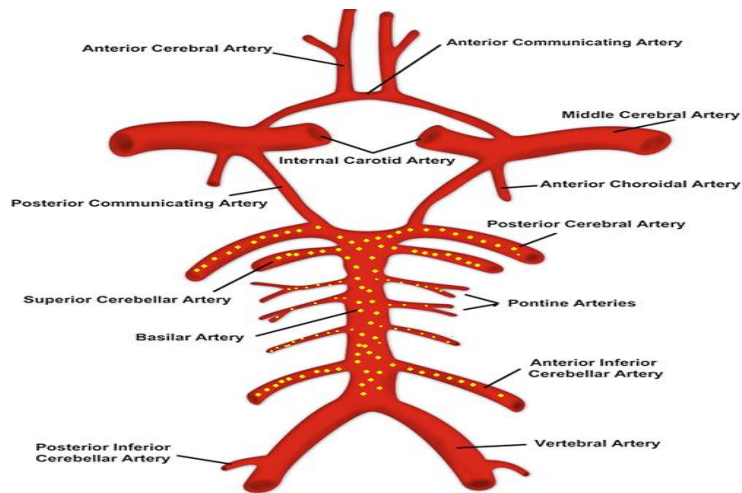


The basilar artery

The basilar artery is formed from the union of both vertebral arteries. It ascends through the basilar groove of the pons, and at the upper border of the pons, it divides into two posterior cerebral arteries.

branches of the basilar artery:

- 1- The anterior inferior cerebellar artery passes posteriorly and laterally to supply the anterior and inferior parts of the cerebellum.
- 2- The labyrinthine artery is a long slender narrow artery that accompanies the facial and vestibulocochlear nerves into the internal acoustic meatus and supplies the internal ear.
- 3- The pontine arteries are numerous small arteries that enter the substance of the pons.
- 4- The superior cerebellar artery winds around the cerebral peduncle and supplies the superior part of the cerebellum. It also supplies the pons and the pineal gland.
- 5- The posterior cerebral arteries are the terminal branches of the basilar artery. They curve backward and laterally around the midbrain and are joined by the posterior communicating artery of the internal carotid artery. They give:
 - a- Cortical branches
 - b- The central branches
 - c- The choroidal branches



The circulus arteriosus((circle of Willis)):

Lies in the interpeduncular fossa at the base of the brain. It is formed by the anastomosis between the two internal carotid arteries and the two vertebral arteries .The circle of Willis is a part of the cerebral circulation and is composed of the following arteries:

Anterior cerebral artery (left and right)

Anterior communicating artery

Internal carotid artery (left and right)

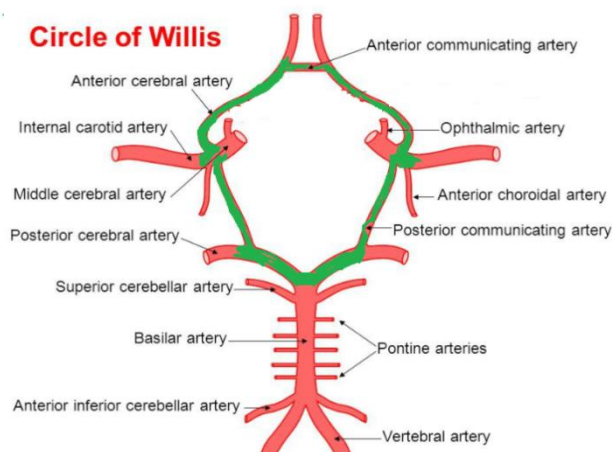
Posterior cerebral artery (left and right)

Posterior communicating artery (left and right)

The circle of willis is an important means of collateral circulation in the event of gradual obstruction of one of the major arteries forming the circle.

Function of Circle of Willis:

The circle of Willis acts to provide collateral blood flow between the anterior and posterior circulations of the brain, protecting against ischemia in the event of vessel disease or damage in one or more areas.



Veins of the brain

The veins of the brain emerge from the brain and lie in the subarachnoid space they pierce the arachnoid mater and meningeal layer of the dura and drain into the cranial venous sinuses .The external cerebral veins:

Superior cerebral veins.

Superficial middle cerebral vein.

Deep middle cerebral vein.

Basal vein.

Great cerebral vein

STROKE (Cerebrovascular Accident) CVA:

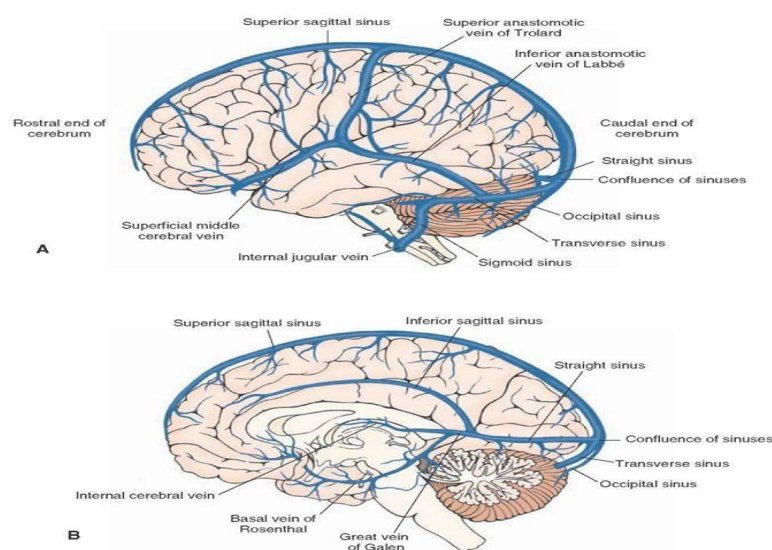
Cerebral tissue requires a constant blood supply and consequently, interruptions in blood flow (ischemia) .If the interruption is longer than 1 hour, the area supplied dies(infarction)and permanent neurological disorder or stroke results.

Interruptions in cerebral flow result from :

1- Blockage caused by thrombus.

2- Hemorrhage of cerebral vessels.

The nature of the stroke is dependent upon the extent of the infarct and the cerebral area affected. For example ,if precentral cortex(motor area) is affected, paralysis of the muscles of contralateral side occurs. While the damage of the left motor speech area(Brocas area) results in **motor aphasia**, an inability to articulate. Damage to the left sensory area(Wernickes area) result in **sensory aphasia** , a loss of language fluency.



CEREBRUM

It is the largest part of the brain. It is composed of two cerebral hemispheres separated by a deep sagittal fissure which contains the sickle-shaped fold of dura mater, the falx cerebri and the anterior cerebral vessels. In the depth of the fissure the corpus callosum connects the two hemispheres.

Each hemisphere has three surfaces:

- 1- Superolateral surface convex and lies in contact with the roof and sides of the skull.
- 2- Medial surface flat and lies in contact with the falx cerebri.
- 3- Inferior surface lies in contact with the floor of anterior and middle cranial fossae and rests posteriorly on the tentorium cerebelli.

In order to increase the surface area of the cerebral cortex the surface of each hemisphere is thrown into folds or gyri which are separated from each other by fissures or sulci.

Each hemisphere is divided into 4 lobes by 3 main sulci, these sulci are the central, lateral, and parieto-occipital. These divide each hemisphere into frontal, parietal, temporal and occipital lobes.

Lobes of cerebral hemisphere

Medial surface

Central sulcus:

The central sulcus runs downward and forward along the superolateral surface of the hemisphere and separates the frontal lobe from the parietal lobe. The central sulcus indents the superomedial border of the hemisphere about 1 cm behind the midpoint.

The central sulcus is of great importance because the gyrus that lies anterior to it is the precentral gyrus, which contains the motor cells that initiate the movements of the opposite side of the body and posterior to the central sulcus is the postcentral gyrus, which contains the general sensory cortex that receives the sensory information from the opposite side of the body.

lateral sulcus

The lateral sulcus is a deep cleft separates frontal and parietal lobes from the temporal lobe. At the bottom of the lateral sulcus is the insula of the brain (an area of cerebral cortex buried at the bottom of the lateral sulcus). The lateral sulcus begins medially and ends laterally on the lateral surface by dividing into three rami:

1. Anterior ramus
2. Ascending ramus
3. Posterior ramus

parieto-occipital sulcus:

The parieto-occipital sulcus separates the parietal lobe from occipital lobe, begins on the medial surface of the hemisphere about 5 cm anterior to the occipital pole passes downward and anteriorly to meet the calcarine sulcus.

Lobes of the cerebral hemispheres

Superolateral surface of the hemisphere

Frontal lobe occupies the area anterior to the central sulcus and superior to the lateral sulcus. The lateral surface of the frontal lobe divided by three sulci into four gyri.

The precentral sulcus parallel to the central sulcus and the precentral gyrus lies between them. Anterior to the precentral sulcus are superior and inferior frontal sulci.

The superior frontal gyrus lies superior to the corresponding sulcus, the middle frontal gyrus lies between the superior and inferior sulci, and the inferior frontal gyrus lies inferior to the corresponding sulcus.

The inferior frontal gyrus indented by the anterior and ascending rami of the lateral sulcus.

parietal lobe

The parietal lobe occupies the area posterior to the central sulcus, anterior to the parieto-occipital sulcus and superior to the lateral sulcus extends posteriorly as far as the parieto-occipital sulcus.

The lateral surface of the parietal lobe contains:

The postcentral sulcus runs parallel to the central sulcus and the postcentral gyrus lies between them parietal lobe.

Running posteriorly from the middle of the postcentral sulcus is the intraparietal sulcus, superior to it is the superior parietal lobule (gyrus), and inferior to it is the inferior parietal lobule (gyrus).

Parietal lobe shows two additional small gyri:

Supramarginal gyrus arching over the end of the posterior ramus of the lateral sulcus.

Angular gyrus arching over the end of the superior temporal sulcus temporal lobe.

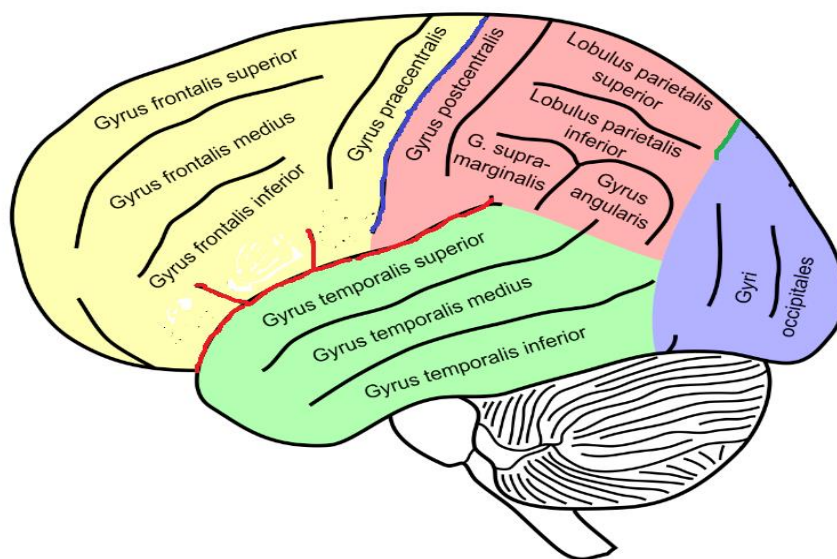
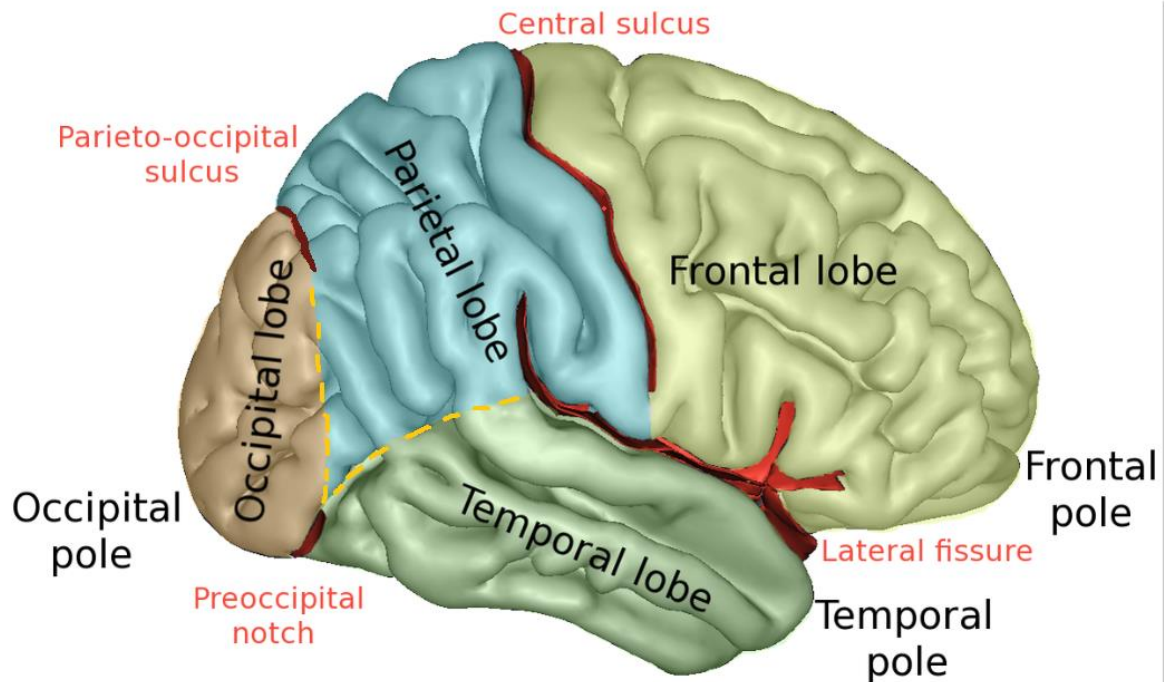
The temporal lobe

The temporal lobe occupies the area inferior to the lateral sulcus.

The lateral surface of the temporal lobe divided into three gyri by two sulci.

The superior and inferior temporal sulci run parallel to the posterior ramus of the lateral sulcus dividing the temporal lobe into the superior, middle and inferior temporal gyri.

Id to



Medial surface of the hemisphere

At this surface we can recognize the corpus callosum, which is the largest commissure of the brain.

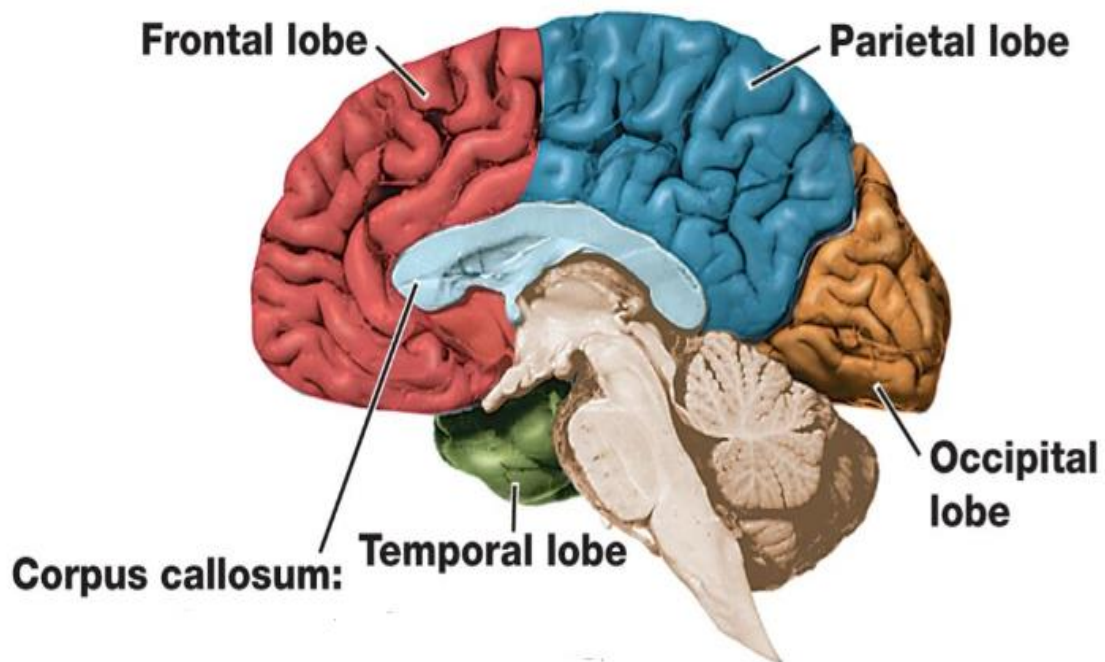
The cingulate gyrus begins beneath the anterior end of the corpus callosum until it reaches its posterior end, the gyrus is separated from the corpus callosum by the callosal sulcus. The cingulate gyrus separated from the superior frontal gyrus by the cingulate sulcus.

The paracentral lobule is the area of the cerebral cortex that surrounds the indentation produced by the central sulcus on the medial surface of the hemispheres. The anterior part of this lobule is a continuation of the precentral gyrus, and the posterior part of the lobule is a continuation of the postcentral gyrus. It contains the motor and sensory areas which control the leg and perineum and supplied by callosomarginal branch of the anterior cerebral artery.

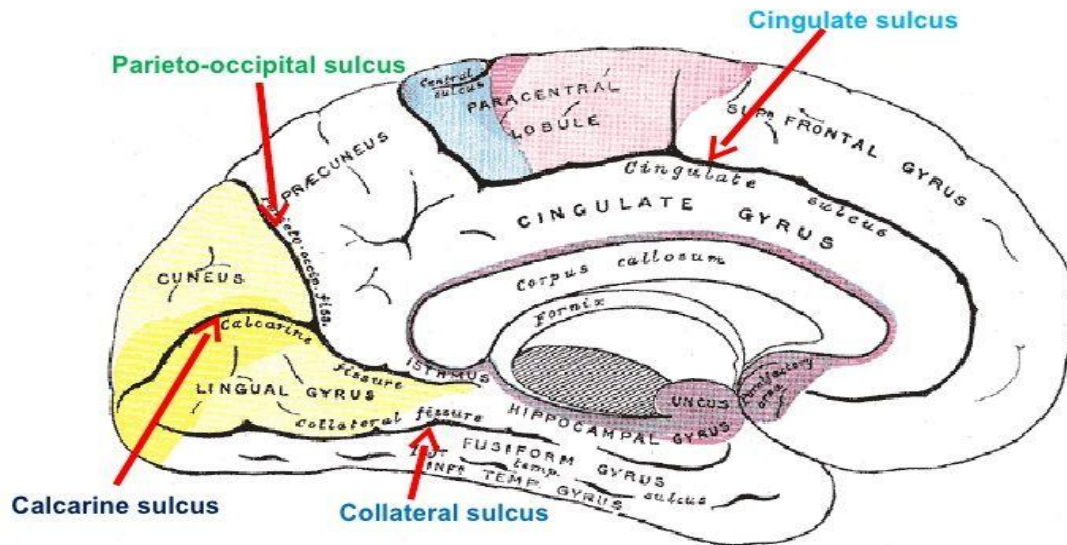
The calcarine sulcus starts just below the splenium of corpus callosum and runs backward as far as the occipital pole. The area surrounding the calcarine sulcus contains the main visual area.

Precuneus is an area of cortex bounded anteriorly by the posterior end of the cingulate sulcus and posteriorly by the parieto-occipital sulcus.

The cuneus is a triangular area of cortex bounded above by the parieto-occipital sulcus, inferiorly by the calcarine sulcus and posteriorly by the superomedial margin of the hemisphere.



Sulcus in the medial surface



Inferior surface

It is divided by the stem of lateral sulcus into:

- 1- Small anterior part (Orbital part) or the inferior surface of the frontal lobe.
- 2- large posterior part (Tentorial part) or the inferior surface of the temporal lobe.

The inferior surface of the Temporal lobe

The collateral sulcus situated on the inferior surface of the temporal lobe of the hemisphere begins below the calcarine sulcus and runs anteriorly.

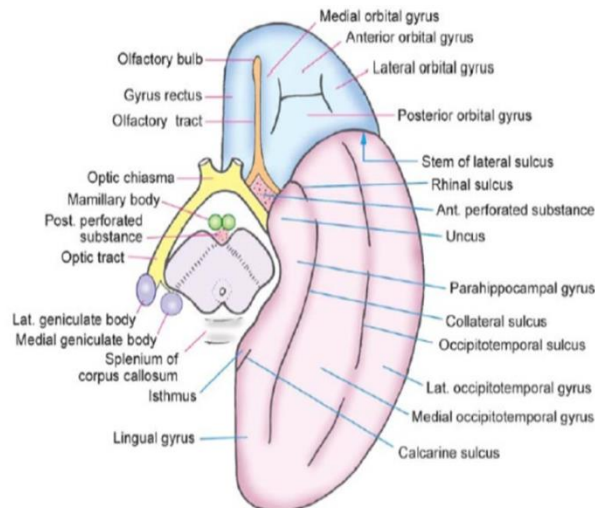
Medial to the collateral sulcus is the parahippocampal gyrus terminates in front as a hook like uncus which is limited laterally by a small sulcus called rhinal sulcus.

Between the collateral sulcus and the calcarine sulcus is the medial occipitotemporal gyrus.

Lateral to the collateral sulcus is the occipitotemporal sulcus extends from the occipital pole to the temporal pole, between the collateral and occipitotemporal sulci is the lateral occipitotemporal gyrus

The inferior surface of the frontal lobe

On the inferior surface of the frontal lobe, the olfactory bulb and tract overlies a sulcus called the olfactory sulcus, medial to it is the rectus gyrus and lateral to it are a number of orbital sulci (H-shaped sulcus) and orbital gyri (anterior, posterior, lateral and medial).



Functional localization areas of the cerebral cortex:

Frontal lobe:

- 1- Primary motor area (Brodmanns' area 4).
- 2-(Brodmann s' area 6)Premotor area or secondary motor area.
- 3- The motor speech area of Broca (area 44 and 45).About 95% of the population reside in the left cerebral hemisphere(include all right-hand people).It controls the ability of vocalization and its damage results in difficulty or inability to articulate(motor aphasia).

In the precentral gyrus various regions of the body are represented in an inverted manner .Thus the head area lies near the lower end and the lower parts of the body (leg and foot)are represented at its upper end.

Parietal lobe

- 1- The primary sensory area (Brodmann s areas 3,1,and2) occupies the postcentral gyrus on the lateral surface of the hemisphere and the posterior part of the paracentral lobule on the medial surface.
- 2- Secondary sensory area is in the superior lip of the posterior ramus of the lateral sulcus.

In the postcentral gyrus various regions of the body are represented in an inverted manner similar to the arrangement in the precentral gyrus.

Occipital lobe

1- The primary visual area(Brodmann s' area 17) is situated in the walls of the calcarine sulcus.

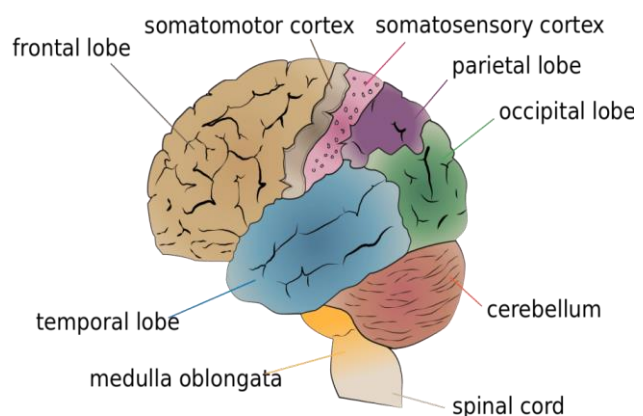
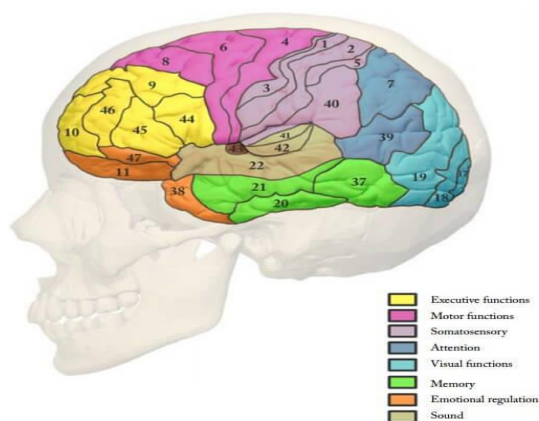
2- The secondary visual area(Brodmann s' area 18 and 19) surrounds the primary visual area on the medial and lateral surfaces of the hemisphere. The function of this area is to relate the visual information received by the primary visual area to past visual experiences thus enabling the individual to recognize what he seeing.

Temporal lobe

1- Primary auditory area(Brodmann s' area 41 and 42) situated in the inferior wall of the lateral sulcus.

2- The secondary auditory area (Brodmann s' area 22) is situated in the lateral sulcus and in the superior temporal gyrus.

3- The sensory speech area of Wernicke is localized in the left dominant hemisphere mainly in the superior temporal gyrus. It enables comprehension of the spoken language or language fluency. Damage to this area results in sensory aphasia.



CEREBELLUM

The largest part of the hindbrain lies posterior to the pons and medulla oblongata situated in the posterior cranial fossa and covered by the tentorium cerebelli. It is ovoid in shape and consists of two cerebellar hemispheres joined by a narrow median part called vermis.

The cerebellum consists of gray and white matter. The gray matter covers the surface of the cerebellum. The cortex shows numerous parallel fissures separated by narrow folds, these folds called folia.

The cerebellum controls the smooth contraction of voluntary muscles and carefully coordinates their action.

The cerebellum has two surfaces superior and inferior.

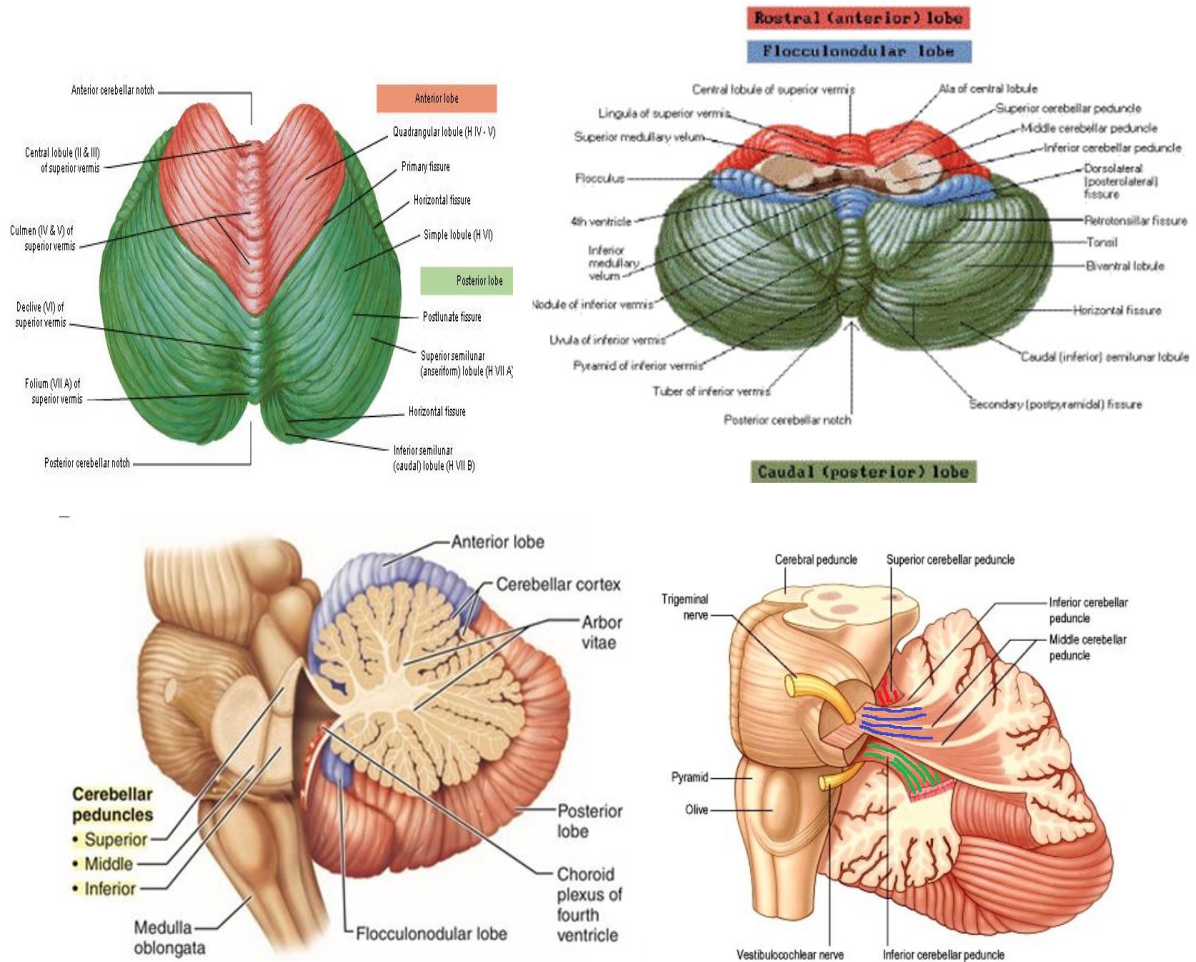
The superior surface of the cerebellum shows the:

- 1- superior aspect of the vermis
- 2- the anterior lobe
- 3- the middle (posterior) lobe
- 4- the primary fissure
- 5- horizontal fissure

The anterior lobe seen on the superior surface of the cerebellum and separated from the middle lobe by a V-shaped fissure called the primary fissure.

The inferior surface of the cerebellum shows:

- 1- posterior lobes
- 2- vermis (its inferior surface) and divided from anterior to posterior into: nodule, uvula, pyramid, and tuber.
- 3- Tonsil : small lobule located in both sides of the vermis.
- 4- Flocculus: is a small ovoid portion which lies anterior to the tonsil.
- 5- The flocculonodular lobe: formed from the flocculus and the nodule of the vermis.



Cerebellar peduncles

The cerebellum connected to the brain stem (midbrain, pons and medulla oblongata) by bundles of nerve fibers of the white matter called peduncles these are:

- 1- Superior peduncle: It connects the cerebellum with the midbrain.
- 2- Middle peduncle: It connects the cerebellum with the pons.
- 3- Inferior peduncle :It connects the cerebellum with the medulla oblongata

Function of the cerebellum

- 1- Each cerebellar hemisphere controls the muscles of the same side of the body
- 2- Assist in maintaining equilibrium of the body by modification of the muscle tone.
- 3- Play a role in maintenance of posture.
- 4- Facilitate a smooth coordinated voluntary movement of the body.

Sign and symptoms of the cerebellar injury:

Hypotonia of the muscles.

Postural changes and alteration of gait.

Disturbance of voluntary movement (ataxia).

Disturbance of reflexes.

Disturbance of ocular movement (Nystagmus).

Disorder of speech (Dysarthria).

MEDULLA OBLONGATA

It is conical in shape connects the pons superiorly to the spinal cord inferiorly the junction of the medulla oblongata to the spinal cord is at the level of the foramen magnum. It is about 3 cm in length.

The central canal of the spinal cord continues upward into the lower part of the medulla oblongata. In the upper part of the medulla the canal expand to form the cavity of the fourth ventricle.

The anterior surface of the medulla oblongata:

- 1- Anterior median fissure.
- 2- Pyramids (corticospinal fibers originate in the precentral gyrus of the cerebral cortex).
- 3- Decussation of the pyramids.
- 4- Olives: oval elevations located posterolateral to the pyramids.
- 5- Inferior cerebellar peduncles (located Posterior to the olives).

The posterior surface of the medulla oblongata:

The superior part forms the lower part of the floor of the fourth ventricle.

The inferior part possess the posterior median sulcus.

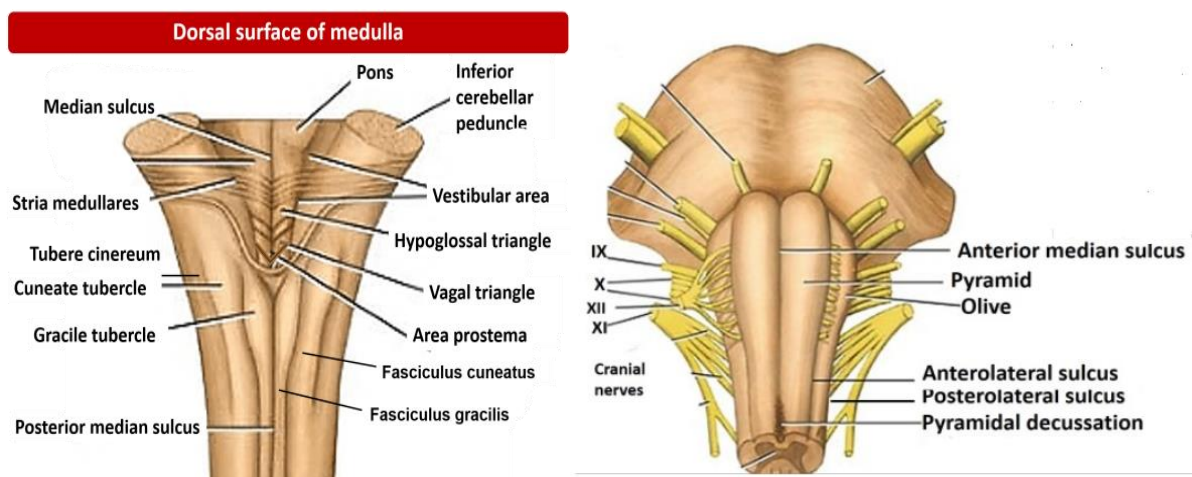
The gracile tubercle, produced by the underlying nucleus gracilis.

The cuneate tubercle, produced by the underlying nucleus conatus.

There are also anterolateral and posterolateral sulci.

Along the anterolateral sulcus the roots of the hypoglossal nerve emerge.

Along the posterolateral sulcus the roots of the glossopharyngeal , vagus and accessory nerves are emerge.



PONS

It lies anterior to the cerebellum connect medulla oblongata to the midbrain, it is about 1 inch in length and Its shape like a bridge.

A shallow groove in the midline called the basilar groove, which contain the basilar artery.

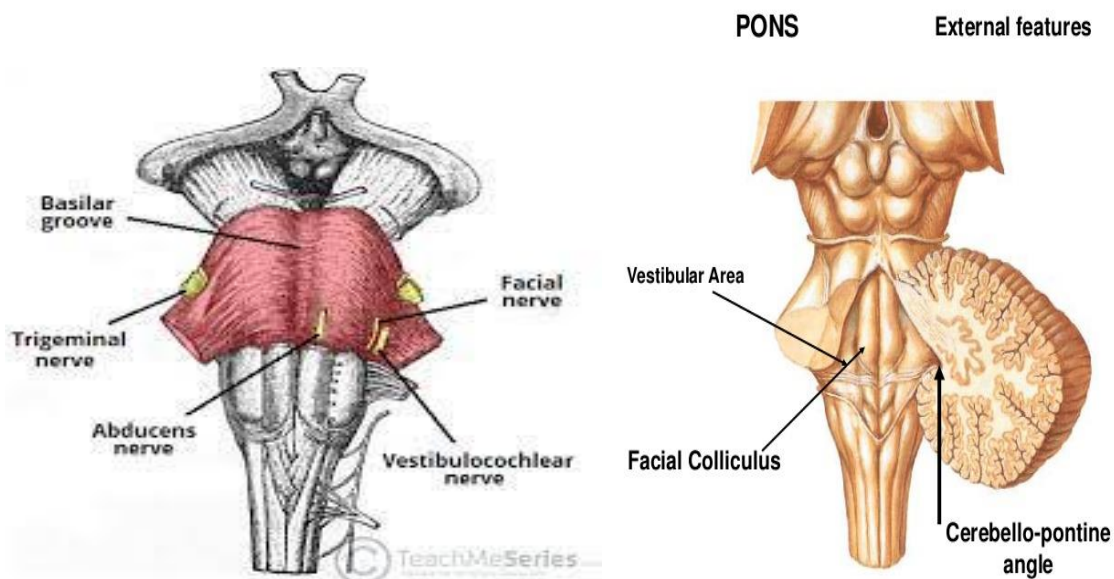
Many transverse fibers that converge on each side to form the middle cerebellar peduncle.

Its anterior surface is convex from side to side and shows many transverse fibers that converge on each side to form the middle cerebellar peduncle.

On the anterolateral surface of the pons the trigeminal nerve emerges, each nerve consists of a smaller medial motor root and a larger lateral sensory root. In the groove between the pons and medulla oblongata three nerves emerge from medial to lateral abducent (6th) facial (7th) and vestibulocochlear (8th) cranial nerves.

Posterior surface of the pons is hidden by the cerebellum. It form the upper half floor of the fourth ventricle and it is triangular in shap.

The posterior surface is limited laterally by the superior cerebellar peduncles and divided into two half by the median sulcus.



MIDBRAIN

It is the short upper part of brain stem lying between the cerebrum above and pons below. It is about 2.5 cm long and it passes through the tentorium notch. It consists of large ventral (anterior) and small dorsal (posterior) parts. The two parts (separated by a narrow cavity called (cerebral aqueduct).

The small dorsal part called tectum. The large ventral part called cerebral peduncle.

Tectum:

It shows 4 rounded elevations called colliculi. They are arranged in superior and inferior pairs and they contain cores of grey matter. The pineal body rests in the groove between the superior colliculi.

There is a round band called brachium which extends upwards and forwards from the outer side of each colliculus. So producing superior and inferior pairs of brachia.

Superior colliculi are centers of visual reflex.

Inferior colliculi are centers of auditory reflex.

Cerebral Peduncles

These are two thick rounded columns which emerge from the upper surface of the pons and diverge as they pass upward into the cerebral hemispheres

Each peduncle consists of three parts:

- 1- Crus cerebri (ventral part).
- 2- Substantia nigra (median part).
- 3- Tegmentum (dorsal part).

Crus cerebri:

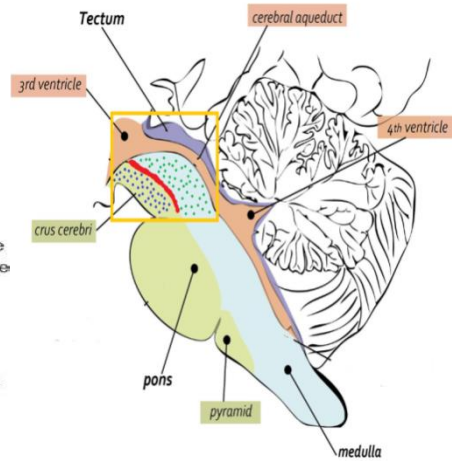
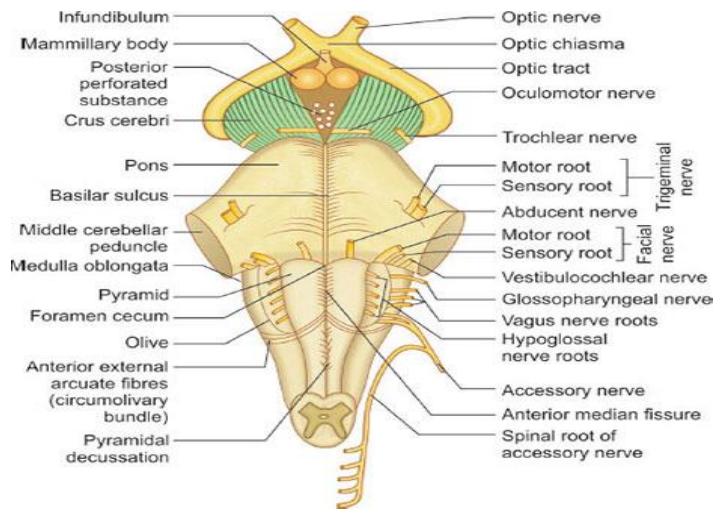
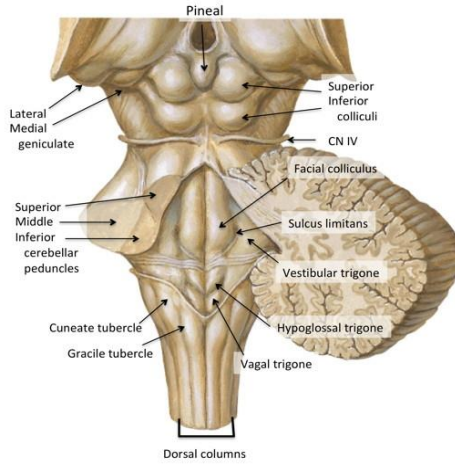
Each one is formed by broad bundles of nerve fibers which arise in the cerebral cortex of the corresponding hemisphere and emerge as a crus.

Substantia nigra:

It is a plate of grey matter lying between the crus cerebri and tegmentum. It consists of large nerve cells with considerable amount of melanin in their cytoplasm. They play an important part in the control of muscle tone and activity and produce dopamine.

Tegmentum:

It is a thick column of mixed grey and white matter.
The thick layer of gray matter called red nucleus.



DIENCEPHALON

The diencephalon surrounds the third ventricle, it divided into :

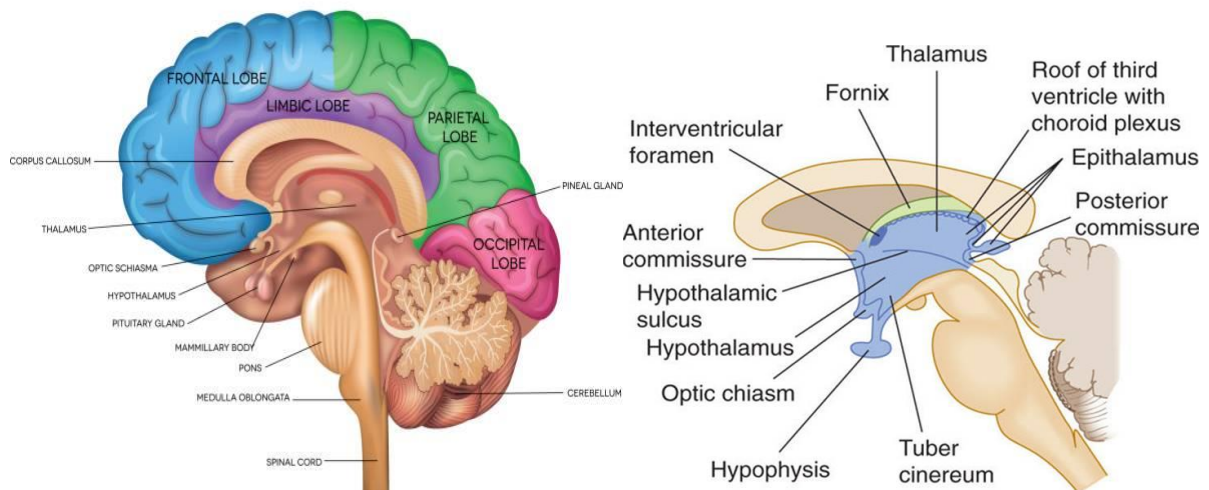
The epithalamus: is the dorsal surface of the diencephalon and is composed of the pineal body (an endocrine gland), the stria medullaris, and the habenular trigone, whose nuclei and interhabenular connections are associated with the olfactory system.

The thalamus: is the largest portion of the diencephalon and is separated into right and left halves by the third ventricle. The two thalami are interconnected by a bridge of gray matter, (or interthalamic adhesion) . The pulvinar is one such large caudal region of the thalamus, located just above the midbrain. Two other nuclei, the medial and lateral geniculate bodies, associated with hearing and sight, respectively are located in the vicinity of the pulvinar.

The hypothalamus: is separated from the thalamus by a groove, the hypothalamic sulcus, located on either wall of the third ventricle. This small region of the diencephalon is associated with endocrine function, sleep, emotion, and regulation of temperature. Structures of the hypothalamus evident on the ventral surface of the brainstem are the hypophysis (pituitary gland); the small, elevated tuber cinereum with the attendant infundibulum of the hypophysis; and the two mamillary bodies, located caudal to the tuber cinereum

The subthalamus: contains one major nucleus the subthalamic nucleus, and a few small bundles of fiber tracts. This subdivision of the diencephalon is associated with somatic efferent functions

ANATOMY OF THE BRAIN



VENTRICLES OF THE BRAIN

The ventricles of the brain are a communicating network of cavities filled with cerebrospinal fluid (CSF) and located within the brain parenchyma.

The ventricular system is composed of 2 lateral ventricles the third ventricle the cerebral aqueduct and the fourth ventricle.

The choroid plexuses are located in the ventricles produce CSF, which fills the ventricles and subarachnoid space, following cycle of constant production and reabsorption.

LATERAL VENTRICLE

There are two C-shaped cavities called the lateral ventricles; one in each cerebral hemisphere. These ventricles have three horns projecting into the lobes for which they are named.

The central part of the lateral ventricle is located in the region of the parietal lobe.

Frontal horn:

An anterior projection from the level of the interventricular foramen of Monro extends into the frontal lobe. It's known as the frontal horn.

Temporal horn:

The temporal horn is the most inferior aspect of the cavity. It extends into the temporal lobe.

Occipital horn:

The occipital horn extends variably as a finger-like projection from the posterior aspect of the concavity of the ventricle to the occipital lobe.

THIRD VENTRICLE

The third ventricle is located in the diencephalic part of the brain .The foramen of Monro provides a passage way for the choroid plexus of the lateral ventricles to enter the third ventricle.

The cerebral aqueduct

The cerebral aqueduct of Sylvius is one of the interconnecting channels, and it ensures the communication between the third and fourth ventricles.

FOURTH VENTRICLE:

The fourth ventricle is the most inferior of the four ventricles. It is situated in the brainstem:

inferior to the midbrain, posterior to the pons, anterior to the cerebellum and superior to the medulla oblongata.

On either side are lateral apertures (foramina of Luschka) that open into the cerebellopontine cisterns.

Similarly, in the inferior roof of the fourth ventricle is another median aperture known as the foramen of Magendie that opens into the cerebellomedullary cistern.

Choroid plexus:

Each ventricle is home to a choroid plexus. The vascular part of the pia mater, which is called the tela choroidea, folds into the cavity of the ventricle and is further covered by ependymal. It contains choroid epithelium, which is simply cuboidal or low columnar epithelium. The extensive folding of the membrane gives the structure an expansive surface area. The capillaries of the plexus are fenestrated with specific permeability.

The choroid plexuses in each ventricle are responsible for the synthesis of cerebrospinal fluid (CSF).

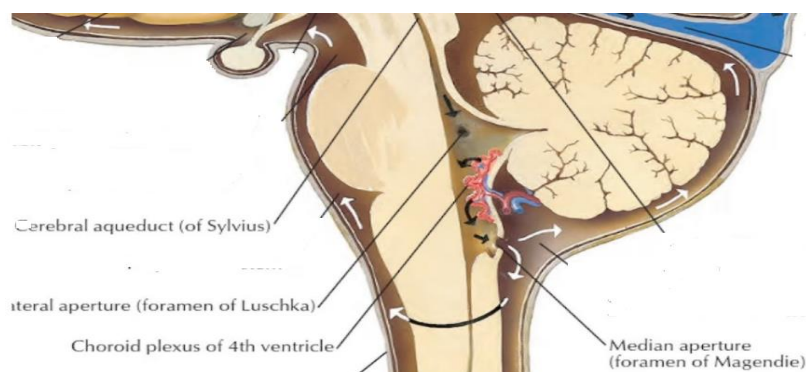
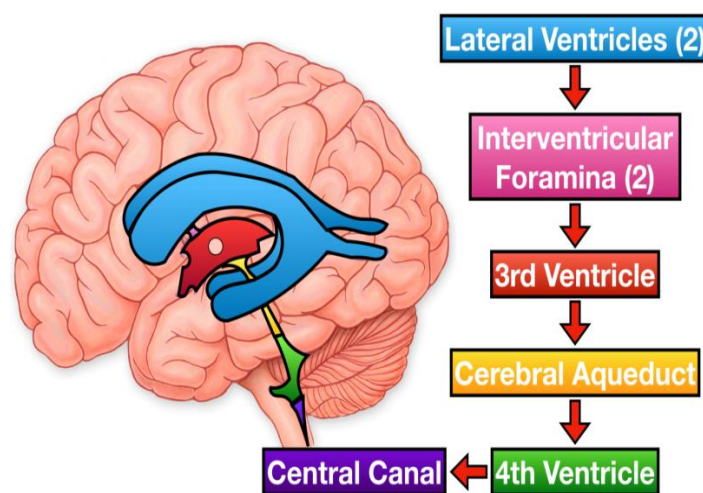
Cerebrospinal fluid:

The cerebrospinal is a clear, colorless, slightly alkaline fluid of low specific gravity. It is produced by the choroid plexuses within the lateral, third and fourth ventricles of the brain.

It escapes from the ventricular system of the brain through the three foramina in the roof of the fourth ventricle and so enters the subarachnoid space.

It circulates both upward over the surfaces of the cerebral hemispheres and downward around the spinal cord. The spinal subarachnoid space extends down as far as the second sacral vertebra.

Eventually, the fluid enters the bloodstream by passing into the arachnoid villi and diffusing through their walls. In addition to removing waste products associated with neuronal activity, the cerebrospinal fluid provides a fluid medium in which the brain floats. This mechanism effectively protects the brain from trauma. In addition, the fluid is now believed to play a role in hormonal transport. CSF assists the brain by providing protection, nourishment and waste removal. CSF acts as a shock absorber and cushioning the brain against the skull.



REFERENCES

- 1- Anne M. Agur and Arther F. Dalley. Grant's atlas of anatomy 13th edition. Wolters Kluwer
- 2- Bernard Liebgott. The anatomical basis of dentistry 4th edition. Mosby
- 3- Frank H. Netters, Atlas of human anatomy, 7th edition. Elsevier.
- 4- Gray's Anatomy. The Anatomical Basis of Clinical Practice 41st edition. Elsevier.
- 5- James L. Hiatt and Leslie P. Gartener. Text book of head and neck anatomy, 4th edition. Wolters Kluwer.
- 6- Richard S. Snell. Snell clinical anatomy by region, 9th edition. Lippincott Williams and Wilkins.
- 7- Richard L. Drake et al. Gray's atlas of anatomy, 2nd edition. Churchill Livingstone. 8- Keith L. Moore Clinically Oriented Anatomy. 8th edition. Wolters Kluwer.

